International Surgery Journal
Gomez SC et al. Int Surg J. 2026 Dec;13(12):2584-2588
https://www.ijsurgery.com
pISSN 2349-3305 | eISSN 2349-2902

DOI: https://dx.doi.org/10.18203/2349-2902.isj20264367

Case Report

Laparoscopic management of phytobezoar-induced small bowel obstruction in a virgin abdomen: a case report

Sofía Claribel Gomez*, Rodrigo Antonio Gasque, Alejandro Marcelo Doniquian, Germán Rodrigo Viscido

Servicio de Cirugía General, Clínica Universitaria Reina Fabiola, Córdoba, Argentina

Received: 20 September 2026
Accepted: 04 November 2026

***Correspondence:**
Dr. Sofía Claribel Gomez,
E-mail: Sofiagom96@gmail.com

Copyright: © the author(s), publisher and licensee Medip Academy. This is an open-access article distributed under the terms of the Creative Commons Attribution Non-Commercial License, which permits unrestricted non-commercial use, distribution, and reproduction in any medium, provided the original work is properly cited.

ABSTRACT

Small bowel obstruction (SBO) in the virgin abdomen represents a diagnostic challenge due to the wide variety of uncommon underlying etiologies. Among them, bezoars are a rare cause, accounting for up to 4.8% of SBO cases. Preoperative diagnosis remains difficult, even with computed tomography, and treatment usually requires surgical intervention. Objectives were to present a case of phytobezoar-induced SBO in a patient with a virgin abdomen, successfully managed using a laparoscopic approach. We report the case of a 43-year-old male patient with no previous surgical or medical history who presented with abdominal pain and distension. Computed tomography demonstrated SBO with a transition point in the small intestine, without clearly identifying the etiology. Due to persistence of symptoms and radiological progression, laparoscopic exploration was indicated. During surgery, a fixed intraluminal lesion measuring approximately 7 cm was identified one meter proximal to the ileocecal valve, causing SBO. Because of the suspicion of a small bowel tumor, laparoscopic segmental resection with intracorporeal anastomosis was performed. Examination of the surgical specimen revealed a phytobezoar composed of dehydrated peach. The patient had a favorable postoperative course, with restoration of bowel function and hospital discharge after 72 hours. Bezoar-induced SBO should be considered among the differential diagnoses in patients with a virgin abdomen. The laparoscopic approach represents a safe and feasible alternative in selected patients and in centers experienced in emergency minimally invasive surgery.

Keywords: Intestinal obstruction, Bezoars, Laparoscopy

INTRODUCTION

Small bowel obstruction (SBO) accounts for approximately 15% of emergency surgical admissions and requires operative intervention in 20-50% of cases.[1,2] The most common causes are postoperative adhesions, abdominal wall hernias, and gastrointestinal malignancies, with adhesive disease alone accounting for 55-75% of cases.[3]

A distinct clinical entity is SBO in the virgin abdomen (SBO-VA), defined as SBO occurring in patients without a history of abdominal surgery, radiotherapy, or known peritoneal inflammatory disease. In this setting, congenital adhesions, neoplasms, volvulus, intussusception, Meckel's diverticulum, internal hernias, gallstone ileus, and bezoars represent the most frequent causes.[2,4,5]

Bezoars are accumulations of indigestible material within the gastrointestinal tract. They represent an uncommon cause of SBO, with a reported incidence ranging from 0.4% to 4.8%.[6-8] According to their composition, bezoars are classified into several subtypes, including phytobezoars, trichobezoars, pharmacobezoars, lactobezoars, and other less frequent variants. Clinically, bezoar-induced SBO is usually indistinguishable from obstruction caused by other etiologies.[6,7-10]

Within the small bowel, bezoars most commonly impact the distal ileum, typically between 60 and 160 cm proximal to the ileocecal valve.[11] Computed tomography (CT) is considered the diagnostic modality of choice because it accurately identifies the site and severity of obstruction while excluding alternative causes. However, direct visualization of the bezoar is not always possible.[12,13]

Management strategies depend on the type and location of the bezoar as well as the patient's clinical condition. SBO secondary to bezoars frequently requires surgical treatment.[6,7,10,11] Traditionally, laparotomy has been the preferred approach; however, laparoscopic management has emerged as a feasible and effective alternative in selected patients. Despite its advantages, reports of laparoscopic treatment remain limited, likely because of the rarity of this condition and the technical challenges associated with minimally invasive surgery in the setting of acute intestinal obstruction (AIO).[10,14,15]

We report the case of a patient with no previous surgical history who developed complete SBO caused by a phytobezoar located in the terminal ileum and was successfully treated through a laparoscopic approach.

CASE REPORT

A 43-year-old male with no significant past medical or surgical history presented to the emergency department with a 12-hour history of diffuse abdominal pain. The pain was colicky in nature, of moderate intensity, predominantly periumbilical, and had partially improved after self-administration of analgesics. He denied nausea, vomiting, diarrhea, weight loss, or other gastrointestinal symptoms. Bowel function was initially preserved, with passage of flatus and a bowel movement occurring 24 hours before presentation.

On physical examination, the patient was hemodynamically stable and afebrile. The abdomen was distended, soft, tympanic, and mildly tender in the periumbilical region, without guarding or signs of peritoneal irritation.

Laboratory investigations demonstrated leukocytosis (16,700/mm³), while C-reactive protein, erythrocyte sedimentation rate, and serum lactate levels were within normal ranges.

Contrast-enhanced abdominal computed tomography (CT) revealed marked gastric and small bowel dilatation with multiple air-fluid levels and an abrupt transition point in the hypogastric region.

No abnormalities of the bowel wall were identified, and there was no evidence of extrinsic compression, intraluminal pathology, inflammatory bowel disease, Meckel's diverticulum, or appendiceal pathology (Figure 1).

A diagnosis of small bowel obstruction in a virgin abdomen was established, and the patient was admitted for close observation. During the first 24 hours, he remained asymptomatic, passed flatus, and exhibited no nasogastric tube output.

On the second hospital day, following initiation of a liquid diet, he developed recurrent severe abdominal pain. Repeat abdominal CT demonstrated progression of the obstruction, with increased dilatation of the proximal small bowel loops, distal bowel collapse, and a small amount of feculent-appearing intraluminal material at the transition point (small bowel feces sign) (Figure 1).

Given the clinical deterioration and radiologic progression, surgical exploration was indicated.

An open umbilical entry technique was used to establish pneumoperitoneum, and a 12-mm trocar was inserted for the laparoscope. Initial exploration revealed dilated small bowel loops and a moderate amount of inflammatory free fluid. Two additional 5-mm trocars were placed in the left upper quadrant and left iliac fossa.

Exploration began at the ileocecal valve and proceeded proximally. Approximately 1 meter proximal to the ileocecal valve, a transition zone was identified, associated with a fixed, rounded lesion measuring approximately 7 cm in diameter. The lesion appeared either intraluminal or intramural, as the serosal surface was completely normal. Multiple attempts at laparoscopic mobilization using atraumatic graspers and suction instrumentation were unsuccessful.

Because preoperative imaging had failed to establish the etiology of the obstruction and the intraoperative appearance was highly suggestive of a small bowel neoplasm, segmental resection of approximately 25 cm of small intestine was performed using 45-mm and 60-mm linear staplers with blue cartridges. A laparoscopic bowel clamp was applied proximally to prevent intraluminal spillage. Intracorporeal side-to-side stapled anastomosis was then fashioned using a 60-mm linear stapler, and the enterotomy was closed with a continuous 3-0 Vicryl® suture. A Jackson-Pratt drain was placed adjacent to the anastomosis.

The specimen was retrieved through the umbilical incision using a protective extraction bag. Gross examination of the resected segment revealed a firm intraluminal mass that remained immobile despite external manipulation. Enterotomy of the specimen demonstrated a phytobezoar consisting of a dehydrated peach (Figure 2).

Following this finding, a targeted dietary history was obtained. The patient reported consuming three dehydrated peaches, locally known as orejones, approximately 72 hours before the onset of symptoms.

The postoperative course was uneventful. Bowel function recovered promptly, oral intake was successfully resumed, and the patient was discharged on postoperative day three.

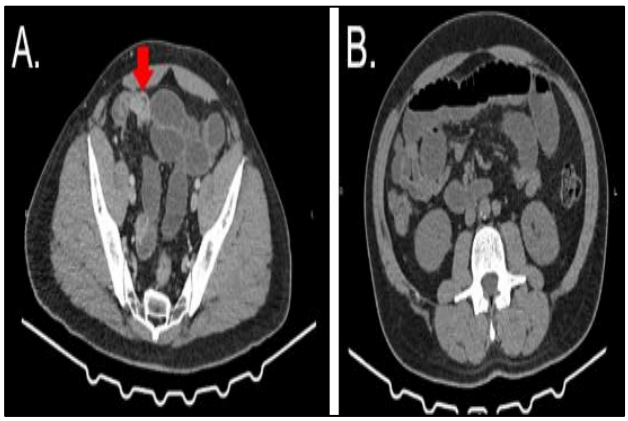

Figure 1 (A and B): Abdominal computed tomography, axial slices (A admission CT scan, B CT scan 48 hours post-admission). A) Dilation of small bowel loops visible extending to the right intrapelvic region where a change in caliber is visualized. B) Signs of obstruction in small bowel loops, with marked dilation and abundant contents. Stop point in the right iliac fossa identifying stercoral-type contents in the pre-stenotic loop and distal collapse of the small bowel post-stenotic.

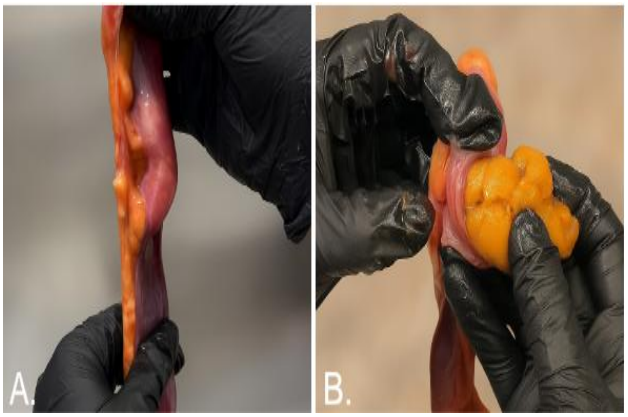

Figure 2 (A and B): A) Surgical specimen with intraluminal obstruction. B) Enterotomy with phytobezoar extraction.

DISCUSSION

AIO is a surgical emergency resulting from a mechanical or functional impairment of normal intestinal transit.[1] It accounts for approximately 15% of hospital admissions for acute abdomen and requires surgical intervention in 20–50% of cases, representing a major source of morbidity, reoperation, and healthcare costs.[1,2]

AIO may be classified as partial or complete based on computed tomography (CT) findings, a distinction that may also have therapeutic implications.[1] The underlying causes can be broadly categorized as extrinsic, mural, or intraluminal. Approximately 90% of cases are attributable to postoperative adhesions, hernias, and gastrointestinal neoplasms.[1,2]

Within the spectrum of AIO, AIO with a volvulus mechanism (AIOV) represents a relatively recently studied entity. In this setting, otherwise uncommon etiologies are encountered with greater frequency, making both diagnosis and management particularly challenging. The most frequently reported causes of AIOV include congenital adhesions; neoplastic disease, including neuroendocrine tumors, lymphomas, carcinomas, retroperitoneal tumors, and metastases from colorectal, ovarian, and prostate cancers; small-bowel volvulus; intestinal intussusception; Meckel's diverticulum; gallstone ileus; internal hernias; and bezoars. Interestingly, negative laparotomies have also been reported in patients with AIOV in whom no underlying cause of obstruction could be identified.[1,3,4]

Bezoars are an uncommon cause of intestinal obstruction and have been reported as the sixth most frequent etiology, accounting for approximately 0.4-4.8% of cases. The first scientific description dates back to 1779, when Baudmant reported a trichobezoar. Subsequently, Quain used the term “bezoar” to describe a mass of food found in the stomach during an autopsy.[1,3,5,6]

Phytobezoars account for approximately 40% of bezoar cases.[10,12] They may occur in otherwise healthy individuals or in patients with predisposing conditions, including previous gastric or intestinal surgery, Crohn's disease, gastrointestinal motility disorders, diabetes mellitus, and a high-fiber diet, among others.[5,9,14] In the present case, the patient had no relevant medical history, had intact dentition, and reported a balanced diet.

Clinically, intestinal obstruction caused by a bezoar is generally indistinguishable from obstruction due to other causes. Our patient presented with several hours of colicky periumbilical abdominal pain that resolved after analgesic administration. There was no vomiting, and intestinal transit was preserved, with passage of both flatus and stool. Physical examination revealed abdominal distension and mild diffuse tenderness, without guarding or signs of peritoneal irritation. Routine laboratory testing demonstrated leukocytosis, prompting abdominal CT imaging.

The clinical presentation of bezoars varies according to their composition, size, and location. When located in the small bowel, they typically present with abdominal pain and distension, vomiting, constipation, anorexia, and gastrointestinal bleeding. Nevertheless, bezoars remain a diagnostic challenge.[15-17]

When a bezoar causes intestinal obstruction, it is most commonly located 50-70 cm proximal to the ileocecal

valve. This predilection has been attributed to the narrower intestinal lumen, reduced motility of the distal small bowel, and increased water absorption in this segment, all of which may contribute to increased bezoar consistency.[15,16] However, this observation contrasts with CT-based studies reporting a higher frequency of bezoars in the jejunum (50-65%), followed by the ileum.[17,18] In our patient, the transition point was located approximately 1 m proximal to the ileocecal valve.

CT has been reported to have a sensitivity of approximately 90% and a specificity of 47-57% for the diagnosis of bezoar-induced intestinal obstruction. Typical CT findings include a mottled gas pattern or a rounded/ovoid intraluminal mass at the site of obstruction, with well-defined margins and heterogeneous internal attenuation. Associated findings frequently include proximal bowel dilatation, air-fluid levels, and distal bowel collapse. CT also plays an important role in excluding alternative causes of intestinal obstruction and in identifying bowel-wall edema, free intraperitoneal fluid, and signs suggestive of strangulation, perforation, or other complications. Furthermore, CT findings may assist in determining the need and timing of surgical intervention. Once a bezoar is identified as the cause of obstruction, early surgical management-ideally within the first 48 hours-has been advocated to minimize complications.[15-18] Higher Hounsfield unit (HU) values within the bezoar have also been proposed as a potential predictor of the need for early surgery, possibly reflecting greater bezoar consistency or rigidity.

In our case, two CT examinations demonstrated findings consistent with intestinal obstruction; however, neither identified the bezoar nor revealed clear indirect signs of its presence, with the exception of the so-called “feces sign.”

Bezoars may be mistaken for fecal material on CT. They can nevertheless be distinguished by their confinement to a relatively short segment of bowel and their well-defined intraluminal appearance.[8,16] We believe that this diagnostic pitfall may have contributed to the failure to identify the bezoar preoperatively in our patient. However, even after the diagnosis had been established intraoperatively, retrospective review of both CT examinations failed to demonstrate the bezoar.

Initial management of bezoar-induced intestinal obstruction follows the general principles of treatment for AIO and includes bowel decompression, fluid and electrolyte resuscitation, and appropriate supportive care. Nevertheless, surgical intervention is required in most cases, particularly when obstruction persists or when there is concern for bowel ischemia or perforation.

The choice between laparotomy and laparoscopy depends on several factors, including the surgeon's experience with minimally invasive management of intestinal obstruction, the size and number of bezoars, the presence of local complications, and a history of previous abdominal surgery.

Yau et al compared 10 patients with bezoar-induced intestinal obstruction managed laparoscopically with 14 patients treated by laparotomy. The laparoscopic group had shorter operative times, fewer complications, and shorter hospital stays.[12,13] Despite these findings, most published series have reported an open approach.[6,7,9,10,15,16] Laparoscopic treatment has been described for bezoars located throughout the gastrointestinal tract, including the stomach, duodenum, jejunum, and ileum.

In our patient, laparoscopic exploration was selected for several reasons. First, the etiology of the intestinal obstruction had not been established preoperatively. The patient was in good general condition, hemodynamically stable, and showed no evidence of sepsis. There was no marked bowel distension or CT evidence of intra-abdominal complications. In addition, our team had substantial experience in the laparoscopic management of intestinal obstruction.

Several surgical techniques have been described, including manual fragmentation, distal displacement or “milking” of the bezoar toward the cecum, enterotomy, and segmental bowel resection with primary anastomosis.[9,10,15,16,19,20] Although milking the bezoar distally may avoid an enterotomy, it can potentially result in serosal or mesenteric injury. Bowel resection has generally been reserved for cases complicated by ischemia or irreversible bowel damage.

In our case, the absence of a preoperative etiological diagnosis and the intraoperative finding of a fixed obstruction mimicking a focal intestinal wall lesion prompted us to perform segmental bowel resection with primary anastomosis.[10,11] Alternatively, a mini-laparotomy can be used to facilitate bezoar fragmentation while preserving the minimally invasive nature of the overall approach.[8,20]

CONCLUSION

Small bowel obstruction in the virgin abdomen remains a diagnostic challenge because of the broad spectrum of uncommon underlying etiologies. Although phytobezoars are a rare cause of obstruction, they should be considered in the differential diagnosis, particularly when conventional imaging fails to identify a clear etiology.

Computed tomography is an essential diagnostic tool; however, preoperative identification of a bezoar may not always be possible. In selected patients, laparoscopic exploration provides both a diagnostic and therapeutic advantage, allowing definitive management while preserving the benefits of a minimally invasive approach.

This case highlights that bezoar-induced small bowel obstruction can occur even in patients without predisposing factors and demonstrates that laparoscopic management is a safe and effective option when performed in experienced centers.

Funding: No funding sources
Conflict of interest: None declared
Ethical approval: Not required

REFERENCES

1. Amara Y, Leppaniemi A, Catena F, Ansaloni L, Sugrue M. Diagnosis and management of small bowel obstruction in virgin abdomen: a WSES position paper. World J Emerg Surg. 2021;16(1):36.
2. Bower KL, Lollar DI, Williams SL, Adkins FC, Luyimbazi DT, Bower CE. Small bowel obstruction. Surg Clin North Am. 2018;98(5):945-71.
3. Baker S, Miller-Hammond K, King-Mullins E. Small bowel obstruction in the virgin abdomen. Surg Clin North Am. 2021;101(6):1045-52.
4. Hew N, Ng ZQ, Wijesuriya R. Non-operative management of small bowel obstruction in virgin abdomen: a systematic review. Surg Today. 2021;51(10):1558-67.
5. Iwamuro M, Okada H, Matsueda K, Inaba T, Kusumoto C, Imagawa A, et al. Review of the diagnosis and management of gastrointestinal bezoars. World J Gastrointest Endosc. 2015;7(4):336-45.
6. Paschos KA, Chatzigeorgiadis A. Pathophysiological and clinical aspects of the diagnosis and treatment of bezoars. Ann Gastroenterol. 2019;32(3):224-32.
7. Ooi S, Hong K. Small bowel obstruction caused by dried apple. Int J Surg Case Rep. 2015;10:154-7.
8. Sheikh AB, Akhtar A, Nasrullah A, Haq S, Ghazanfar H. Role of laparoscopy in the management of acute surgical abdomen secondary to phytobezoars. Cureus. 2017;9(6):1.
9. Wang S, Yang X, Zheng Y, Wu Y. Clinical characteristics and indications for surgery for bezoar-induced small bowel obstruction. J Int Med Res. 2021;49(1):300060520979377.
10. Occhionorelli S, Zese M, Targa S, Cappellari L, Stano R, Vasquez G. A rare case of a double phytobezoar causing gastric and jejunum obstruction in an adult man: a case report. J Med Case Rep. 2016;10(1):350.
11. Altintoprak F, Degirmenci B, Dikicier E, Cakmak G, Kivilcim T, Akbulut G, et al. CT findings of patients with small bowel obstruction due to bezoar: a descriptive study. ScientificWorldJournal. 2013;2013:298392.
12. Dikicier E, Altintoprak F, Ozkan OV, Yagmurkaya O, Uzunoglu MY. Intestinal obstruction due to phytobezoars: an update. World J Clin Cases. 2015;3(8):721-6.
13. Yau KK, Siu WT, Law BK, Cheung HY, Ha JP, Li MK. Laparoscopic approach compared with conventional open approach for bezoar-induced small-bowel obstruction. Arch Surg. 2005;140(10):972-5.
14. Reddy SRR, Cappell MS. A systematic review of the clinical presentation, diagnosis, and treatment of small bowel obstruction. Curr Gastroenterol Rep. 2017;19:28.
15. Oh SH, Namgung H, Park MH, Park DG. Bezoar-induced small bowel obstruction. J Korean Soc Coloproctol. 2012;28(2):89-93.
16. Ho TW, Koh DC. Small-bowel obstruction secondary to bezoar impaction: a diagnostic dilemma. World J Surg. 2007;31:1072-8.
17. Kim JH, Ha HK, Sohn MJ, Kim AY, Kim TK, Kim PN, et al. CT findings of phytobezoar associated with small bowel obstruction. Eur Radiol. 2003;13:299-304.
18. Zissin R, Osadchy A, Gutman V, Rathaus V, Shapiro-Feinberg M, Gayer G. CT findings in patients with small bowel obstruction due to phytobezoar. Emerg Radiol. 2004;10(4):197-200.
19. Pergel A, Yucel AF, Aydin I, Sahin DA. Laparoscopic treatment of a phytobezoar in the duodenal diverticulum: report of a case. Int J Surg Case Rep. 2012;3(8):392-4.
20. Yol S, Bostanci B, Akoglu M. Laparoscopic treatment of small bowel phytobezoar obstruction. J Laparoendosc Adv Surg Tech A. 2003;13(5):325-6.

Cite this article as: Gomez SC, Gasque RA, Doniquian AM, Viscido GR. Laparoscopic management of phytobezoar-induced small bowel obstruction in a virgin abdomen: a case report. Int Surg J 2026;13:2584-8.