International Surgery Journal
Patel FA et al. Int Surg J. 2026 Dec;13(12):2627-2630
https://www.ijsurgery.com
pISSN 2349-3305 | eISSN 2349-2902

DOI: https://dx.doi.org/10.18203/2349-2902.isj20264376

Original Research Article

Laparoscopic cholecystectomy in an ectopic (subhepatic) gallbladder: a rare anatomical variant

Foram A. Patel*, Abhyuday Singh, Rachit Sharma, Aishwarye Singh, Shweta Singh

Department of Surgery, Saraswathi Institute of Medical Sciences, Hapur, UP, India

Received: 14 September 2026
Revised: 07 November 2026
Accepted: 18 November 2026

***Correspondence:**
Dr. Foram A. Patel,
E-mail: forampatel996@gmail.com

Copyright: © the author(s), publisher and licensee Medip Academy. This is an open-access article distributed under the terms of the Creative Commons Attribution Non-Commercial License, which permits unrestricted non-commercial use, distribution, and reproduction in any medium, provided the original work is properly cited.

ABSTRACT

Gallbladder anatomical variations are relatively common; however, positional anomalies such as a subhepatic gallbladder are exceedingly rare. Recognition of these variants is essential to avoid iatrogenic bile duct injury during laparoscopic cholecystectomy. A 32-year-old previously healthy female presented with a 3-day history of epigastric pain associated with nausea, vomiting. Laboratory investigations including liver function test where within normal limits. Abdominal ultrasonography demonstrated multiple gallstones with features of chronic calculous cholecystitis, without any evidence of biliary anatomical variation. Subsequently intraoperative findings revealed an inferolateral subhepatic gallbladder in relation to segment V and VI of liver surrounded by flimsy adhesions. Careful dissection of Calot's triangle enabled safe identification and ligation of the cystic duct and cystic artery. The procedure was completed successfully without complications. The postoperative course was uneventful, and the patient was discharged on postoperative day 3. This case highlights the importance of anticipating unexpected anatomical variations during laparoscopic cholecystectomy. An incidentally discovered right inferolateral subhepatic gallbladder can pose significant technical challenges and increase the risk of biliary injury. Careful identification of biliary anatomy, achievement of the critical view of safety and meticulous surgical technique are key to successful management and favourable postoperative outcomes.

Keywords: Inferolateral subhepatic gallbladder, Gallbladder anatomical variations, Technical challenges, Case report

INTRODUCTION

The biliary system is composed of the intrahepatic ducts, the extrahepatic ducts and the gallbladder. Anatomically, the gallbladder occupies the right hypochondriac region, positioned in the gallbladder fossa on the visceral surface of the right hepatic lobe, interposed between hepatic segments IV B and V. The biliary tree exhibits marked anatomical complexity, with structural variations reported in nearly 50% of all patients , encompassing variations in its number, size, morphology, and anatomical position.[1,2] Multiple atypical locations have been documented, including suprahepatic, intrahepatic, left-sided, retrocolic, retro-duodenal and retro-renal sites. To the best of our knowledge, only a single instance of a gallbladder positioned within the anterior abdominal wall has been reported. Patients harbouring inferolateral subhepatic gallbladder and presenting with symptomatic gallstones exhibit clinical manifestations that mirror those of individuals with a normally located gallbladder, making the clinical identification of this anomaly exceedingly challenging for the surgeon, mastery of the biliary anatomy and its anatomical variations is critical, as it underpins the safe execution of laparoscopic cholecystectomy and the avoidance of iatrogenic injury to the biliary system.[3] This case report a rare case of an

incidentally identified right inferolateral subhepatic gallbladder successfully managed by laparoscopic cholecystectomy.[4]

CASE REPORT

A 32-year-old woman followed on an outpatient basis presented with a long history of typical symptoms of cholelithiasis, including severe epigastric pain radiating to the back or right shoulder, nausea, vomiting and intolerance to fatty foods. She denied jaundice, dark urine or acholic stools. Outpatient abdominal ultrasonography demonstrated gallstones within the gallbladder, without evidence of complications such as cholecystitis (wall thickening orimpacted stones in the infundibulum) choledocholithiasis or biliary dilation.



SARASWATHI INSTITUTE OF MEDICAL SCIENCES
NH-24, ANWARPUR, HAPUR- 245101

PATIENT NAME: [redacted] DATE:10.06.2026

AGE- 32 Y SEX: F UHID- 6090991 REFD. BY: DEPT OF G. SURGERY

ULTRASOUND SCAN OF WHOLE ABDOMEN

Liver is normal in size. Echotexture is normal. No focal space occupying lesion is seen within liver parenchyma. Intra-hepatic biliary channel are not dilated.

Gall bladder lumen shows multiple calculi, largest measuring ~ 6.6mm suggestive of cholelithiasis. Wall is not thickened. Common bile duct is not dilated.

Pancreas is of normal in size and contour. Echo-pattern is normal. No focal lesion is seen within pancreas.

Spleen is normal in size. Echotexture is normal. No focal Lesion is seen.

Both kidneys are normally sited and are of normal size and shape. Cortico medullary echoes are normal. No focal mass lesion is seen. Left kidney shows few tiny calculi.

No free fluid seen in peritoneal cavity.

Urinary bladder is normal in distension and wall is not thickened. Free internal echoes are seen in UB lumen.

Uterus is anteverted. Myometrium shows normal echo-pattern. No focal space occupying lesion is seen. Endometrial thickness is measuring ~ 9.2mm.

Both ovaries are normal.

No free fluid in pouch of douglas.

PLEASE CORRELATE CLINICALLY.

Figure 1: Ultrasound of whole abdomen suggestive of cholelithiasis.

Inferolateral subhepatic right sided gallbladder was not identified; no additional findings warranted further evaluation with more sensitive imaging modalities, such as magnetic resonance cholangiopancreatography, for preoperative diagnosis of this anatomical variant. Elective laparoscopic cholecystectomy was therefore indicated for symptom management. During the procedure, the gallbladder was observed entirely to the right side at inferolateral subhepatic location in relation to hepatic segment V, VI (Figures 2 and 3) establishing the diagnosis of inferolateral subhepatic gallbladder.

Careful dissection of Calot's triangle was performed in accordance with the principles of the critical view of safety; the cystic duct and cystic artery were isolated, and normal biliary anatomy was confirmed. In the absence of laboratory abnormalities or clinical features suggestive of distal biliary obstruction such as choledocholithiasis, cholestatic jaundice, strictures or ductal dilation previously excluded on preoperative ultrasonography-intraoperative cholangiography was not performed. The procedure proceeded with clipping of the cystic duct and cystic artery, followed by removal of the gallbladder (Figure 4). The procedure was uneventful, and the patient was discharged on postoperative day 3 without symptoms. At outpatient follow-up on postoperative day 7 and again on day 30.

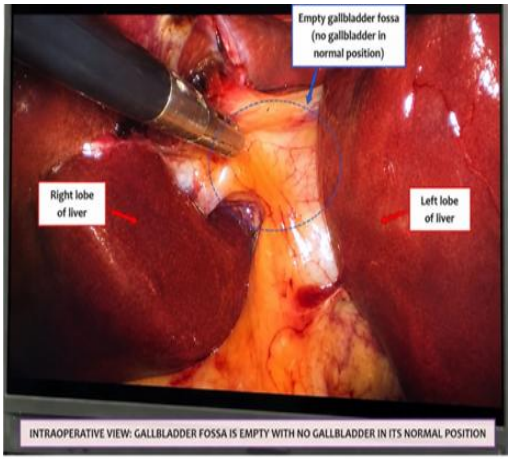

Figure 2: Initial laparoscopic view showing empty gallbladder fossa.

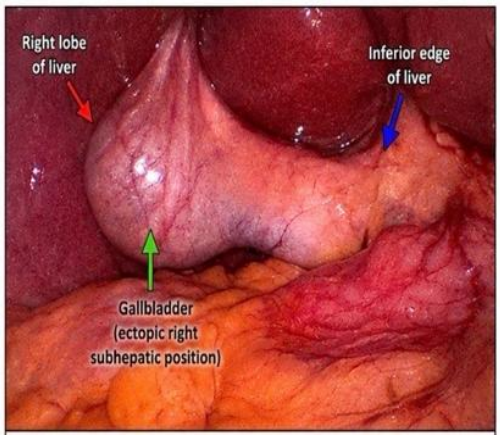

Figure 3: Initial laparoscopic view showing the gallbladder in right inferolateral subhepatic position, located inferior to the right hepatic lobe.

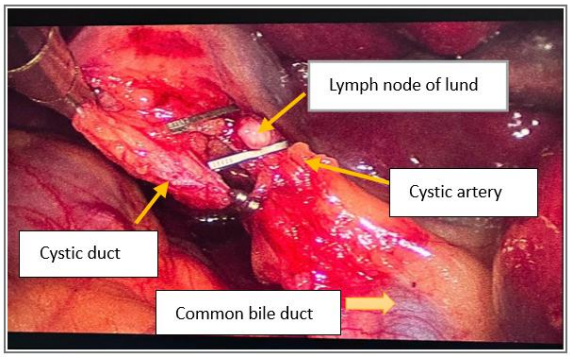

Figure 4: Post-clipping image of critical view of safety.

DISCUSSION

The gallbladder normally lies within the gallbladder fossa on the visceral surface of the liver, between hepatic segments IVB and V. Although variations in the biliary tree are relatively common, ectopic gallbladder positions are rare. Reported ectopic locations include left-sided, intrahepatic, suprahepatic, retro-hepatic, retroperitoneal, transverse, and subhepatic positions. These anatomical variations arise from abnormalities during embryological development and migration of the gallbladder.[2,3,5] A right subhepatic gallbladder is an uncommon congenital anomaly resulting from abnormal embryological migration during fetal development.[4,5] Clinically, patients with a subhepatic gallbladder usually present with symptoms similar to those of conventional gallstone disease, including right upper quadrant pain, nausea, vomiting, and dyspepsia.

Consequently, preoperative recognition of the anomaly can be challenging. Ultrasonography may demonstrate cholelithiasis but can fail to identify the abnormal gallbladder position, particularly when the anomaly is isolated and not associated with other biliary abnormalities.[2-4] In the present case, ultrasonography revealed cholelithiasis without suggesting an ectopic gallbladder, and the anomaly was identified only during laparoscopic surgery .The major surgical significance of a inferolateral subhepatic gallbladder is the altered anatomical relationship of Calot's triangle and the possibility of associated biliary or vascular anomalies. Variations in the extrahepatic biliary anatomy are well documented and may significantly influence the safety of cholecystectomy.[1,2,5]

These variations can make laparoscopic dissection technically challenging and increase the risk of iatrogenic bile duct injury. Therefore, when the gallbladder is not identified in its expected anatomical location, the surgeon should maintain a high index of suspicion and avoid proceeding with routine dissection until the anatomy is clearly understood.[6-8] Laparoscopic cholecystectomy remains the standard treatment for symptomatic gallstone disease, including in patients with ectopic gallbladders.[4,9-11] Safe surgery requires meticulous adhesiolysis, careful identification of the cystic duct and cystic artery, and strict achievement of the Critical View of Safety (CVS) as described by Strasberg.[6,8] The CVS requires clearance of the hepato-cystic triangle, separation of the lower third of the gallbladder from the cystic plate, and confirmation that only two structures enter the gallbladder before clipping and division.[8]

When the biliary anatomy remains unclear, adjunctive measures such as intraoperative cholangiography, subtotal cholecystectomy, or conversion to open surgery should be considered to minimize the risk of bile duct injury.[6-8] In our patient, the right inferolateral subhepatic gallbladder was identified incidentally during laparoscopic cholecystectomy. Despite the unexpected anatomical variation, careful dissection enabled clear identification of the cystic duct and cystic artery and the critical view of safety was achieved before clipping and division.

The procedure was completed laparoscopically without biliary injury or conversion to open surgery, and the postoperative course was uneventful. This case emphasizes the importance of anticipating uncommon gallbladder anatomical variations during laparoscopic cholecystectomy. Even when preoperative imaging does not demonstrate an ectopic position, surgeons should be prepared to modify their operative approach according to intraoperative findings. Thorough knowledge of biliary anatomy, meticulous dissection, and adherence to established principles of safe cholecystectomy are essential for preventing bile duct injury and achieving favourable outcomes.[1,2,5-8]

CONCLUSION

A right inferolateral subhepatic gallbladder is a rare anatomical variation that can present significant technical challenges during laparoscopic cholecystectomy. Routine ultrasonography may fail to identify the abnormal position, resulting in standard port placement and operative strategies that may provide suboptimal visualization and ergonomics. We would like to suggest for a 3rd port (midclavicular) inferolateral subhepatic gall bladder, the 4th port (right anterior axillary line) should be made more inferiorly and inferolateral respectively, for safe dissection of Calots and gall bladder bed. In suspected or complex cases, advanced preoperative imaging such as magnetic resonance cholangiopancreatography (MRCP) may help delineate the biliary anatomy and facilitate appropriate surgical planning, particularly when associated biliary anomalies are suspected. However, when the anomaly is discovered incidentally, early recognition, appropriate modification of port placement and operative ergonomics, and meticulous dissection are essential. Above all, strict adherence to the critical view of safety remains paramount to minimizing the risk of iatrogenic biliary injury and ensuring successful laparoscopic management.

Funding: No funding sources
Conflict of interest: None declared
Ethical approval: The study was approved by the Institutional Ethics Committee

REFERENCES

1. Benson EA, Page RE. A practical reappraisal of the anatomy of the extrahepatic bile ducts and arteries. Br J Surg. 1976;63(11):853-60.
2. Puente SG, Bannura GC. Radiological anatomy of the biliary tract: variations and congenital abnormalities. World J Surg. 1983;7(2):271-6.

3. Dhulkotia A, Kumar S, Kabra V, Shukla HS. Aberrant gallbladder situated beneath the left lobe of liver. HPB (Oxford). 2002;4(1):39-42.
4. Gu W, Tong Z. Ectopic gallbladder: a case report and review of the literature. Asian J Surg. 2020;43(9):950-2.
5. Skandalakis JE, Colborn GL, Weidman TA, Foster RS Jr, Kingsnorth AN, Skandalakis LJ, et al. Skandalakis' surgical anatomy: the embryologic and anatomic basis of modern surgery. Athens: Paschalidis Medical Publications; 2004.
6. Strasberg SM. Biliary injury in laparoscopic surgery: part 2. Changing the culture of cholecystectomy. J Am Coll Surg. 2005;201(4):604-11.
7. Hugh TB. New strategies to prevent laparoscopic bile duct injury—surgeons can learn from pilots. Surgery. 2002;132(5):826-35.
8. Strasberg SM, Brunt LM. Rationale and use of the critical view of safety in laparoscopic cholecystectomy. J Am Coll Surg. 2010;211(1):132-8.
9. Brunicardi FC, Andersen DK, Billiar TR, Dunn DL, Kao LS, Hunter JG, et al., editors. Schwartz's principles of surgery. 11th ed. New York: McGraw-Hill Education; 2019.
10. O'Connell PR, McCaskie AW, Sayers RD, editors. Bailey & Love's short practice of surgery. 28th ed. Boca Raton (FL): CRC Press; 2023.
11. Townsend CM Jr, Beauchamp RD, Evers BM, Mattox KL, editors. Sabiston textbook of surgery: the biological basis of modern surgical practice. 21st ed. Philadelphia: Elsevier; 2022.

Cite this article as: Patel FA, Singh A, Sharma R, Singh A, Singh S. Laparoscopic cholecystectomy in an ectopic (subhepatic) gallbladder: a rare anatomical variant. Int Surg J 2026;13:2627-30.