International Surgery Journal
Keshava CJ et al. Int Surg J. 2026 Dec;13(12):2623-2626
https://www.ijsurgery.com
pISSN 2349-3305 | eISSN 2349-2902

DOI: https://dx.doi.org/10.18203/2349-2902.isj20264375

Case Report

Large culture-negative left psoas abscess with extension into anterior thigh compartment mimicking an inguinal abscess: a diagnostic dilemma — a rare case report and review of literature

Keshava C. J.*, Pradeep Y. M., Shankar Lal J., Saajan Shetty A.

Department of General Surgery, Hassan Institute of Medical Sciences, Hassan, Karnataka, India

Received: 10 September 2026
Revised: 16 October 2026
Accepted: 13 November 2026

***Correspondence:**
Dr. Keshava C. J.,
E-mail: keshavakeshu480@gmail.com

Copyright: © the author(s), publisher and licensee Medip Academy. This is an open-access article distributed under the terms of the Creative Commons Attribution Non-Commercial License, which permits unrestricted non-commercial use, distribution, and reproduction in any medium, provided the original work is properly cited.

ABSTRACT

Psoas abscess is a rare entity with extension into the anterior thigh compartment beneath the inguinal ligament being extremely rare and often misdiagnosed as inguinal abscess, femoral hernia or lymphadenitis leading to inappropriate groin exploration. We report a 60-year-old male farmer who presented with left inguinal swelling for 15 days, anterior thigh pain, limping, low-grade fever and low back pain for one month. Examination revealed 8×6 cm tender, fluctuant swelling in left inguinal region extending to anterior thigh with positive psoas sign and painful hip movements. Laboratory investigations showed leukocytosis with neutrophilia, elevated erythrocyte sedimentation rate (ESR) and C-reactive protein (CRP). Ultrasonography revealed heterogeneous collection in left psoas tracking to groin and thigh. Contrast-enhanced computed tomography showed large peripherally enhancing hypodense collection measuring 15×4.5×4.1 cm involving left psoas muscle from L3 level extending beneath inguinal ligament into anterior thigh compartment abutting femoral neurovascular bundle without thrombosis. Diagnosis of primary psoas abscess with thigh extension was made. Broad-spectrum antibiotics were started and ultrasound-guided 12 Fr pigtail catheter drainage was performed with 300 ml purulent pus drained over three days. Culture was sterile due to prior antibiotics. Patient improved dramatically within 48 hours and no recurrence at 3 months follow-up.

Keywords: Psoas abscess, Culture-negative, Anterior thigh compartment, Inguinal abscess, Diagnostic dilemma, Pigtail drainage

INTRODUCTION

Psoas abscess was first described by Mynter in 1881.[1] It is defined as collection of pus in psoas muscle compartment. It is classified as primary (hematogenous spread from occult source, commonly staphylococcus aureus, no identifiable adjacent source) and secondary (direct spread from adjacent structures like appendix, colon, small bowel, kidney, and spine).[2,3] Secondary type is more common in India due to higher prevalence of tuberculosis. Several studies have reported that primary psoas abscess is associated with immunocompromised states, diabetes, intravenous drug abuse and trauma.[2,3] Clinically reported studies have shown that incidence is rare with 0.4 per 100,000 in developed countries and up to 12 per 100,000 in developing countries.[4] Few studies have documented that classic triad of fever, back pain and limp is present in only 30% of cases making diagnosis difficult.[3,5] Anatomy explains thigh extension: psoas major originates from T12-L5 vertebrae, joins iliacus to form iliopsoas, passes beneath inguinal ligament via lacuna musculorum and inserts onto lesser trochanter.[6] Its sheath is continuous with femoral sheath and fascia lata of thigh, hence pus can track beneath inguinal ligament into anterior thigh compartment, presenting as inguinal swelling. This extension is reported in less than 5% cases and can be misdiagnosed as inguinal abscess, femoral hernia, inguinal lymphadenitis, or soft tissue tumor of thigh.[7,8]

CASE REPORT

A 60-year-old male farmer from Hassan, Karnataka presented to casualty, HIMS with complaints of left inguinal swelling for 15 days, gradually progressive, painful, left anterior thigh pain and difficulty in walking/limping for 10 days, low-grade fever with chills for 7 days, low back pain since 1-month dull aching.

No history of trauma, tuberculosis, urinary symptoms, bowel symptoms, weight loss, diabetes, immunosuppression, spinal tuberculosis (TB) in past. He had taken oral antibiotics (amoxicillin-clavulanate) from local doctor for 5 days without relief.

On examination

Vitals: febrile 100.8F, HR 98/min, BP 126/80 mmHg, SpO_2 98% RA.

Local

Left inguinal region - 8×6 cm tender, warm, fluctuant swelling, erythematous skin, no cough impulse, no transillumination, fluctuation present extending to upper thigh anteriorly, no crepitus.

No inguinal lymphadenopathy separately palpable. No overlying sinus.

Psoas sign

Positive - pain on passive hip hyperextension and active flexion against resistance.

Spine

No deformity, mild tenderness over lumbar region, no gibbus.

Abdomen

Soft, no mass palpable separately, no organomegaly, no free fluid.

Hip movements

Painful flexion and extension, limited extension, flexion 0-100 degrees painful.

Systemic

No other findings.

Provisional diagnosis in casualty

Left inguinal abscess with thigh extension / soft tissue abscess of anterior thigh.

Investigations

Blood: Hb 12.5 g/dl, WBC 14,200 with neutrophilia (82%), ESR 58 mm/hour, CRP 86 mg/l, platelets 2.61 lakhs, RBS 87 mg/dl, urea 21.4, creatinine 0.78 mg/dl, LFT normal, HIV/HBsAg/HCV negative, and HbA1c 5.6%.

Chest X-ray

Chest X-ray was normal.

X-ray lumbar spine AP/lat

No obvious spondylodiscitis, no lytic lesion.

USG abdomen + inguinal region + thigh: heterogeneous collection in left psoas region 15×4.5 cm tracking along iliopsoas to groin and anterior thigh, volume ~140 cc, with internal echoes, no septations.

CECT abdomen and pelvis with thigh (contrast)

Large well-defined peripherally enhancing hypodense collection measuring 15×4.5×4.1 cm, volume ~140 cc, involving left psoas muscle from L3 level extending along iliopsoas sheath beneath inguinal ligament to upper thigh anterior compartment, involving iliacus and abutting femoral neurovascular bundle but no thrombosis, no bowel communication, no spinal involvement, no renal collection, no appendicular pathology. No intraperitoneal free fluid.

Impression

Primary psoas abscess with anterior thigh extension.

Management

Patient was started on broad-spectrum antibiotics as per hospital protocol for deep abscess: Inj. Piperacillin-tazobactam 4.5 g IV TID + Inj. Metronidazole 500 mg IV TID + Inj. Amikacin 500 mg IV BD after blood culture.

Intervention

Under USG guidance under local anesthesia, 12 Fr pigtail catheter placed via anterior approach, extraperitoneal, trans-inguinal route, avoiding femoral vessels. 180 ml thick purulent, non-foul-smelling pus drained on day 1, CECT volume was estimated ~140 cc at presentation, total drainage 300 ml over 3days included re-accumulation. Catheter fixed, connected to urobag.

Pus analysis

Gram stain: few pus cells, no organisms seen. Culture: sterile after 72 hours incubation - culture-negative due to prior antibiotics. Cytology negative for malignant cells.

CBNAAT/AFB for tuberculosis could not be performed due to lack of residual pus sample after routine analysis. Catheter flushed daily with 10 ml normal saline, kept for 7 days till output <10 ml/day, serous.

Post-procedure

Patient improved dramatically - fever subsided in 48 hours, pain reduced, able to extend hip, inguinal swelling reduced 80% in 5 days, WBC reduced to 7,280 on day 5, CRP to 24.

Repeat USG on day 7

Residual collection ~15 cc in psoas, no thigh collection. Pigtail removed on day 8, small dressing.

Patient discharged on day 9 on oral antibiotics Tab. Cefixime 200 mg BD + Tab. Metronidazole 400 mg TID for 14 days, analgesics, advised physiotherapy for hip.

Follow-up

At 2 weeks, wound healed, no swelling, no fever, able to walk without limp. At 1 month, USG: no residual collection. At 3 months: no recurrence, able to do routine farming activities, inflammatory markers normalized (CRP 4.2, ESR 18, WBC 7,200).

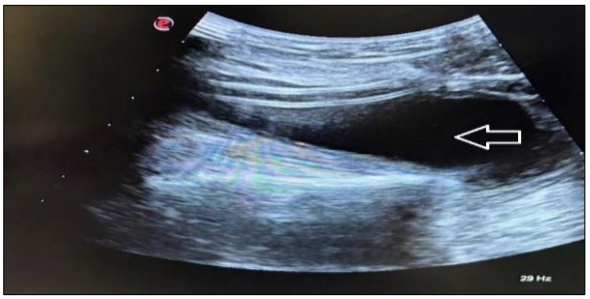

Figure 1: Ultrasonography of left thigh showing large well-defined anechoic collection with internal echoes suggestive of abscess in anterior compartment.

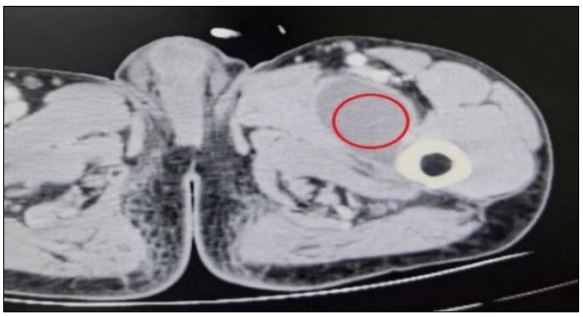

Figure 2: CECT axial section at mid-thigh level showing large rim-enhancing collection in anterior compartment of left thigh (red circle) around femoral shaft - extension from left psoas abscess beneath inguinal ligament.



Figure 3: Real-time USG showing needle tip (white arrow) entering the abscess cavity-Seldinger technique.



Figure 4: 12 Fr pigtail catheter placed in left thigh collection under USG guidance, fixed to skin, with frank purulent pus collected in urobag.

DISCUSSION

This case highlights a diagnostic dilemma of psoas abscess mimicking inguinal abscess.

In the present study, a 60-year-old male farmer presented with inguinal swelling, thigh pain, limping, fever and low back pain. Mean age of psoas abscess with thigh extension reported in previous studies is 54 years with male predominance (77% cases), which correlates with present case being 60-year male.[2,5,7] Chern et al reported 56-year male with groin mass, Tabrizian et al 45-year male with thigh pain, Zhou et al 55-year male from India with inguinal abscess, similar to our presentation.[5,6,8]

Size and volume

Present case had large collection measuring 15×4.5×4.1 cm with 300 ml pus drained over 3 days, which is larger than average size reported in literature (average 10.6 cm). Garner et al reported 14 cm collection with anterior thigh extension, Asenov et al reported 13 cm, Tabrizian et al reported 12 cm, while Santaella et al reported 9 cm.[6-8]

Thus, our case represents largest collection among reported cases managed successfully by pigtail alone.[5]

Primary versus secondary

Our case is primary because no adjacent source was found on CECT. Primary cases are more common in younger patients but can occur in elderly without comorbidities as in our case, similar to findings of Ricci et al and Tabrizian et al.[2,5]

Culture negativity

Reported in 20-30% cases due to prior antibiotics. In present case patient had taken amoxicillin-clavulanate for 5 days before presentation leading to sterile culture. Similar culture-negative cases were reported by Santaella et al, Garner et al and Asenov et al in India due to over-the-counter antibiotic use.[7-9] Prior antibiotic use does not change management if adequate drainage and empiric broad-spectrum antibiotics are given.[3,4,9]

Diagnostic challenge

In casualty inguinal swelling with fever is commonly misdiagnosed as inguinal lymphadenitis, incarcerated femoral hernia or groin abscess. Previous studies by Chern et al described misdiagnosis as groin mass, Santaella et al as femoral hernia, Garner et al as inguinal lymphadenitis, Asenov et al as soft tissue thigh tumor.[7,8] Incision and drainage over groin without addressing psoas source leads to persistent fistula and recurrence.[5] High index of suspicion is needed when elderly patient presents with back pain, inguinal swelling, limp, fever and positive psoas sign. CECT is gold standard with sensitivity 90-100% and specificity 95% for diagnosis and delineating thigh extension.[3,4]

Management evolution

Historically open extraperitoneal drainage was gold standard. Now image-guided percutaneous drainage with pigtail catheter is first-line with success rate 80-90%, less morbidity and shorter hospital stay.[2,3,5,8] Chern et al and Tabrizian et al managed with open extraperitoneal drainage, while Santaella et al, Garner et al, Zhou et al and Asenov et al managed with percutaneous drainage or pigtail similar to present case.[6,8,9] Our case responded excellently to 12Fr pigtail with 300 ml drainage, which is largest in literature managed by pigtail alone without open surgery.[5,8]

Outcome

In present case fever subsided in 48 hours, 80% swelling reduction by day 5 and no recurrence at 3 months. Similar excellent outcomes with pigtail drainage were reported by Singh et al and Asenov et al in Indian population with no recurrence.[8,9]

CONCLUSION

Giant culture-negative primary psoas abscess extending into anterior thigh compartment mimicking inguinal abscess is a rare diagnostic dilemma. Early CECT, high index of suspicion, and timely image-guided pigtail drainage can prevent misdiagnosis, avoid unnecessary groin exploration and result in excellent outcome. Not all inguinal swellings are inguinal in origin - look beyond groin to psoas.

Funding: No funding sources
Conflict of interest: None declared
Ethical approval: Not required

REFERENCES

1. Mynter H. Acute psoitis. Buffalo Med Surg J. 1881;21:202-10.
2. Ricci MA, Rose FB, Meyer KK. Psoas abscess: A review. Am J Surg. 1986;151:412-6.
3. Santaella RO, Fishman EK, Lipsett PA. Psoas abscess: diagnosis and management. J Am Coll Surg. 1995;181:365-70.
4. Chern CH, Hu SC, Kao WF, Tsai J, Yen D, Lee CH. Psoas abscess: making an early diagnosis in the ED. Am J Emerg Med. 1997;15(1):83-8.
5. Tabrizian P, Nguyen SQ, Greenstein A, Rajhbeharrysingh U, Divino CM. Management and treatment of iliopsoas abscess. Arch Surg. 2009;144(10):946-9.
6. Garner JP, Meiring PD, Ravi K, Gupta R. Psoas abscess - not as rare as we think? Colorectal Dis. 2007;9(3):269-74.
7. Zhou Z, Song Y, Cai Q, Zheng J. Primary psoas abscess extending to thigh adductors: case report. BMC Musculoskelet Disord. 2010;11:176.
8. Asenov Y, Dimitrov IV, Kotsev M, Angelov T, Golemanov B, Getsov P, et al. Beyond the psoas: iliopsoas abscess with thigh extension successfully managed by percutaneous approach. J Surg Case Rep. 2025;2025(10):rjaf792.

Cite this article as: Keshava CJ, Pradeep YM, Shankar Lal J, A Saajan Shetty. Large culture-negative left psoas abscess with extension into anterior thigh compartment mimicking an inguinal abscess: a diagnostic dilemma — a rare case report and review of literature. Int Surg J 2026;13:2623-6.