International Surgery Journal
Nandigam SSN et al. Int Surg J. 2026 Dec;13(12):2620-2622
https://www.ijsurgery.com
pISSN 2349-3305 | eISSN 2349-2902

DOI: https://dx.doi.org/10.18203/2349-2902.isj20264374

Case Report

Duplication of gallbladder with single cystic duct: a case report of a rare anatomical variant

Suhas Sai Nandaphani Nandigam*, Haritha Rameni, Jitendra Narayan Senapati

Department of General Surgery, IMS and SUM Hospital, Bhubaneswar, Odisha, India

Received: 27 August 2026
Revised: 07 October 2026
Accepted: 27 October 2026

***Correspondence:**
Dr. Suhas Sai Nandaphani Nandigam,
E-mail: suhasnandigam@gmail.com

Copyright: © the author(s), publisher and licensee Medip Academy. This is an open-access article distributed under the terms of the Creative Commons Attribution Non-Commercial License, which permits unrestricted non-commercial use, distribution, and reproduction in any medium, provided the original work is properly cited.

ABSTRACT

Gallbladder duplication is a rare congenital biliary anomaly with important surgical implications. A 33-year-old woman presented with recurrent biliary colic for 3 months, aggravated by fatty meals. Examination showed mild right hypochondrial tenderness without clinical obstructive jaundice. Liver function tests were within normal limits. Ultrasonography suggested gallbladder duplication with multiple calculi and magnetic resonance cholangiopancreatography (MRCP) showed two adjacent gallbladder structures in the gallbladder fossa with a likely common cystic duct insertion. Laparoscopic cholecystectomy was completed without a reported intraoperative complication. Histopathological examination of the submitted gallbladder showed chronic cholecystitis with cholesterolosis, without definite dysplasia or malignancy. The cholesterol calculus was submitted separately. The postoperative course was uneventful, and the patient was discharged on postoperative day 2. This case emphasizes the value of preoperative recognition and careful assessment of biliary anatomy.

Keywords: Gallbladder duplication, Common cystic duct, MRCP, Laparoscopic cholecystectomy, Biliary anomaly

INTRODUCTION

Gallbladder duplication is an uncommon congenital anomaly of the biliary system that arises from abnormal development of the gallbladder primordium. Its reported incidence is approximately 1 in 3,000–4,000 individuals, although estimates vary between reports. Recent case reports and reviews by Arif et al, Panday et al and Zhuang et al describe the range of presentations and the importance of defining the biliary anatomy before surgery.[1-3] Anatomical patterns include duplicated gallbladders with a common cystic duct and those with separate cystic ducts.[1-2] Although duplication may remain asymptomatic, it can be associated with cholelithiasis and inflammation. Recognition is important because an unrecognized gallbladder component or atypical cystic duct anatomy may complicate cholecystectomy.[4-6] Ultrasonography may suggest the anomaly, while MRCP can help define the anatomy before surgery.[4-9] We report a symptomatic adult with imaging findings suggestive of gallbladder duplication with a common cystic duct who underwent laparoscopic cholecystectomy.

CASE REPORT

A 33-year-old woman presented to the outpatient department with recurrent biliary colic for 3 months, aggravated by fatty meals. No underlying comorbidities were documented. She had no history of alcohol consumption or smoking. Abdominal examination revealed a soft abdomen with mild right hypochondrial tenderness. There were no clinical features of obstructive jaundice. Liver function tests were within normal limits, and no coagulopathy was documented. Ultrasonography

of the abdomen and pelvis suggested gallbladder duplication with multiple calculi. MRCP demonstrated two gallbladder structures adjacent to each other in the gallbladder fossa, with a likely single cystic duct insertion; multiple calculi were also reported.



Figure 1: MRCP demonstrating two adjacent gallbladder structures in the gallbladder fossa with a suspected common cystic duct configuration.

The patient underwent laparoscopic cholecystectomy, which was completed without a reported intraoperative complication. The available operative record does not detail any anomalies in cystic artery; intraoperative cholangiography was not performed as duplication was visible intraoperatively and no evidence of Mirizzi syndrome.

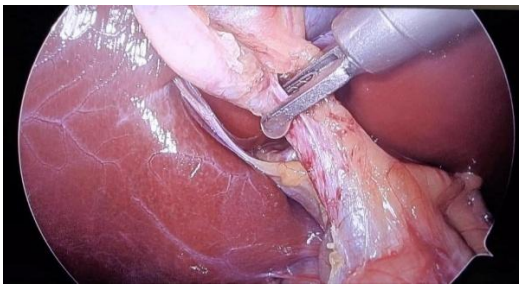

Figure 2: Intraoperative laparoscopic view demonstrating the duplicated gallbladder anatomy.

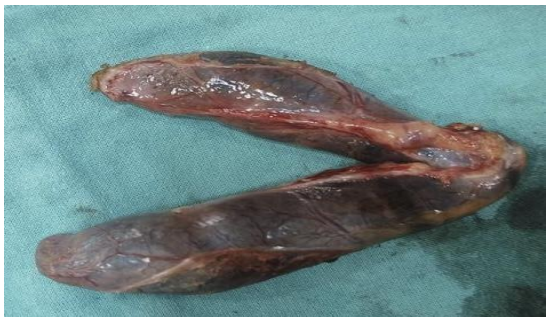

Figure 3: Gross specimen demonstrating the duplicated gallbladder components.

Postoperative recovery was uneventful. Oral intake was gradually advanced, and the patient was discharged on postoperative day 2. Longer-term follow-up information was not available in the supplied record.

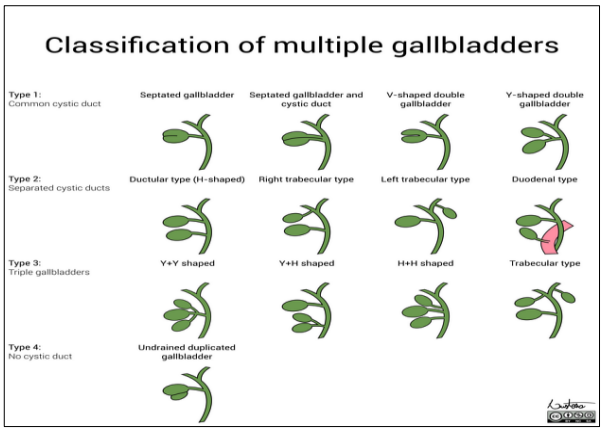

Figure 4: Classification of multiple gallbladders according to the Harlaftis system.

DISCUSSION

Gallbladder duplication is commonly described using the Harlaftis classification, which groups anomalies according to the configuration of the gallbladders and their cystic ducts. Type I (split primordium) variants include Septate, V-shaped and Y-shaped forms, usually with a common cystic duct; Type II (accessory gallbladder) variants have separate drainage patterns, including ductular and trabecular forms. The classification is useful for describing anatomy and planning safe biliary surgery.[1-2]

A recent report by Spiliotis and Maurer described a V-shaped duplicated gallbladder with a single cystic duct and chronic cholecystitis, supporting the importance of preoperative recognition of variant biliary anatomy and careful dissection during laparoscopic cholecystectomy.[7] Gallbladder duplication is a rare developmental anomaly with several recognized anatomical configurations. Boyden described accessory gallbladders, while Harlaftis and colleagues proposed a classification based on embryological development and ductal arrangement.[4,5] Causey et al subsequently reviewed the spectrum of gallbladder duplication and emphasized the variability of these configurations.[6] Correctly describing the cystic duct relationship is important because the term “duplicated gallbladder” alone does not fully define the anatomy encountered at surgery.

In the present case, ultrasonography and MRCP suggested two adjacent gallbladder structures with a likely common cystic duct insertion. Arif et al. described a duplicated gallbladder with a single cystic duct and a gallbladder polyp, although their anomaly was recognized intraoperatively.[1] Panday et al reported a double gallbladder with a common cystic duct and highlighted the usefulness of preoperative MRCP for defining the variant anatomy.[2] Zhuang et al reported intraoperative recognition of gallbladder duplication in a patient with a choledochal cyst.[3] These reports illustrate that the anomaly may be identified before or during

surgery, depending on the configuration and clarity of preoperative imaging. The patient's recurrent biliary colic and imaging evidence of multiple calculi are consistent with published reports describing symptomatic gallbladder duplication associated with gallstone disease.[1,2,8,9] Al Rawahi et al reported successful laparoscopic management of a duplicated gallbladder, while Rajapandian et al. discussed the importance of defining a Y-shaped configuration before division of the ductal structures.[8,9]

Maddox and Demers also described laparoscopic management of gallbladder duplication.[10] These case reports support laparoscopic treatment in selected patients when the anatomy can be safely delineated; however, case reports cannot establish comparative complication rates or superiority of one approach. Preoperative imaging was important in the present case. Ultrasonography raised suspicion of duplication, and MRCP further demonstrated two adjacent gallbladder structures and a likely common cystic duct insertion. MRCP is useful for non-invasive assessment of biliary anatomy and can assist operative planning.[1,2,8,9] Intraoperative cholangiography may be considered when the ductal anatomy remains uncertain. During cholecystectomy, careful dissection and secure identification of the cystic duct and cystic artery remain essential to reduce the risk of biliary injury.

Histopathological examination of the submitted gallbladder showed chronic cholecystitis with cholesterolosis and no definite dysplasia or malignancy. No definite polyp was identified grossly in the submitted gallbladder specimen. The cholesterol calculus was submitted separately, accounting for its absence in the gallbladder specimen. This distinction is important when correlating operative findings with pathology results. Arif et al. reported a gallbladder polyp in a duplicated gallbladder, illustrating that pathology findings can vary between cases.[1]

The principal value of this case is the preoperative suspicion of gallbladder duplication with a likely common cystic duct, successful laparoscopic treatment, and histopathological confirmation of chronic cholecystitis with cholesterolosis. Detailed operative anatomy and longer-term follow-up were not available, limiting further comparison with previously published cases.

CONCLUSION

Gallbladder duplication is an uncommon biliary anomaly that may present with symptomatic cholelithiasis. Preoperative recognition with ultrasonography and MRCP can facilitate operative planning. Careful identification of the cystic duct and complete management of both gallbladder components are important during cholecystectomy to reduce the risk of residual disease and biliary injury.

Funding: No funding sources
Conflict of interest: None declared
Ethical approval: Not required

REFERENCES

1. Arif SH, Hussein IS, Mohammed AA. Duplicated gall bladder with gall bladder polyp presenting with cholecystitis: case report with literature review. Int J Surg Case Rep. 2019;60:103-5.
2. Panday B, Dangol RS, Joshi MD, Acharya B, Bijukchhe SM, Subedi K, et al. Double gallbladder: a case report and review of literature. Ann Med Surg (Lond). 2026;88(1):785-8.
3. Zhuang H, Ma Z, Yin Z, Hou B, Zhang C. Incidental intraoperative finding of gallbladder duplication in a patient with a choledochal cyst. J Int Med Res. 2020;48(5):300060520924570.
4. Boyden EA. The accessory gall-bladder: an embryological and comparative study of aberrant biliary vesicles occurring in man and the domestic mammals. Am J Anat. 1926;38(2):177-231.
5. Harlaftis N, Gray SW, Skandalakis JE. Multiple gallbladders. Surg Gynecol Obstet. 1977;145(6):928-34.
6. Causey MW, Miller S, Fernelius CA, Burgess JR, Brown TA, Newton C. Gallbladder duplication: evaluation, treatment, and classification. J Pediatr Surg. 2010;45(2):443-6.
7. Spiliotis PM, Maurer CA. Gallbladder duplication: case report of a rare clinical entity. Int J Clin Case Rep Rev. 2025;30(5):1-6.
8. Al Rawahi A, Al Azri Y, Al Jabri S, Alfadli A, Al Aghbari S. Successful laparoscopic management of duplicate gallbladder: a case report and review of literature. Int J Surg Case Rep. 2016;21:142-6.
9. Rajapandian S, Jankar SV, Nayak D, Chittawadgi B, Sabnis SC, Sathyamoorthy R, et al. Laparoscopic management of 'Y-shaped' gallbladder duplication with review of literature. J Minim Access Surg. 2017;13(3):231-3.
10. Maddox JM, Demers ML. Laparoscopic management of gallbladder duplication: a case report and review of literature. JSLS. 1999;3(2):137-40.

Cite this article as: Nandigam SSN, Rameni H, Senapati JN. Duplication of gallbladder with single cystic duct: a case report of a rare anatomical variant. Int Surg J 2026;13:2620-2.