International Surgery Journal
Srivastava R et al. Int Surg J. 2026 Dec;13(12):2569-2573
https://www.ijsurgery.com
pISSN 2349-3305 | eISSN 2349-2902

DOI: https://dx.doi.org/10.18203/2349-2902.isj20264365

Case Series

Use of dental moulds as a cost-effective method for stenting of neovaginal cavity created in patients with MRKH syndrome: a case series

Richa Srivastava, Amber Das, Shreya Pandey*

Department of Plastic, Craniofacial and Microsurgery, Vivekananda Polyclinic & Institute of Medical Sciences, Lucknow, U.P., India

Received: 30 June 2026
Revised: 17 September 2026
Accepted: 13 November 2026

***Correspondence:**
Dr. Shreya Pandey,
E-mail: shreya.pandey.0896@gmail.com

Copyright: © the author(s), publisher and licensee Medip Academy. This is an open-access article distributed under the terms of the Creative Commons Attribution Non-Commercial License, which permits unrestricted non-commercial use, distribution, and reproduction in any medium, provided the original work is properly cited.

ABSTRACT

Vaginal agenesis is a rare congenital anomaly most commonly associated with Mayer Rokitansky Kuster Hauser (MRKH) Syndrome. While non-surgical dilatation techniques are undertaken for management of vaginal agenesis, various surgical techniques have also been used by surgeons across the world, including McIndoe vaginoplasty, Vecchietti procedure, Davydov peritoneal vaginoplasty and more. Vaginal stents or moulds are routinely used post-surgery to maintain the cavity depth and to prevent stenosis during the healing phase. Commercial vaginal moulds are often expensive and unavailable in resource-limited settings. We provide an alternative, less expensive method to achieve the same end goal following McIndoe vaginoplasty. A custom fabricated mould using thermoplastic dental impression material provides a simple and economical alternative to the conventionally used vaginal moulds. During surgery, the mould is inserted into the created neovagina after placement of the skin graft. This helps maintain graft adherence, prevents hematoma formation and preserves vaginal depth during early post-operative period. Regular monitoring and gradual mould removal or replacement allows appropriate epithelisation and healing. This case series includes a total of 20 cases of MRKH Syndrome in whom dental impression material was used to make customised vaginal moulds. Conclusion: Customisable dental moulds can serve as an effective and economical vaginal stent following vaginoplasty, with satisfactory functional outcomes and potential applicability in resource-limited settings.

Keywords: MRKH Syndrome, Vaginal agenesis, McIndoe vaginoplasty, Dental moulds, Vaginal stents

INTRODUCTION

Vaginal agenesis is a rare congenital anomaly most commonly associated with Mayer–Rokitansky–Küster–Hauser (MRKH) syndrome, characterized by failure of Müllerian duct development in phenotypic females with normal secondary sexual characteristics and a functional ovarian axis. The estimated incidence is approximately 1 in 4,500–5,000 female births.[1] Two types of vaginal agenesis have been notes: Type 1, also known as Isolated Müllerian aplasia or Rokitansky involves only uterovaginal agenesis- and Type 2 uterovaginal agenesis along with renal, cardiac, or other organ anomalies.[2]

Management of a female with an absent vagina aims at creation of a functionally adequate neovagina to allow satisfactory sexual function and improve psychosocial well-being. Non-surgical dilation techniques[3] are considered first-line therapy; however, surgical vaginoplasty becomes necessary in patients with failed conservative management, severe agenesis, scarring, or patient preference.

Several surgical techniques have been described, including (1) McIndoe vaginoplasty; (2) Vecchietti procedure; (3) Davydov peritoneal vaginoplasty; (4) Intestinal vaginoplasty. McIndoe vaginoplasty is known to be a safe and effective procedure for providing a functional and satisfactory vagina.[4,5] Other methods using autologous fenestrated buccal mucosal graft.[4] and tissue engineered biomaterial mesh[7] have also been used by some surgeons which have provided satisfactory results.

Despite advances in surgical technique, postoperative maintenance of neovaginal patency remains a major challenge. Vaginal moulds or stents are essential to prevent graft contraction, stenosis, and cavity collapse. Conventional vaginal moulds or 3D-printed moulds[8] may be associated with high cost, limited availability, poor anatomical fit or patient discomfort leading to reduced compliance.

Recent interest has focused on custom-made low-cost innovations that improve patient comfort and surgical outcomes. Dental mould fabrication materials are widely available, biocompatible, and allow individualized shaping according to patient anatomy.

Present case series evaluates the feasibility and outcomes of vaginoplasty using a custom-fabricated dental mould as a postoperative stenting device.

CASE SERIES

This case series includes 20 patients between ages of 16-22 years with vaginal agenesis (Figure 1) who underwent vaginoplasty using the Mclndoe technique (Figure 2, 3 and 4) at a tertiary care center between 2024-2025.



Figure 1: Vaginal agenesis in a case of MRKH Syndrome.



Figure 2: Split thickness skin graft harvested for lining the newly created vaginal cavity.



Figure 3: Customised dental mould covered with split thickness skin graft



Figure 4: Neovagina created using McIndoe technique.

Inclusion criteria included patients with confirmed diagnosis of MRKH syndrome; female patients aged 16-22 years; primary vaginal agenesis; normal secondary sexual characteristics; motivated for post-operative mould usage. Exclusion criteria included patients with other causes of vaginal agenesis; patients aged <16 years and >22 years; patients previously operated for vaginal agenesis; severe associated anomalies (cardiac, respiratory, etc.); psychiatric illness and inability to comply; unwillingness to follow up.



Figure 5: Thermoplastic material used for preparation of custom mould. Material is dipped in hot water, following which it loses it becomes soft and can subsequently be moulded as per the dimensions of the newly created vaginal cavity.

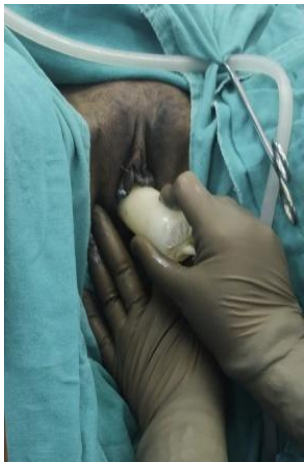

Figure 6: Customised mould to be used after post-op week 3.

A patient specific dental mould was fabricated using dental impression material (Figure 5). A thermoplastic material which can be moulded into the desired shape and length was used and moulds were prepared pertaining to the created neovaginal cavity. These moulds were used for neovaginal stenting after 3 post-operative weeks [Fig. 6]. The material used has an added advantage that if the size of the custom mould is found to be greater than the created cavity, it can be re-modelled, which dispenses with the need for creation of a new mould and thus, additional expenditure of the patient's money.

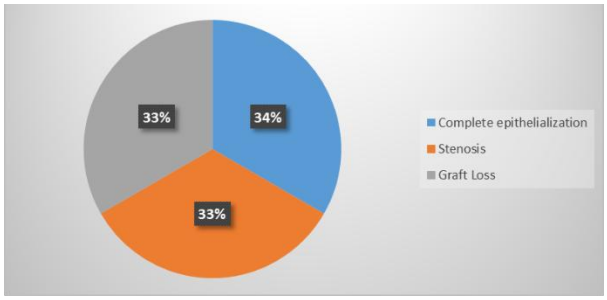

Figure 7: Final outcome (16-18 years).

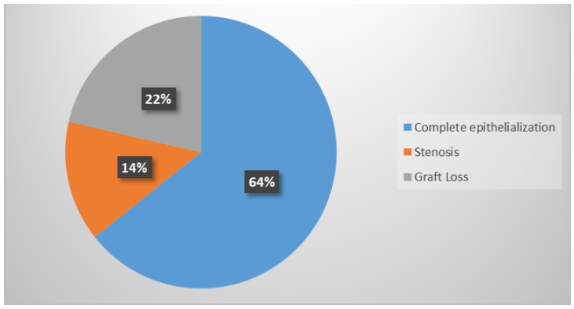

Figure 8: Final outcome (19-22 years).

Patients were followed up for assessment of neovaginal dimensions, epithelialization, compliance, complications and functional outcomes at 1, 3 and 6 months post-operatively.

A total of 20 patients were assessed for results after vaginoplasty. Mean age of patients taken up for neovagina creation was 19 years. Mean neovaginal length achieved was 8 cm.

Among the age group of 16-18 years (6 patients) (Figure 7), reduced compliance was noted–only 2 patients out of 6 were compliant to the given instructions - as the mould used is hard in consistency and the process of removal and re-application of the mould can be discomforting for the patient. Complete epithelialization occurred in 33.33% cases (2 patients). 66.67% cases (4 patients) experienced complications like graft loss (2 cases) and stenosis (2 cases).

Out of the 14 patients between ages of 19-22 years (Figure 8), complete epithelialization occurred in 64.29% cases (9 patients) by 6 weeks. Minor complications were seen in 35.71% cases (5 cases), including partial graft loss (3 cases) and mild stenosis (2 cases). Compliance with mould use was good in 85.71% cases (12 patients). At a mean follow-up of 3 months, functional outcomes were satisfactory in 78.57% of patients (11 patients).

DISCUSSION

The McIndoe technique for vaginal reconstruction remains a reliable and established surgical approach in patients with vaginal agenesis. However, the long-term success of the technique depends as much on the creation of an adequate neovaginal cavity and successful skin-graft take as it does on the maintenance of neovaginal dimensions during post-operative healing phase. The anatomical and functional outcomes of reconstruction may be compromised due to post-operative contraction, scar formation and stenosis. Vaginal moulds or stents, therefore, play an important role in maintaining the neovaginal cavity as they support graft adherence during the early postoperative period and facilitate the prevention of subsequent contracture. Nevertheless, the optimal design and material of a vaginal mould remain a topic of debate, with considerable variation in the devices described earlier.[9]

Conventional vaginal moulds have been fabricated using a variety of materials, including acrylic, silicone, polyacetal and plastic tubing with focus on structural rigidity, adequate tissue support, patient comfort and ease of insertion and removal. Although rigid moulds may provide effective structural support, excessive pressure or a larger size can contribute to operative site trauma and subsequent complications. Conversely, softer materials may provide more comfort, but due to less consistent structural support, retention of the mould and thus, it's main purpose may get defeated. A systematic review by Jain et al highlighted substantial heterogeneity in the materials and designs of vaginal stents. The study concluded that the available evidence is insufficient to establish the superiority of one design over another.

There is further need for clinical evaluation of alternative mould designs.[9]

This study states that the use of dental thermoplastic material to fabricate a customised vaginal mould represents a potentially useful approach to post-operative management of the constructed neovagina, especially in the socio-economically weaker sections of the society. The rationale for this technique lies in the ability of the dental thermoplastic material to be fabricated as per the dimensions and contour of the reconstructed cavity, rather than relying on a prefabricated, non-customised mould. Customisation facilitates a more appropriate fit and permits adjustments according to individual anatomical requirements. However, these potential benefits should be interpreted in relation to the specific material employed, its mechanical properties and the fabrication protocol. Ease of moulding or customisation alone does not establish suitability for prolonged mucosal contact, and the material's biocompatibility, surface finish, dimensional stability, sterilisation compatibility and risk of tissue injury require further clinical evidence.

A previous study by Mishra et al described an indigenous technique for mould fabrication in McIndoe vaginoplasty using a 10-ml syringe as a framework, dental impression compound and gauze in the initial design, followed by an acrylic mould for longer-term dilatation.[10] This approach demonstrated the practical value of combining readily available materials with prosthetic fabrication techniques to address the need for postoperative moulding. Although the technique shares a conceptual similarity with the present study in that they both rely on economically affordable materials, a careful consideration of the property of these materials and fabrication methods is needed.

Other alternative materials have been tried by surgeons to address the limitations of conventional moulds. Kim et al described the use of a silicone gel sheet vaginal mould in McIndoe vaginoplasty, highlighting its application during reconstruction and subsequent postoperative stenting.[11] Another study reported the use of a specially designed perforated polyacetal mould in patients undergoing McIndoe-style vaginoplasty. The design aimed to facilitate drainage while maintaining graft support, and the authors reported favourable clinical outcomes.[12] These reports demonstrate that modifications in material, surface characteristics and mould architecture may address practical challenges associated with postoperative difficulties faced by patients of vaginal agenesis.

The present study aims to add to this evolving literature by evaluating a customised mould fabricated from dental thermoplastic material in patients undergoing McIndoe vaginoplasty. Its clinical relevance should be assessed in relation to the outcomes documented in the present series, including graft take, maintenance of neovaginal dimensions, ease of mould use and patient compliance. Compared with previously described devices, the principal contribution of the present technique is the affordability and the pliability of the material used along with the ease of insertion and removal that it offers.

However, practical the use of the mentioned material may be, it still has its limitations that should be acknowledged. The number of patients and duration of follow-up may limit the ability to identify uncommon complications or assess the long-term risk of neovaginal stenosis. In addition, postoperative outcomes are influenced by factors beyond the mould itself, including surgical technique, graft characteristics, postoperative wound care and adherence to the prescribed stenting or dilatation regimen. Unless specifically measured, patient comfort, cost-effectiveness, ease of use and improved compliance should not be inferred solely from the fabrication method. Furthermore, the suitability of the dental thermoplastic material for prolonged contact with healing vaginal tissue depends on its composition and validated processing and sterilisation requirements.

CONCLUSION

In conclusion, the use of dental thermoplastic material for customised vaginal mould fabrication represents a potential addition to the myriads of devices available for postoperative management following McIndoe vaginoplasty. The existing literature demonstrates considerable variation in mould design and material, while comparative evidence remains limited. The findings of the present case series may provide preliminary evidence regarding the feasibility and clinical utility of this approach. Larger prospective studies incorporating standardised anatomical, functional and patient-reported outcomes, longer follow-up and direct comparisons with established moulds are needed to determine its relative safety, effectiveness and role in routine clinical practice.

Funding: No funding sources
Conflict of interest: None declared
Ethical approval: Not required

REFERENCES

1. McIndoe AH. The treatment of congenital absence and obliterative conditions of the vagina. Br J Plast Surg. 1950;2:254-67.
2. Shah NA, Yadav M, Verma S, Yadav D, Yadav AK, Ghimire A, et al. McIndoe vaginoplasty in MRKH syndrome: case report and literature review. Clin Case Rep. 2024;12:e70009.
3. Chaudhary A, Acharya S, Dahal A, Basnet R, Basnet A, Dongol A. Mayer-Rokitansky-Küster-Hauser syndrome managed with McIndoe's vaginoplasty: a case series and literature review. Ann Med Surg (Lond). 2024;86:3206-10.
4. Kamal S, Tirkey S, Singh S, Chakraborty S. A clinical study of McIndoe vaginoplasty in vaginal

agenesis. Int J Reprod Contracept Obstet Gynecol. 2019;8.
5. Gowardhan AK, Bagade PM. A clinical study of modified McIndoe vaginoplasty with split thickness skin graft: a tertiary care experience. Int J Reprod Contracept Obstet Gynecol. 2020;9.
6. Teng Y, Zhu L, Chong Y, Zeng A, Liu Z, Yu N, et al. The modified McIndoe technique: a scar-free surgical approach for vaginoplasty with an autologous micromucosa graft. Urology. 2019;131:240-4.
7. Zhang X, Liu Z, Yang Y, Yao Y, Tao Y. Clinical outcomes of vaginoplasty using tissue-engineered biomaterial mesh in patients with Mayer-Rokitansky-Küster-Hauser syndrome. Int J Surg. 2017;44:9-14.
8. Pavan LI, Bourguignon GA, Ubertazzi EP. Vaginoplasty: modified McIndoe using xenograft and a tailored 3D-printer mold. Int Urogynecol J. 2021;32(8):2283-5.
9. Jain P, Jain S, Bansal A, Soni A. Variability in design and materials of vaginal stent or moulds for vaginal agenesis: a systematic review. J Hum Reprod Sci. 2024;17(3):158-69.
10. B, Janavar G, Pradeep Y, et al. Indigenous technique of fabricating vaginal mould for vaginal reconstruction and uterine drainage in McIndoe vaginoplasty using 10 ml syringe. Indian J Plast Surg. 2016;49(1):76-80.
11. Kim SW, Kim DY, Oh DY, et al. Use of a silicone gel sheet vaginal mold in McIndoe vaginoplasty. Arch Plast Surg. 2013;40(5):652-5.
12. Han SE, Go JY, Choi DS, Seo GH, Lim SY. Experience with specially designed pored polyacetal mold dressing method used in McIndoe-style vaginoplasty. J Pediatr Urol. 2017;13(6):621.e1-6.e6.

Cite this article as: Srivastava R, Das A, Pandey S. Use of dental moulds as a cost-effective method for stenting of neovaginal cavity created in patients with MRKH syndrome: a case series. Int Surg J 2026;13:2569-73.