

## Case Report

# Logistical surgical challenges in performing thyroidectomy on huge multinodular goiters in austere limited resource settings: a case report, ideal management protocols, review of literature and pictorial presentation

Ahmed A. Shabhay<sup>1,2\*</sup>, Kondo Chilonga<sup>1,2</sup>, David Msuya<sup>1,2</sup>,  
Zarina Shabhay<sup>3</sup>, Fabian A. Massaga<sup>4</sup>

<sup>1</sup>Department of General Surgery, Kilimanjaro Christian Medical University College (KCMUCo), Moshi, Tanzania

<sup>2</sup>Department of General Surgery, Kilimanjaro Christian Medical Centre (KCMC), Moshi, Tanzania

<sup>3</sup>Muhimbili Orthopedic Institute, Dar es Salaam, Tanzania

<sup>4</sup>Bugando Medical Centre, Mwanza, Tanzania

**Received:** 13 April 2026

**Revised:** 14 May 2026

**Accepted:** 03 June 2026

### \*Correspondence:

Dr. Ahmed A. Shabhay,

E-mail: [ahmedshabio84@gmail.com](mailto:ahmedshabio84@gmail.com)

**Copyright:** © the author(s), publisher and licensee Medip Academy. This is an open-access article distributed under the terms of the Creative Commons Attribution Non-Commercial License, which permits unrestricted non-commercial use, distribution, and reproduction in any medium, provided the original work is properly cited.

## ABSTRACT

Thyroidectomy is a safe procedure when performed by competent well-trained surgeon in ideal settings. However not all centers have settings that adhere to recommended standard preoperative, intraoperative, and postoperative well laid guidelines. Surgeons in such settings must improvise ingenious methods to try to comply with recommended guidelines. Patients in resource limited settings present late with huge benign or malignant multinodular goiters with limited preoperative investigative modalities due to financial constraints. These settings create logistical challenges for the attending surgeons in such settings. Thyroidectomy also carries a high legal ramification potential due to its high complication potential index from its anatomical proximity of potential lethal or life changing complications by iatrogenic injury to adjacent structures such as Recurrent Laryngeal Nerve, parathyroid glands, or the large caliber blood vessels. It is the author's intention to highlight these logistical challenges and not recommend or advocate the practice in such settings to be adopted as the standard of care.

**Keywords:** Total thyroidectomy, Subtotal thyroidectomy, Goiter, Multinodular goiter

## INTRODUCTION

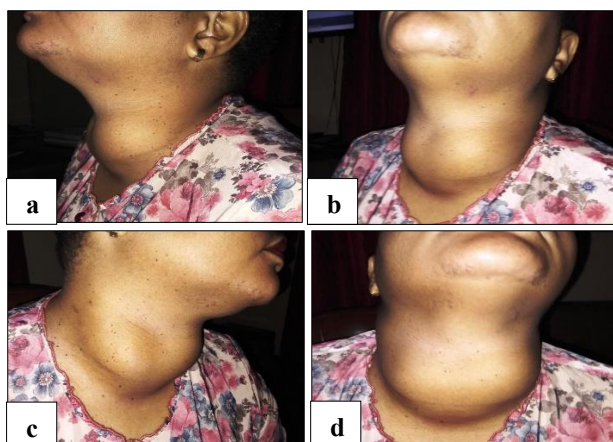Thyroidectomy is considered to be the pinnacle of endocrine surgery as it requires experience, surgical precision, sound judgement, meticulous technique and adequate training to combat and prevent potential lethal complications such as uncontrollable haemorrhage, recurrent laryngeal nerve damage, condemning patients to lifelong thyroxine therapy and parathyroid gland damage.<sup>1,2</sup> Recurrent laryngeal nerve damage leading to reduced voice quality can lead to career ending

consequences to professional speakers and singers, and also frustrations to mothers of small children.<sup>2</sup>

In the early years of the twentieth century thyroidectomy was considered a barbaric procedure due to its associated complications even leading to be banned in France.<sup>3</sup> Herein we present a case of a middle-aged lady who had a multinodular goiter and underwent total thyroidectomy with no post-operative complications, and pictorial presentations of patients who had also undergone total thyroidectomies and thyroid lobectomies.

## CASE REPORT

A 36-year-old female with a history of 6 years of a painless anterior neck swelling attended our center. She had a gradual onset of a slow growing spontaneous painless anterior neck swelling for 6 years but due to fear of potential surgery and complications told to her by her family and friends she avoided medical consultation. She had no history of psychic episodes, sleeplessness episodes, excessive worry nor anxiety. The reason for seeking medical consultation was mainly due to the subjective feeling of compression in her neck and limited head movement in nodding. She had already gotten used in wearing a scuff nearly always to hide her neck swelling due to appearance/cosmesis. She didn't report any episodes of difficulty in breathing, swallowing or changes in voice quality. She weighed 87 kg and was 150 cm in height. She had "normal" intelligence level. She didn't report any episodes of heat or cold intolerance, abnormal gain or loss of weight and had normal menstrual cycles. She is the first member of her family to have such a swelling. On examination she was not pale, not jaundiced, not cyanosed and normal facies. Her blood pressure was 150/90 mmHG, pulse rate 92 beats per minute, respiratory rate 16 cycles per min, oxygen saturation 99% on room air. On local examination there was a 10 by 6 cm non pulsatile, firm, smooth overlying skin surface, non-translucent, same body temperature, smooth edges, moving with swallowing, anterior neck swelling (Figure 1).

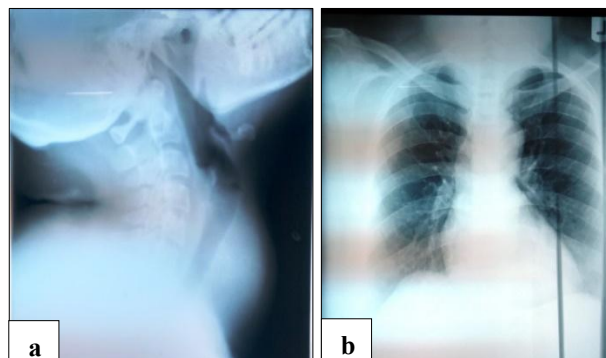


**Figure 1 (a-d): Pre-operative appearance of the patient's neck revealing multi-nodular enlarged thyroid gland. Thyroid gland size grade III.**

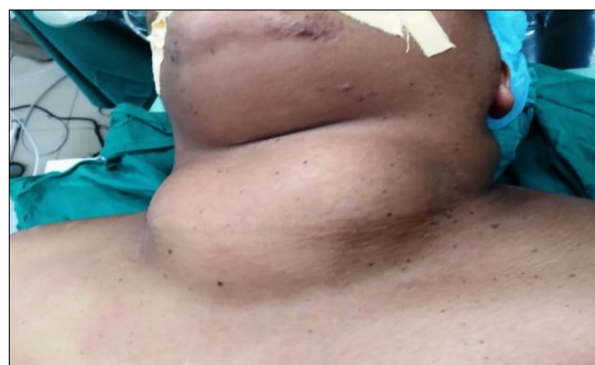Cardiovascular and respiratory systems were normal. Chest X ray did not reveal any retrosternal extension (Figures 2a and b).

Indirect laryngoscopy preoperatively was not performed. Blood work revealed she was in euthyroid state triiodothyronine (T3) - 1.84 ng/ml (0.60-2.10), thyroxine (T4) - 7.6 ng/dl (5.0-13 ng/dl), and thyroid stimulating hormone (TSH) - 1.14 U/l (0.32-5.20). Her haemoglobin level was 12.2 g/dl. She was scheduled for total

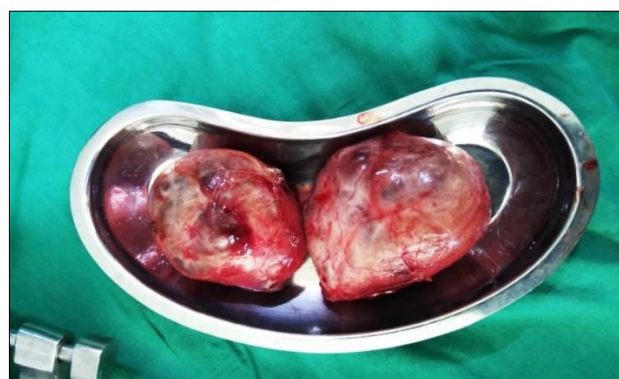thyroidectomy for excision of the bilateral goitrous thyroid lobes. She was taken to theater (Figure 3) and intra-operatively two enlarged thyroid lobes were excised (total thyroidectomy done) (Figure 4).



**Figure 2: (a) Lateral view X-ray, and (b) antero-posterior view X-ray.**



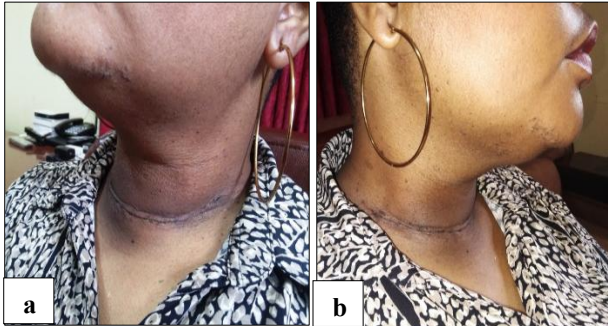**Figure 3: Pre-operative appearance with neck extension prior thyroidectomy. Thyroid gland size grade III.**



**Figure 4: post-operative specimen measuring 80mm by 70 mm and 60 mm by 50 mm in dimension weighing 0.2 kgs and 0.3 kgs respectively (excision of bilateral enlarged thyroid gland lobes, total thyroidectomy done).**

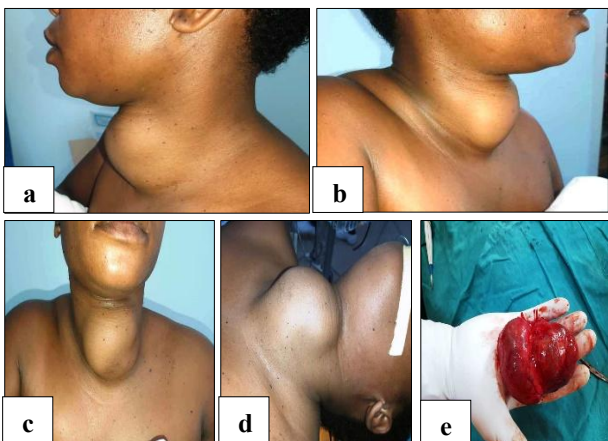
The procedure was uneventful. Day one post-operatively her voice assessment was of normal pitch and the method used in our center to assess and rule out recurrent laryngeal

nerve palsy of the patient is the surgeons and close relatives' opinion on the quality of voice pre-operatively and post-operatively. The patient fared well and two weeks post-operative her wound had healed well (Figures 5a and b).



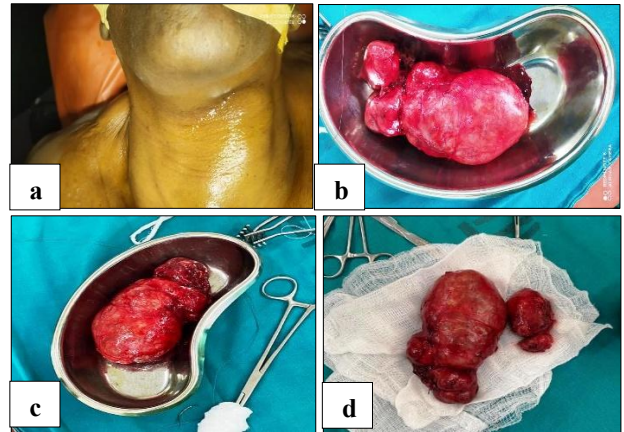
**Figure 5: (a) 2 weeks post-operative incision site and neck appearance front view, and (b) 2 weeks post-operative incision site and neck appearance side view.**

Post-operatively the two thyroid lobes measuring 80 by 70 mm and 60 by 50 mm were subjected to histological studies and revealed multi nodular colloid goiter. Patients' post-operative recovery was uneventful. She was instituted on levothyroxine 50 mcg OD and control serum calcium levels 2 weeks post-operative were normal. Her surgical outpatient clinic was uneventful. Six pictorial cases have also been displayed. The first case (Figures 1-5) is the presented case. Figure 6 was a middle-aged lady who had presented with unilateral left lobe enlargement. She underwent left hemi-thyroidectomy (lobectomy). Her post-operative recovery was uneventful.



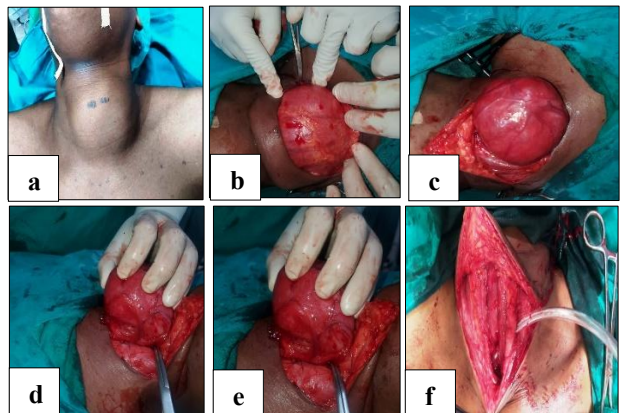
**Figure 6: (a-d) Pre-operative neck appearance of unilateral left thyroid lobe multi-nodular goiter. Thyroid gland size grade III, and (e) post-operative 0.3 kg left thyroid lobe (hemi-thyroidectomy done). Histology revealed multi-nodular colloid goiter.**

Figure 7 was of a fifty-year-old male who presented with bilateral multi-nodulated thyroid lobes and underwent total thyroidectomy. His post-operative recovery was uneventful.



**Figure 7: (a) Pre-operative neck appearance of a 50-years-old male with multi-nodular goiter. Thyroid gland size grade III, and (b-d) post-operative goitrous thyroid gland specimen revealing a huge 0.6 kg multi nodular goiter measuring 120 mm by 70 mm and 60 mm by 50 mm. Histology results revealed multinodular colloid goiter. Total thyroidectomy done.**

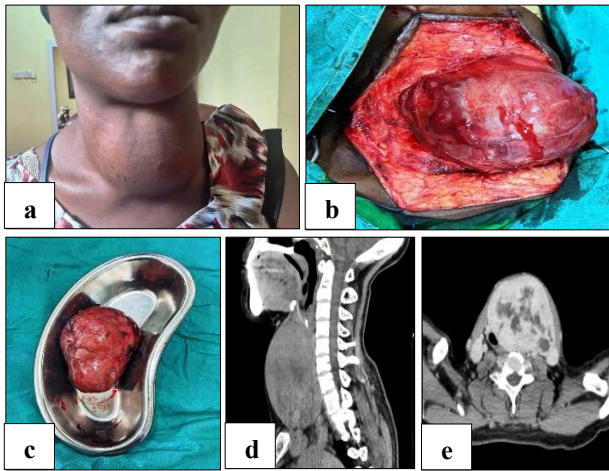
Figure 8 was another middle-aged lady who had unilateral left thyroid lobe enlargement. She underwent left hemi-thyroidectomy, and her post-operative recovery was uneventful.



**Figure 8: (a) "Therapeutic" marks on neck indicating chronicity and seeking of treatment from traditional healers' prior hospital visit. Thyroid gland size grade III, (b) platysma muscle exposed after incision of skin and subcutaneous tissues in a hemi-thyroidectomy of a left goitrous thyroid lobe, (c) exposed left thyroid lobe prior excision, (d and e) exposed left thyroid lobe. Note middle thyroid vein can be vividly seen. Histology revealed multinodular colloid goiter, and (f) insertion of a drain post goitrous thyroid lobe excision.**

Figure 9 was a middle-aged lady who presented in euthyroid state with enlarged left thyroid lobe. Underwent left hemi-thyroidectomy. She was fortunate enough to receive financial aid to transfer her to a center with

computed tomography (CT) scan. Note the extensive right tracheal deviation (Figure 9).



**Figure 9: (a) Enlarged left multi-nodular lobe, (b) exposed left thyroid lobe prior excision, (c) post-operative specimen, (d) 0.4 kg 7 cm by 5 cm for histopathology, and (e) CT scan neck exposing the enlarged left thyroid lobe. Note the tracheal deviation to the right.**

All patients' histopathological post-operative biopsies were multi-nodular colloid goiter. None experienced any transient or permanent hypoparathyroidism or recurrent laryngeal nerve palsy. In all cases there was no need for the sternohyoid and sternothyroid muscles to be divided.

## DISCUSSION

Despite advanced technological modalities in some settings which led to Huscher performing the first endoscopic thyroid lobectomy in 1997, which paved the way for other minimally invasive scarless thyroidectomies such as the cervical and extra-cervical modalities; such as the minimally invasive video-assisted thyroidectomy described by Micolli; bilateral axillo-breast approach (BABA) thyroidectomy developed in 2007 by Choe and Youn et al as a modification of the axillo-bilateral breast approach by Shimazu et al still in some areas of limited resources, this type of surgery is quite a logistical challenge.<sup>4,5</sup> It is impossible to conduct proper preoperative studies, which makes it difficult to comply with the recommendations of international treatment guidelines.<sup>5</sup>

Even to date some regions in the developing world pose a logistic nightmare to the proper performance of the procedure. Most centers do not offer all basic investigations and the availability of hormonal replacement therapy is limited. Thus, the attending surgeons fear to condemn the patients to life-long unavailable drug therapies as is in the case of total thyroidectomy.<sup>6</sup>

These logistic challenges have led to even in some cases local anaesthesia for thyroidectomy be opted contrary to the recommended standard general anaesthesia either due to "high risk patients" whom either a physician or anaesthesiologist, anaesthesia machines, drugs and monitoring devices are unavailable or in remote rural areas where no anaesthesiologist/anaesthetic, high inhibitive cost of running the devices or clinical officer is available to institute general anaesthesia.<sup>2</sup> Aliyu et al in Nigeria reported operating on 59 patients with local anaesthesia due to his center having no functional anaesthesia machine with four non-fatal complications over a period of two years, however this medically medieval practice can be a harrowing and frightening experience to the patient similar to probably what his ancestors faced in the 19th century.<sup>7,2</sup>

It is further noted that in resource limited settings, patients present late with huge multi-nodular goiters once compression symptoms ensue as indication for thyroidectomy due to cosmetic appearance is impracticable in an insured poverty-stricken old lady in developing countries contrary to her counterpart in the Western World.<sup>2</sup> Huge goiters present a surgical challenge even to competent well-trained surgeons and meticulous care is needed to avoid the vital structures while removing the huge goitrous thyroid mass.<sup>1</sup>

Huge goiters of up-to 2 kg (8) and 4.7 kg have been documented to be operated on, with fatality on the latter case due to complications in post-operative care of a tracheostomy in situ.<sup>1</sup> To further add difficulty in the procedure there are certain patient factors which demand more surgical dexterity from the performing surgeon such as obesity, short neck as was the scenario in our case and cervical spondylitis.<sup>3</sup> The outcome of the procedure may also be affected by the performing surgeon who is influenced by several factors such as peer pressure, professional relationship with the consultant, family/marital issues, competence basing on basic surgical training, institution of training, type of personality, personal health habits and health issues.<sup>3</sup>

The success of the surgery is thus dependent almost solely on the surgeon's pre-operative clinical acumen and assessment, intra-operative meticulous skills, and post-operative monitoring of the patient. It has been noted that the surgeon is the most important prognostic factor for potential of complications.<sup>9</sup> However, the attending surgeon should take into consideration the dire life changing complications lies wholly on the patient.<sup>10</sup> This was evident in a reported case by Nada et al reporting mortality two days post-operatively after excision of a 4.7 kg thyroid gland mass due to a mucous plug lodged into the tracheostomy tube due to lack of experience of the attending staff.<sup>11</sup> As much as the surgeon in remote settings would wish to adhere to all standard measures in his practice, it is prudent to appreciate the fact he works in a rather unique disadvantageous austere setting and can thus not "copy-cat" all documented protocols not available to him.<sup>2</sup> The rural surgeon has above all to rely on his

knowledge of anatomy of the thyroid gland and meticulous surgical technique as an essential armament for prevention of surgical complications.<sup>9</sup>

Some surgeons refrain from performing the procedure in fear of potentially fatal complications in settings where arresting or correcting the complications is not possible such as hypocalcemia and hypothyroidism.<sup>12</sup> Thyroidectomy has a high legal lawsuit action potential especially due to the life changing loss of or reduction of voice quality due to recurrent laryngeal nerve damage as observed by Carsuzaa et al.<sup>13</sup> Preoperative and intraoperative modalities employed in advanced centers such as laryngoscope examination serves as an invaluable tool in identifying existing pre-operative damage and dysfunction of the vocal cords, as noted by Echternach (20% his patients had preoperative pathologies in their vocal cords prior surgery) and intraoperative nerve monitoring for identifying and recording recurrent laryngeal nerve vitality, tools which can be considered a luxury in austere remote settings.<sup>14</sup>

To mitigate the challenges, rural surgeons have devised ingenious in expensive modalities to reduce the complication rates in performing thyroidectomy. The use of post-operative drain insertion can serve and save as an invaluable tool in monitoring of on-going haemorrhage and haematoma formation which could lead to fatal airway compromise.<sup>2</sup> Training staff to monitor vitals/signs requiring no/or inexpensive tools such as visual wound inspection, initial danger signs such as deranged respiratory and cardiac rate, non-invasive blood pressure monitoring, temperature, arterial oxygen saturations and Glasgow coma scale as well visible distress signs in the patient such as agitation or anxiety, and difficulty in breathing is another invaluable and inexpensive modality in resource limited settings in the post-operative care for thyroidectomy cases.<sup>15</sup> However, the availability of these inexpensive tools should not be a substitute for meticulous craftsmanship intra-operatively as it also serves as a risk factor for post-operative infection, longer hospital stay, drain blockage and does not prevent life threatening haematoma.<sup>2</sup> However, the clinical/surgical decision on drain placement ultimately rests on the clinical acumen of the attending surgeon as the literature on drain versus no draining is still controversial.<sup>14,16</sup> In settings where diathermy machines are unavailable the use of “Jungle juice” for control of haemorrhage has been adopted by either a mixture of 180mls normal saline, 20mls of xylocaine 2%, 1 ampoule of adrenaline 1:1000 and 1 ampoule of hylase beneath the platysma.<sup>2</sup> The availability of ultrasonic or radiofrequency scalpels to reduce haemorrhage other than traditional haemostatic modalities is not always feasible in all settings.<sup>14</sup>

Despite employment of total thyroidectomy in management of benign thyroid pathologies still being controversial, with most surgeons refraining from performing radical total thyroidectomy due to the potential increased risk of recurrent laryngeal nerve damage and

parathyroid gland damage and resort to subtotal thyroidectomies, total thyroidectomy is still the current preferred treatment option for multinodular goiters.<sup>10,17</sup> In austere settings where there is limited availability of qualified general surgeons competent enough for endocrine surgeries and long waiting lists, with regards to the best modality of thyroidectomy, total thyroidectomy strikes the best balance between a single stage procedure as subtotal thyroidectomy has been shown to be associated with incidences of recurrence of thyroid nodules manifesting years post initial surgery, high malignancy potential of the remnant thyroid tissues with increased technical surgical dexterity required in redo-surgeries due to distorted structural morphology of the gland in relation to vital surrounding structures and financial limitation of uninsured clients.<sup>10,18</sup>

However, it has been noted radical procedures such as total thyroidectomy have catastrophic results when performed by relative junior surgeons in resource limited settings as those seen by our pioneers in thyroid surgery; Kocher, Billroth and Mikulicz in the 19th century.<sup>2</sup> In medieval times, the mortality rate was as high as 40%, which were reduced by the fathers of thyroid surgery, Kocher and Billroth to less than 5%.<sup>14</sup> Such rare catastrophic complications can include rare complications such as complete and complex laceration of the cervical esophagus at 360° resulting into complete transection of the cervical oesophagus with the two esophageal stumps retracting 3 cm far from each other as reported by Mondello et al.<sup>5</sup>

It was Kocher who introduced the extracapsular dissection for thyroidectomy for which he later received the Nobel prize in 1909.<sup>19</sup> However, the procedure in the hands of well-trained endocrine surgeons, it is a safe procedure as suggested by the American Association of Endocrine Surgeons “When possible, thyroidectomy should be performed by a high-volume thyroid surgeon”, with fewer complication rates noted when procedure performed by endocrine surgeon specialists.<sup>10,20</sup> The safety of the procedure depends on the competence of the performing surgeon and has shown to be a safe and efficacious procedure despite its legal risk for the surgeon.

## CONCLUSION

Thyroidectomy in resource limited settings pose clinical and surgical management modalities which hinder the rural surgeon in adhering to recommended standard guidelines. These logistical challenges demand improvisations by the local staff to mitigate the challenges they face. It should however be noted and emphasized that it is not the authors intentions to propagate or advocate that improvised measures taken in limited resource settings be adopted or accepted as a standard of measure rather than to merely highlight the challenges faced by rural remote surgeons in performing the procedure. All potential thyroidectomy cases should be subjected to standard pre-operative and peri-operative routine safety procedures especially benign cases. All efforts should be emphasized

on training of personnel and equipping health centers with proper equipment for standard care.

*Funding: No funding sources*

*Conflict of interest: None declared*

*Ethical approval: Not required*

## REFERENCES

1. Nada A, Mohamed Ahmed A, Vilallonga R, Armengol M, Moustafa I. A giant euthyroid endemic multinodular goiter with no obstructive or compressive symptoms. *Case Rep Med.* 2011;2011:620480.
2. Adwok J. Thyroid II– Thyroidectomy. Nairobi: Surgery in Africa- Monthly Review. 2007. Available at: <https://erepository.uonbi.ac.ke/items/a8b62a70-2f0c-40b8-980e-b83d45ab629a>. Accessed on 03 March 2026.
3. Bothra S, Sabaretnam M, Kannujia A, Chand G, Agarwal G, Mishra SK, et al. Patient, thyroid, and surgeon related factors that make thyroidectomy difficult-cohort study. *Ann Med Surg.* 2022;49:14-8.
4. Chand G, Johri G. Extracervical endoscopic thyroid surgery via bilateral axillo-breast approach (BABA). *J Minim Access Surg.* 2020;16:190-4.
5. Mondello C, Baldino G, Cianci V, Gualniera P, Sapienza D, Asmundo A, et al. Professional liability due to complete esophagus section during thyroidectomy: a rare case report. *Gland Surg.* 2023;12:716-22.
6. Lin YS, Wu HY, Yu MC, Hsu CC, Chao TC. Patient outcomes following surgical management of multinodular goiter: does multinodularity increase the risk of thyroid malignancy? *Medicine (Baltimore).* 2016;95(28).
7. Aliyu S, Ningi A, Rabi M. Thyroidectomy under local anaesthesia in a poor resource health facility in Northeastern Nigeria. *J Surg Surg Res.* 2020;6(1):1-5.
8. Mabewa AA, Njile J, Mushi A, Kabala RB, Ngaa T, Agapiti T, et al. A two kilograms euthyroid goiter in Singida Regional Referral Hospital, Central Tanzania: case report. *Int J Surg Case Rep.* 2020;77:430-3.
9. Dzodic R, Santrac N, Markovic I, Buta M, Goran M. Complications in thyroid surgery. *Evid Based Endocr Surg.* 2018;187:99.
10. Gangappa RB, Kenchannavar MB, Chowdary PB, Patanki AM, Ishwar M. Total thyroidectomy for benign thyroid diseases: what is the price to be paid? *J Clin Diagn Res.* 2016;10(6):PC04-7.
11. Nada A, Mohamed Ahmed A, Vilallonga R, Armengol M, Moustafa I. A giant euthyroid endemic multinodular goiter with no obstructive or compressive symptoms. *Case Rep Med.* 2011;2011:620480.
12. Pereira Pérez F, Calvo Espino P, Sánchez Arteaga A, Muñoz Rodríguez JM, Nges LW, Kemmoe M, et al. Thyroid surgery at a volunteer program in Sub-Saharan Africa. *Cir Esp.* 2016;94(7):404-9.
13. Carsuzaa F, Delbreil A, Chabrillac E. Thyroid surgery, complications and professional liability. *Gland Surg.* 2023;12:1025-7.
14. Stefanou CK, Papathanakos G, Stefanou SK, Tepelenis K, Kitsouli A, Barbouti A, et al. Surgical tips and techniques to avoid complications of thyroid surgery. *Innov Surg Sci.* 2022;7(3-4):115-23.
15. Iliff HA, El-Boghdadly K, Ahmad I, Davis J, Harris A, Khan S, et al. Management of haematoma after thyroid surgery: systematic review and multidisciplinary consensus guidelines. *Anaesthesia.* 2022;77:82-95.
16. Nawaz S, Naeem A, Zeb A. Thyroid surgery: drain versus no drain. *J Postgrad Med Inst.* 2015;29(2):101-4.
17. Padur AA, Kumar N, Guru A, Badagabettu SN, Shanthakumar SR, Virupakshamurthy MB, et al. Safety and Effectiveness of Total Thyroidectomy and Its Comparison with Subtotal Thyroidectomy and Other Thyroid Surgeries: A Systematic Review. *J Thyroid Res.* 2016;2016:7594615.
18. Chalya PL, Rambau P, Mabula JB, Kanumba ES, Giiti G, Chandika AB, et al. Patterns and outcome of surgical management of goitres at Bugando Medical Centre in northwestern Tanzania. *Tanzan J Health Res.* 2011;13(3):242-51.
19. Welbourn RB. Highlights from endocrine surgical history. *World J Surg.* 1996;20(5):603-12.
20. Kim J, Seib CD. Operative management of thyroid disease in older adults. *J Endocr Soc.* 2023;7(7):1-7.

**Cite this article as:** Shabhay AA, Chilonga K, Msuya D, Shabhay Z, Massaga FA. Logistical surgical challenges in performing thyroidectomy on huge multinodular goiters in austere limited resource settings: a case report, ideal management protocols, review of literature and pictorial presentation. *Int Surg J* 2026;13:1217-22.