

Case Report

Aortosternal venous compression along with bovine arch masquerading as internal jugular vein thrombus: a case report

Sourav S. Dutta*, Kalpit K. Sahoo, Shefali Manchanda

Department of General Surgery, Pt. B. D. Sharma PGIMS, Rohtak, Haryana, India

Received: 01 April 2026

Revised: 06 May 2026

Accepted: 20 May 2026

*Correspondence:

Dr. Sourav S. Dutta,

E-mail: prince.dutta54@gmail.com

Copyright: © the author(s), publisher and licensee Medip Academy. This is an open-access article distributed under the terms of the Creative Commons Attribution Non-Commercial License, which permits unrestricted non-commercial use, distribution, and reproduction in any medium, provided the original work is properly cited.

ABSTRACT

We present the case of a 31-year-old male who presented with pain and swelling of the left side of the neck and left upper limb. Initial ultrasonography demonstrated thrombosis of the left internal jugular vein with partial thrombosis of the left subclavian and axillary veins. Subsequent contrast-enhanced computed tomography of the neck and thorax revealed an anatomical variant of the aortic arch with a common origin of the brachiocephalic artery and left common carotid artery (bovine arch), resulting in significant compression of the left brachiocephalic vein between the aortic arch, clavicle, and manubrium sterni. No mediastinal mass or aneurysm was identified. Computed tomography (CT) venography confirmed severe stenosis of the left brachiocephalic vein, establishing the diagnosis of aorto-sternal venous compression after exclusion of other causes. The patient was managed conservatively with limb elevation and anticoagulation therapy, with marked symptomatic improvement on follow-up.

Keywords: Upper limb DVT, Venous thromboembolism, Aortosternal compression, Bovine arch, IJV thrombus

INTRODUCTION

Aorto-sternal venous compression (AVC) syndrome, also known as aorto-sternal compression syndrome, is a rare condition involving the compression of the brachiocephalic vein due to its positioning between the aorta and the sternum. This compression is often asymptomatic but can occasionally cause symptoms such as upper extremity oedema, neck or scalp pulsations, and paraesthesia.¹ While mediastinal masses in the anterior or superior mediastinum may cause extrinsic compression of adjacent vasculature, AVC is ultimately a diagnosis of exclusion. In some cases, AVC arises from tortuous or ectatic great vessels that compress the brachiocephalic vein, particularly in patients with a decreased anterior-posterior chest diameter.²⁻⁴

Etiology

This condition may develop as a result of underlying anatomical abnormalities. One commonly associated

cause is an aberrant right subclavian artery, in which the artery originates abnormally from the left side of the aortic arch and exerts compressive effects on adjacent venous structures.

Additionally, tortuous or ectatic great vessels within the mediastinum-particularly in individuals with a reduced thoracic cavity-can lead to compression of the brachiocephalic vein.¹

Incidence

Aorto-sternal venous compression syndrome is a rare condition, and its incidence is not well established. It was first described in 1989 by Wurtz et al, and subsequent case reports highlight its occurrence mainly in patients with specific anatomical variations, such as an aberrant right subclavian artery. This condition typically involves compression of the left innominate vein between the sternum and the aorta or its branches, which is exacerbated during expiration.⁵

Symptoms

Aorto-sternal compression is frequently asymptomatic because venous obstruction is often compensated by the development of collateral circulation. When symptoms do occur, they are typically related to venous congestion and may include swelling of the upper extremities, particularly the left arm or shoulder. Patients may also experience paraesthesia, such as numbness or tingling in the neck or scalp, as well as visible neck or scalp pulsations resulting from elevated venous pressure. Headaches and orbital pain may be present, occasionally accompanied by visual disturbances such as “squiggly lines.” In some cases, dysphagia can occur if the oesophagus is involved, especially when aberrant vascular anatomy leads to direct compression.^{1,6}

Diagnosis

Diagnosing AVC is difficult because of its rarity and the nonspecific nature of its clinical presentation. Imaging plays a central role in establishing the diagnosis. Computed tomography (CT) or CT angiography is used to evaluate the mediastinum and vascular structures, often during both inspiratory and expiratory phases, to detect dynamic changes in the calibre of the brachiocephalic vein. Venography is frequently utilized as the confirmatory diagnostic modality, as it can clearly demonstrate venous compression and the development of collateral circulation, particularly during expiration, while allowing dynamic assessment of respiratory flow changes. Although not diagnostic on its own, ultrasound may reveal reduced or stagnant venous flow in the internal jugular or brachiocephalic veins, prompting further diagnostic evaluation.^{1,7}

Treatment

Treatment of aorto-sternal compression syndrome, a rare condition involving external compression of the innominate vein, depends on symptom severity. Initial management is usually conservative, with medical therapy such as anticoagulation used in patients with mild symptoms or associated venous thrombosis. Patients with more significant or persistent symptoms may benefit from endovascular intervention, particularly venous stenting, which provides a minimally invasive means of restoring venous flow and relieving symptoms. Open surgical treatment is rarely pursued due to the need for extensive exposure and the higher risk of complications. Overall, endovascular stenting is considered the preferred option for symptomatic cases.¹

Prognosis

The prognosis for patients with AVC is generally favourable, particularly for those managed conservatively. Surgical intervention is rarely needed, and long-term complications are uncommon. However, due to the limited

number of cases reported, the long-term outcomes remain poorly understood.¹

CASE REPORT

A 31-year-old male patient presented to the casualty of PGIMS Rohtak with ongoing pain and swelling of neck (left side) and left upper limb. There was no significant past medical or surgical history neither the patient was a drug abuser. The patient denied any loss of consciousness, ringing noise in ears, or slurred speech, or dysphagia. Physical examination demonstrated swelling over left side of neck which was extending to the entire left upper limb along with tenderness on palpation of neck and left upper limb. A focused upper extremity examination revealed intact sensations, normal reflexes bilaterally, normal muscle tone and motor strength 5/5. Laboratory investigations showed an international normalized ratio (INR) of 0.7 and an activated partial thromboplastin time (aPTT) of 20 seconds. Complete blood count (CBC), vitamin B12, and thyroid stimulating hormone (TSH) levels were all within normal limits (Table 1).

Table 1: Laboratory values.

Investigation	Findings	Reference values
INR	0.7	0.8-1.3
aPTT (secs)	20	25-35
Complete blood count (CBC)	Within normal limits	
Vitamin B12 (pg/ml)	680	200-900
Thyroid-stimulating hormone (TSH) (mIU/ml)	2.5	0.5-5

Laboratory investigations showed slightly low values of INR and aPTT. Rest blood work-up was within normal limits.

Due to ongoing neck and upper limb pain, Ultrasonography of neck and upper limb was advised. Initial scan revealed thrombosis of left internal jugular vein (IJV) along with partial thrombosis of left subclavian and left axillary veins (Figure 1). However, left branchial vein showed normal flow on colour Doppler (Figure 2).

Ultrasonography of the neck showing non-compressible left internal jugular vein with intraluminal echogenic thrombus, consistent with venous thrombosis.

Colour Doppler imaging of the neck showing absent colour Doppler flow in left IJV, consistent with venous thrombosis.

CECT of the neck and thorax was ordered and revealed an anatomical variant of aortic arch i.e., brachiocephalic artery (BCA) shows a common origin with the left common carotid artery (CCA), also known as bovine arch,

which was seen compressing over left brachiocephalic vein (BCV). Also, left brachiocephalic vein appeared compressed between left CCA and medial head of left clavicle and manubrium sterni.

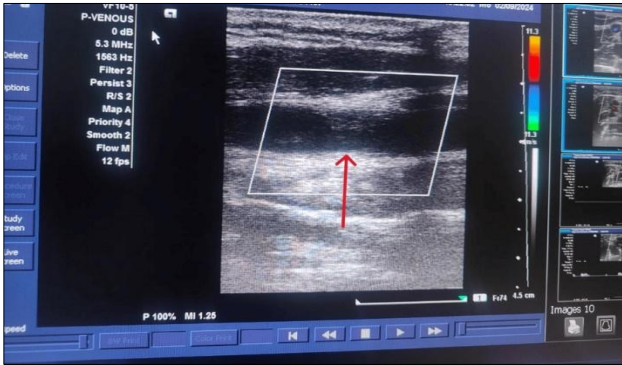

Figure 1: Ultrasound imaging showing thrombus in left internal jugular vein (red arrow).

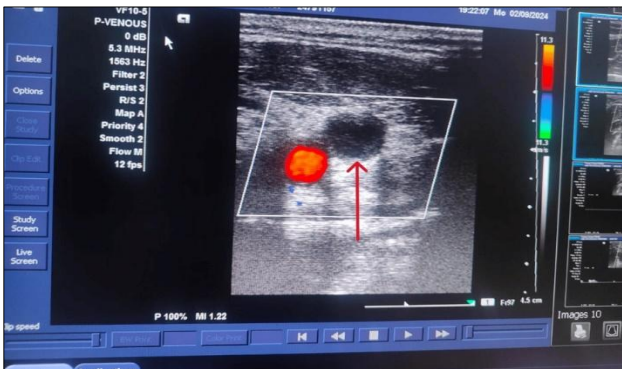


Figure 2: Colour Doppler imaging showing absent flow in left internal jugular vein (red arrow).

The anteroposterior (AP) distance between left CCA and medial head of left clavicle was 7.7 mm and the AP distance between manubrium sterni and bovine arch was 10 mm. However, CT thorax ruled out any mediastinal mass or aortic arch aneurysm. As the CT thorax examination was performed during the expiratory phase, hence findings of brachiocephalic venous compression could be noted. Also, inspiratory phase of CT thorax was performed to compare the findings (Figure 3). Findings were suspicious for aorto-venous compression hence CT venography was advised.

The AP distance between the manubrium sterni and bovine arch was just 10 mm. the ap distance between the left common carotid artery (CCA) and medial head of clavicle was 7.7 mm.

CT venogram demonstrated severe stenosis of the left brachiocephalic vein. Previous exclusion of other aforementioned etiologies of venous compression, and the venographic findings mentioned above, led to a diagnosis of aorto-venous compression in the setting of anatomical variant of aortic arch, known as bovine arch (Figure 4).

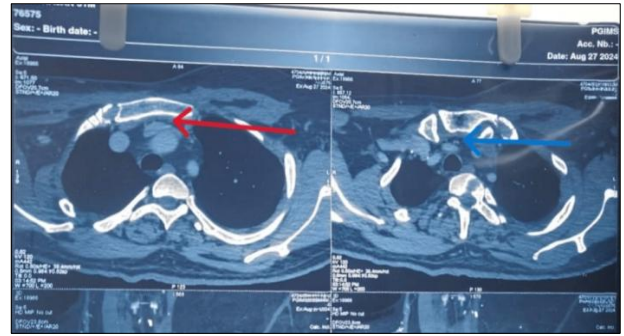


Figure 3: CECT (axial sections) showing aorto-sternal narrowing (red arrow) and narrowing of space between medial end of clavicle and left common carotid artery (blue arrow).

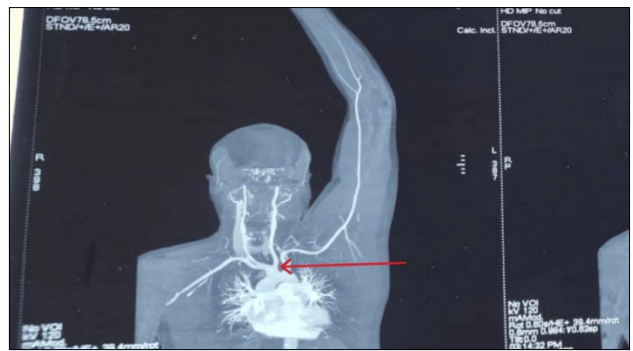

Figure 4: CT venogram showing bovine arch (red arrow).

The above film shows the common origin of left common carotid artery from innominate (brachiocephalic) artery, which is known as the Bovine Arch.

Management included conservative options such as left arm elevation, and for the thrombus of great veins, injection LMWH was given initially for a period of 5 days followed by oral tablets of direct thrombin inhibitors (Dabigatran 150 mg twice a day). Based on the last follow up visit, the patient is doing well with decreased severity of symptoms.

DISCUSSION

AVC syndrome is a rare vascular condition caused by extrinsic compression of the brachiocephalic vein between the sternum and the aorta or its branches. Due to its nonspecific clinical features, it is frequently misdiagnosed as primary venous thrombosis, particularly when patients present with unilateral neck and upper limb swelling.¹ In this case, the initial diagnosis of internal jugular vein thrombosis on ultrasonography was revised after contrast-enhanced CT revealed a bovine aortic arch causing significant compression of the left brachiocephalic vein. Anatomical variants of the aortic arch, including bovine arch and aberrant right subclavian artery, have been previously reported as predisposing factors for aorto-

sternal venous compression by reducing the available mediastinal space.

The typical branching of the aortic arch sequentially involves the brachiocephalic trunk, the left common carotid artery, and the left subclavian artery. A bovine arch variant—where the brachiocephalic trunk and the left common carotid artery share a common origin—drastically alters the normal spatial geometry of the superior mediastinum.⁸ This structural variation predisposes the thin-walled brachiocephalic vein to compression between the anomalous arterial trunks and the rigid manubrium sterni, particularly during expiration when the retrosternal clearance is physiologically narrowed (our CT findings demonstrated critical reductions to 10 mm and 7.7 mm).¹ The expiratory-phase CT images were instrumental in demonstrating venous narrowing, emphasizing the importance of dynamic imaging in suspected cases. CT venography remains the confirmatory imaging modality, as it accurately demonstrates the site and severity of venous stenosis while excluding alternative causes such as mediastinal mass or aneurysm.

Awareness of this entity is crucial, as venous stasis from extrinsic compression may lead to secondary thrombosis, potentially resulting in inappropriate long-term anticoagulation if the underlying cause is not identified.⁷ Treatment strategies are individualized. Conservative management is often sufficient in mildly symptomatic patients, while endovascular stenting has been reported to provide rapid symptom relief in refractory cases.

However, the application of endovascular stents in the context of extrinsic anatomical compression remains highly debated. While self-expanding stents are routinely utilized for intrinsic central venous stenoses with high procedural success rates, their use in aorto-sternal venous compression is heavily discouraged by several authors due to the mechanical shear stress exerted by respiratory volume changes within the confined retrosternal space.^{1,9} Continual extrinsic compression from the pulsatile anomalous aorta and rigid sternum significantly increases the risk of stent fracture and distal migration.^{1,9} Operative decompression of the thoracic inlet, including manubrioplasty, is reserved as a radical approach for severe, refractory cases but carries considerable morbidity.¹

The favourable response to conservative treatment in our patient supports its role as first-line therapy. This case highlights the importance of recognizing aorto-sternal venous compression as a differential diagnosis in patients with unilateral cervicothoracic venous congestion and underscores the critical role of CT imaging in establishing the diagnosis.

CONCLUSION

AVC syndrome should be considered in patients presenting with unexplained unilateral neck and upper limb swelling, especially in the absence of conventional risk factors for venous thrombosis. Anatomical variants of the aortic arch can contribute to clinically significant venous compression and may be overlooked on initial evaluation. Dynamic CT imaging and CT venography are crucial for establishing the diagnosis. Timely recognition allows appropriate management and avoids unnecessary or prolonged anticoagulation.

Funding: No funding sources

Conflict of interest: None declared

Ethical approval: Not required

REFERENCES

- Giglio V, Badar Z, Bhogadi Y, Van Adel B, Yip G. Aortosternal Venous Compression: A Review of Two Cases. *Case Rep Med.* 2022;2022:4591024.
- Hernandez JA, Walser EM, Swischuk LE. Aortosternal venous compression in patients with aberrant right subclavian arteries. *Am J Roentgenol.* 2005;184:1434-6.
- Itkin M, Kraus MJ, Trerotola SO. Extrinsic compression of the left innominate vein in hemodialysis patients. *J Vasc Int Radiol.* 2004;15:51-6.
- Moes CAF, MacDonald C, Mawson JB. Left innominate vein compression by a brachiocephalic artery anomaly. *Pediatr Cardiol.* 1995;16:291-3.
- Wurtz A, Quandalle P, Lemaitre L, Robert Y. Innominate vein compression syndrome. *Br J Surg.* 1989;76(6):575-6.
- Weerakkody Y, Deng F. Aortosternal venous compression. 2026. Available at: <https://radiopaedia.org/articles/aortosternal-venous-compression>. Accessed on 12 February 2026.
- Arslan Ü, Jalalzai I. A Narrative Review of Biomarkers and Imaging in the Diagnosis of Acute Aortic Syndrome. *Diagnostics.* 2025;14:183.
- Rotundu A, Nedelcu AH, Tepordei RT, Moraru MC, Chiran DA, Oancea A, et al. Medical-Surgical Implications of Branching Variation of Human Aortic Arch Known as Bovine Aortic Arch (BAA). *J Pers Med.* 2024;14(7):678.
- Eguchi D, Honma K. Results of Stenting for Central Venous Occlusions and Stenoses in the Hemodialysis Patients. *Ann Vasc Dis.* 2020;13:235-9.

Cite this article as: Dutta SS, Sahoo KK, Manchanda S. Aortosternal venous compression along with bovine arch masquerading as internal jugular vein thrombus: a case report. *Int Surg J* 2026;13:1084-7.