

Case Report

Left is right and right is left: a case report of gastric antral perforation in situs inversus totalis

Ayesha Reshma V. M. K.*, Shyamsundar R., Arulkumaran M., Srinithi S.

Department of General Surgery, GMKMCH, Salem, Tamil Nadu, India

Received: 22 March 2026

Accepted: 20 April 2026

*Correspondence:

Dr. Ayesha Reshma V. M. K.,

E-mail: ayeshareshma.vmk@gmail.com

Copyright: © the author(s), publisher and licensee Medip Academy. This is an open-access article distributed under the terms of the Creative Commons Attribution Non-Commercial License, which permits unrestricted non-commercial use, distribution, and reproduction in any medium, provided the original work is properly cited.

ABSTRACT

Situs inversus totalis (SIT) is a rare congenital anomaly in which thoracoabdominal organs are arranged in a complete mirror-image pattern. Although SIT does not increase the risk of gastrointestinal disease, it can obscure the diagnosis of acute abdominal emergencies because symptoms may appear on the opposite side. Gastric perforation in SIT is extremely uncommon, with very few cases reported worldwide. A 20-year-old male presented with two days of worsening abdominal pain and vomiting. Examination showed diffuse tenderness, guarding, rigidity, and liver dullness on the left side. A chest X-ray performed earlier revealed dextrocardia. At our centre, abdominal X-ray showed free air under the left hemidiaphragm. Computed tomography (CT) confirmed situs inversus totalis with complete visceral transposition and identified a right-sided gastric antral perforation. Emergency laparotomy revealed mirror-image anatomy of abdominal organs and great vessels. A 0.5×0.5 cm antral perforation near the lesser curvature on the right was repaired with primary closure and an omental patch. Recovery was uneventful, and the patient was discharged on postoperative day 10. SIT may delay diagnosis due to reversed symptom localisation. Early radiological evaluation, especially CT, is crucial for identifying organ transposition and guiding safe operative planning. Despite the inverted anatomy, standard surgical principles for small perforations remain effective. Gastric perforation in SIT is rare and easily missed. Prompt imaging, careful intraoperative orientation, and awareness of reversed anatomy enable safe surgical management and good outcomes.

Keywords: Visceral transposition, Mirror-image anatomy, Acute peritonitis, Emergency laparotomy, Omental patch repair, Abdominal situs anomaly

INTRODUCTION

Situs inversus totalis (SIT) is a rare congenital condition in which the thoracic and abdominal organs are arranged in a complete right-to-left mirror-image orientation.¹ Its estimated prevalence ranges between 1 in 10,000 and 1 in 50,000 individuals, with a slight male predominance.^{2,3} Although SIT itself does not predispose patients to specific gastrointestinal diseases, its recognition is critical, as the reversed anatomy can mask typical symptoms and lead to diagnostic delays in acute abdominal conditions.⁴

Acute surgical presentations in SIT have been described, including perforated appendicitis, colonic perforation, duodenal ulcer perforation, and gastric malignancy.⁴⁻⁸

However, gastric perforation in SIT remains exceptionally uncommon, with only two previously documented reports worldwide. To the best of our knowledge, this case represents the third reported instance of gastric antral perforation occurring in a patient with SIT, and the first such presentation reported from India.^{9,10}

The rarity of this condition, combined with its atypical clinical presentation, highlights the importance of maintaining a high index of suspicion when evaluating abdominal pain in patients with reversed organ anatomy.

This case report has been prepared in accordance with the SCARE 2025 checklist.¹¹

CASE REPORT

Patient information

A 20-year-old male, thin-built and moderately nourished, came to the emergency department with abdominal pain and vomiting for the past two days. The pain started suddenly, kept getting worse, was dull and constant, and did not radiate.

He had vomited four times a day, usually after food. The vomitus was non-bilious and contained food particles.

He had no major past medical or surgical history. He drank alcohol occasionally (about 150 ml per binge; last intake 3 days ago) and did not smoke. There was no relevant family history.

He first visited a private hospital, where a chest X-ray done for his symptoms incidentally showed dextrocardia, after which he was referred to our centre.

Clinical findings

On examination, he was alert, oriented, and afebrile. There was no pallor, icterus, cyanosis, clubbing, lymphadenopathy, or pedal oedema. His apical impulse was felt on the right side, and normal heart sounds were heard. Both lungs had good air entry. CNS examination was normal.

His abdomen was not distended and moved normally with breathing. There was diffuse tenderness, guarding, and rigidity. No organomegaly was noted, and bowel sounds were present. Liver dullness was heard on the left side. Per rectal examination showed normal tone with faecal staining.

Investigations and diagnosis

Initial blood investigations revealed leucocytosis (TC – $15,300/\text{mm}^3$) with a normal haemoglobin level (14.2 g/dl) and platelet count ($2.69 \text{ lakhs}/\text{mm}^3$). Renal and liver function tests, serum electrolytes, and viral markers were within normal limits.

Chest X-ray revealed dextrocardia, raising suspicion of a positional anomaly. An erect abdominal X-ray showed free air under the left hemidiaphragm, indicative of hollow viscus perforation (Figure 1).

Subsequent CT abdomen confirmed the diagnosis of situs inversus totalis, with the liver and other abdominal organs mirrored in position. The scan also revealed a gastric antral perforation on the right side (Figure 2).

The combination of free air, abdominal rigidity, and reversed organ placement confirmed a diagnosis of gastric antral perforation in situs inversus totalis.

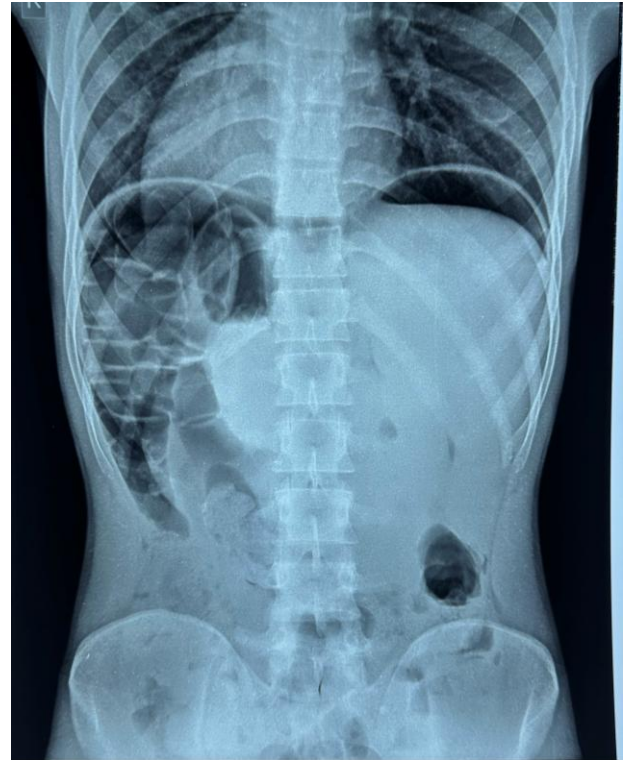


Figure 1: Erect abdominal X-ray demonstrating dextrocardia (yellow arrow) and free subdiaphragmatic air under the left hemidiaphragm (orange arrow), consistent with a hollow viscus perforation.

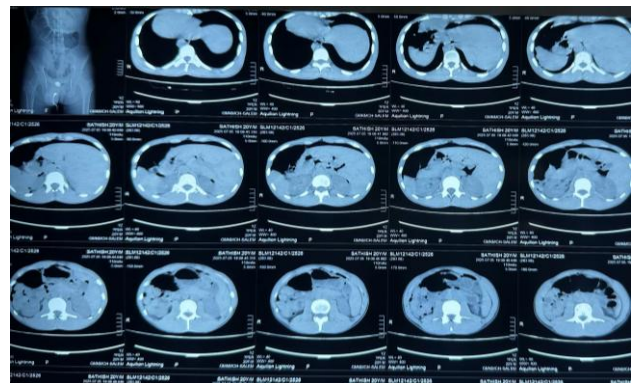


Figure 2: CT abdomen showing mirrored organ positions spleen on right, liver on left.

Intervention

The patient was taken up for emergency laparotomy under general anaesthesia. Intraoperatively, situs inversus totalis was confirmed. The spleen and sigmoid colon were found on the right side (Figure 4), while the caecum with the appendix was located on the left (Figure 5). The liver and gallbladder were positioned on the left, consistent with complete mirror-image anatomy. Great vessels were also reversed (aorta on right, IVC on left). A $0.5 \times 0.5 \text{ cm}$ gastric antral perforation was found on the right near the lesser

curvature (Figure 3). Remaining organs were found healthy.

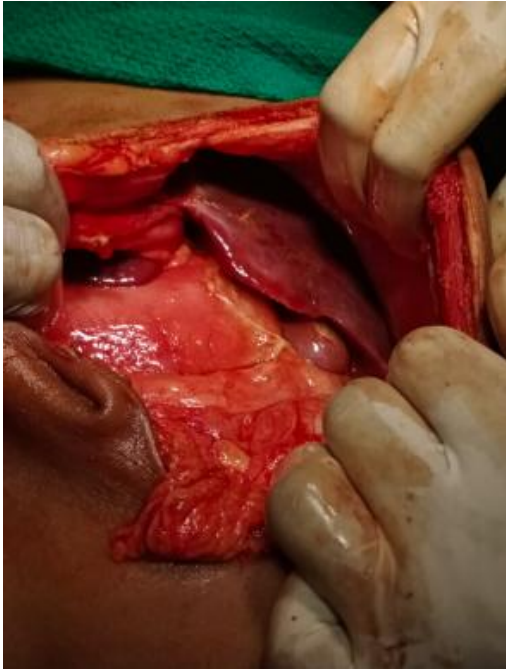

Figure 3: Intraoperative image showing mirror-image transposition of abdominal organs in situs inversus totalis. The liver and gallbladder are located on the left side, while the spleen is seen on the right. A gastric antral perforation is visualized near the lesser curvature, which is also positioned on the right side.

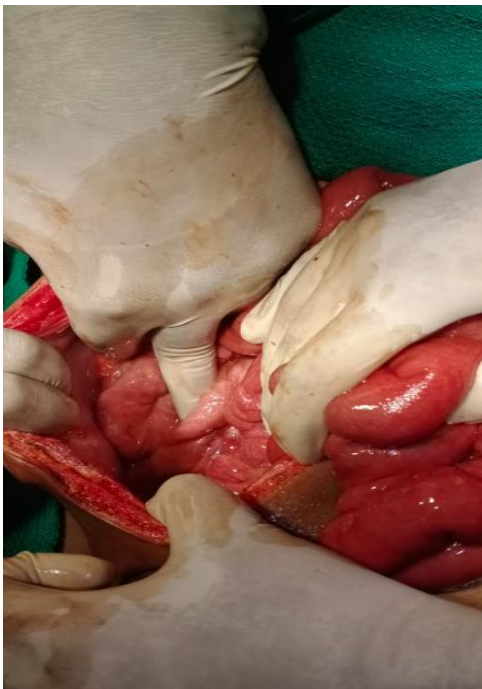

Figure 4: Intraoperative image showing transposition of the sigmoid colon to the right side, consistent with mirror-image anatomy in situs inversus totalis.

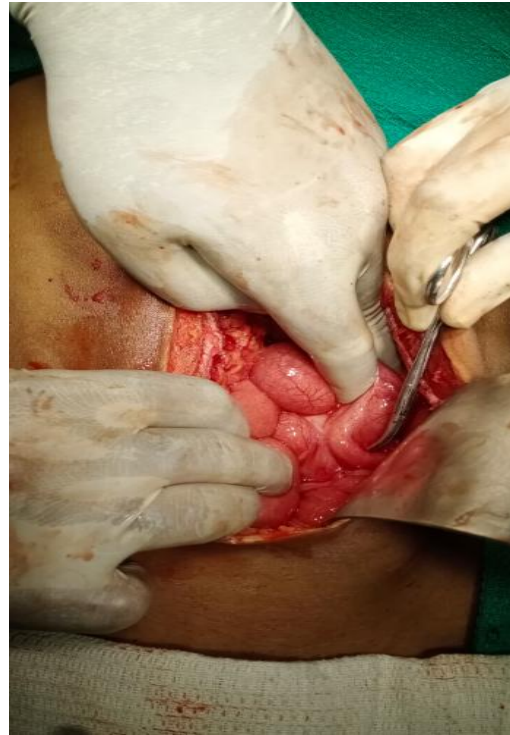

Figure 5: Intraoperative image showing the caecum with appendix located on the left side.

Surgical management was primary closure of the perforation with a live omental patch and thorough peritoneal lavage. No deviation from the surgical plan was required.

Postoperative course

The postoperative period was uneventful. The patient recovered well and was discharged at 10th postoperative day with advice for regular follow-up. At his two-week review, he was well and had no complaints. He was also counselled about his anatomical variation and the importance of informing healthcare providers of his situs inversus status in future medical or surgical encounters.

DISCUSSION

Perforation peritonitis is one of the most common surgical emergencies in India, with peptic perforation being its leading cause.¹² However, the occurrence of perforation peritonitis in a patient with SIT is exceptionally rare. SIT is often diagnosed incidentally, as most individuals remain asymptomatic throughout life. In our case, the patient first underwent a chest X-ray at a private hospital, where dextrocardia was incidentally detected, prompting further evaluation.

Because SIT involves complete mirror-image transposition of thoracoabdominal organs, clinical presentations may not follow typical anatomical patterns. This can cause significant diagnostic confusion, particularly in emergency abdominal conditions. Our

patient presented with acute abdominal pain and vomiting, but the clinical findings including liver dullness on the left side, right-sided cardiac apex, and an unusual location of peritonitis signs necessitated careful evaluation. Similar diagnostic challenges have been reported in other acute gastrointestinal emergencies and conditions occurring in SIT.⁴⁻⁸

Radiological imaging plays an important role in recognizing SIT and helping surgeons plan the operation. Lee et al suggest that when a patient is found to have congenital heart disease or when organs appear in unusual positions, clinicians should evaluate for situs anomalies using a approach starting with a chest X-ray followed by a CT scan.¹³ This aligned with our evaluation. The chest X-ray showed dextrocardia, prompting further imaging. The CT scan then confirmed complete organ reversal, with the liver on the left and the spleen on the right, and also demonstrated free intraperitoneal air and a right-sided antral perforation, consistent with the patient's mirror-image anatomy. Similar CT findings in gastric perforation with SIT have been reported by Ouédraogo et al, showing that CT is very reliable for identifying both the organ positions and the site of perforation in these rare cases.⁹

Although approximately 60% of individuals with SIT may have other gastrointestinal malformations, such as rotational anomalies or biliary atresia, our patient had no associated congenital anomalies, consistent with reports from Biswajit et al and Ouédraogo et al.^{9,13,14} Importantly, like many SIT patients, he was entirely unaware of his congenital condition until the onset of peritonitis.

Intraoperative findings confirmed complete mirror-image anatomy, including reversal of the liver, spleen, caecum, appendix, sigmoid colon, and major vessels (aorta on the right and IVC on the left). Despite these anatomical variations, the surgical principles remained unchanged. A 0.5×0.5 cm anterior antral perforation was identified on the right near the lesser curvature. As established in literature, perforations <1 cm are best managed with primary closure reinforced by an omental patch.^{15,16} Our management followed this standard approach, similar to the technique described in SIT cases by Ahmed et al.¹⁰

The postoperative course in our patient was uneventful, and recovery occurred within the expected timeframe. This supports existing observations that SIT does not adversely influence prognosis, provided that diagnosis is timely and operative orientation is handled with care.

CONCLUSION

Gastric antral perforation in a patient with situs inversus totalis is very rare and can be difficult to diagnose because the symptoms appear on the opposite side of the body. This case shows the need to think about anatomical variations when the clinical picture does not fit the usual pattern. Early imaging with X-ray and CT is very useful to confirm the diagnosis and plan surgery safely.

Although the organs are reversed, surgery can be performed safely by paying close attention to the inverted anatomy. Standard surgical repair works well for small perforations when they are recognised early. Overall, this case highlights the importance of prompt imaging, careful planning, and educating patients with SIT about their condition so they can receive timely care in future emergencies.

Funding: No funding sources

Conflict of interest: None declared

Ethical approval: Not required

REFERENCES

1. Peeters H, Devriendt K. Human laterality disorders. *Eur J Med Genet.* 2006;49(5):349-62.
2. Budhiraja S, Singh G, Miglani HP, Mitra SK. Neonatal intestinal obstruction with isolated levocardia. *J Pediatr Surg.* 2000;35(7):1115-6.
3. Huang SM, Yao CC, Tsai TP, Hsu GW. Acute appendicitis in situs inversus totalis. *J Am Coll Surg.* 2008;207(6):954.
4. Martin VJ, Parinding IT. An unusual perforated appendicitis in total situs inversus in Indonesia: a case report. *New Ropanasuri J Surg.* 2022;7(1):17-9.
5. Elfanagely O, Elfanagely Y, Pratt A. A rare anatomical variation complicating a diffuse abdominal pain presentation: a case report of colonic perforation in situs inversus totalis. *Int J Surg Case Rep.* 2021;87:106456.
6. Tayeb M, Khan FM, Rauf F. Situs inversus totalis with perforated duodenal ulcer: a case report. *J Med Case Rep.* 2011;5:279.
7. Gandhi DM, Warty PP, Pinto AC, Shetty SV. Perforated duodenal ulcer with dextrocardia and situs inversus. *J Postgrad Med.* 1986;32(1):45-6.
8. Suh BJ. A case of gastric cancer with situs inversus totalis. *Case Rep Oncol.* 2017;10:130-5.
9. Ouédraogo NLMM, Sanogo K, Traoré MS, Traoré SS, Simporé J. A case report of management of gastric perforation in situs inversus totalis in a 45-year-old adult. *Int J Surg Case Rep.* 2020;74:69-72.
10. Ahmed Z, Khan SA, Chhabra S, Yadav R, Kumar N, Vij V, et al. Our experience with surgery in situs inversus: open peptic perforation repair and laparoscopic cholecystectomy in 1 patient and 3 patients respectively. *Int J Surg Case Rep.* 2016;29:34-8.
11. Kerwan A, Al-Jabir A, Mathew G, Sohrabi C, Rashid R, Franchi T, et al. Revised Surgical CAse REport (SCARE) guideline: An update for the age of Artificial Intelligence. *Premier J Sci.* 2025;10:100079.
12. Bali RS, Sharma A, Gupta A, Goyal R, Jindal V. Perforation peritonitis and the developing world. *ISRN Surg.* 2014;2014:105492.
13. Lee SE, Kim HY, Jung SE, Lee SC, Park KW, Kim WK. Situs anomalies and gastrointestinal abnormalities. *J Pediatr Surg.* 2006;41(7):1237-42.

14. Biswajit B, Sabuj B, Partha C, Arnab M, Ramkrishna M. Perforated duodenal ulcer in a case of situs inversus totalis in an elderly woman: a rare presentation. *J Case Rep.* 2016;6(2):218-21.
15. Cellan-Jones CJ. A rapid method of treatment in perforated duodenal ulcer. *Br Med J.* 1929;1(3571):1076-77.
16. Opreanu RC. Omental (Graham) Patch: Overview, Perioperative Care, Technique. *Medscape.* 2015.

Available at: <http://emedicine.medscape.com/article/1892935-overview>. Accessed on 12 January 2026.

Cite this article as: Ayesha RVMK, Shyamsundar R, Arulkumaran M, Srinithi S. Left is right and right is left: a case report of gastric antral perforation in situs inversus totalis. *Int Surg J* 2026;13:877-81.