

Case Report

Severe nasal cutaneous necrosis following an arthropod bite: surgical management and reconstruction

Lahmidi Hajar*, Wannassy Mohamed Amine, Habla Marouane, Elyoussoufi Ahlam, Karti Sara, Diouri Mounia

Department of Plastic and Reconstructive Surgery, University Hospital Center (CHU), Casablanca, Morocco

Received: 04 January 2026

Accepted: 11 February 2026

***Correspondence:**

Dr. Lahmidi Hajar,

E-mail: dr.lahmidi@gmail.com

Copyright: © the author(s), publisher and licensee Medip Academy. This is an open-access article distributed under the terms of the Creative Commons Attribution Non-Commercial License, which permits unrestricted non-commercial use, distribution, and reproduction in any medium, provided the original work is properly cited.

ABSTRACT

Arthropod bites are usually benign; however, severe cutaneous necrosis is a rare complication that may result in significant tissue loss, particularly when the face is involved. We report the case of a 19-year-old woman who developed progressive nasal cutaneous necrosis following a presumed arthropod bite. Despite initial medical treatment, the lesion worsened, requiring surgical necrosectomy followed by delayed split-thickness skin graft reconstruction. Histopathological examination supported the diagnosis of a severe arthropod bite reaction. Early recognition of necrotic arthropod bite reactions and timely surgical management are essential to prevent extensive tissue loss. Appropriate reconstructive strategies can achieve satisfactory functional and aesthetic outcomes, even in rare facial localizations.

Keywords: Arthropod bite, Cutaneous necrosis, Nasal reconstruction, Skin graft, Case report

INTRODUCTION

Arthropod bites are frequently encountered in clinical practice and usually present as mild, self-limited inflammatory skin reactions.¹ These reactions are mediated by toxic and immunologic mechanisms related to salivary or venom components injected during the bite.²

In rare cases, arthropod bites may lead to severe local complications such as ulceration and cutaneous necrosis.³ Necrotic arachnidism represents one of the most severe manifestations of arthropod envenomation and is associated with vascular injury, inflammatory mediator release, and tissue ischemia.^{4,5}

Facial involvement is uncommon and may result in diagnostic confusion, as early lesions can mimic infectious, inflammatory, or neoplastic conditions.⁶ When the nasal region is affected, even limited tissue loss may cause major functional and aesthetic impairment due to the complexity of nasal subunits.⁷ We report a rare case of

severe nasal cutaneous necrosis following a presumed arthropod bite and describe its surgical management.

CASE REPORT

A 19-year-old woman with no significant past medical history presented with a progressive lesion of the nasal dorsum (Figure 1).

The evolution began six weeks earlier with the sudden appearance of a painful erythematous papule, presumed to be secondary to an arthropod bite. The lesion was exacerbated by local manipulation and mechanical irritation from eyeglass wear. By the third day, purulent discharge appeared, followed by progressive ulceration and necrosis despite topical and systemic medical treatments (Figure 2).

Dermatological evaluation prompted a skin biopsy, initially suggestive of a vascular or granulomatous process. Given the unfavorable evolution,

histopathological reassessment demonstrated necrotizing dermatitis with vascular involvement and a dense

eosinophilic inflammatory infiltrate, findings consistent with a severe arthropod bite reaction.

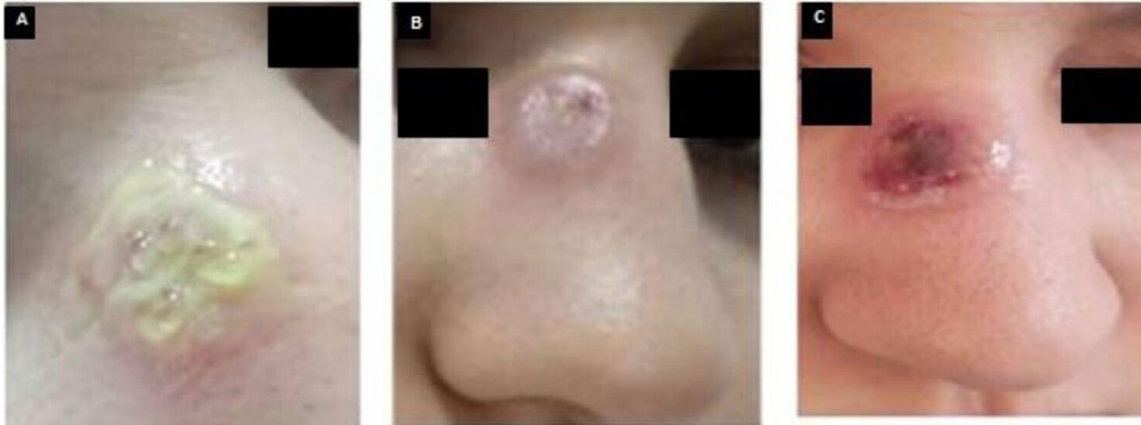


Figure 1: (A) Initial presentation of erythematous and necrotic lesion of the nasal dorsum. Early inflammatory lesion with central necrosis on the nasal dorsum, (B) progression to a well-demarcated necrotic lesion and (C) established nasal cutaneous necrosis prior to surgical management.

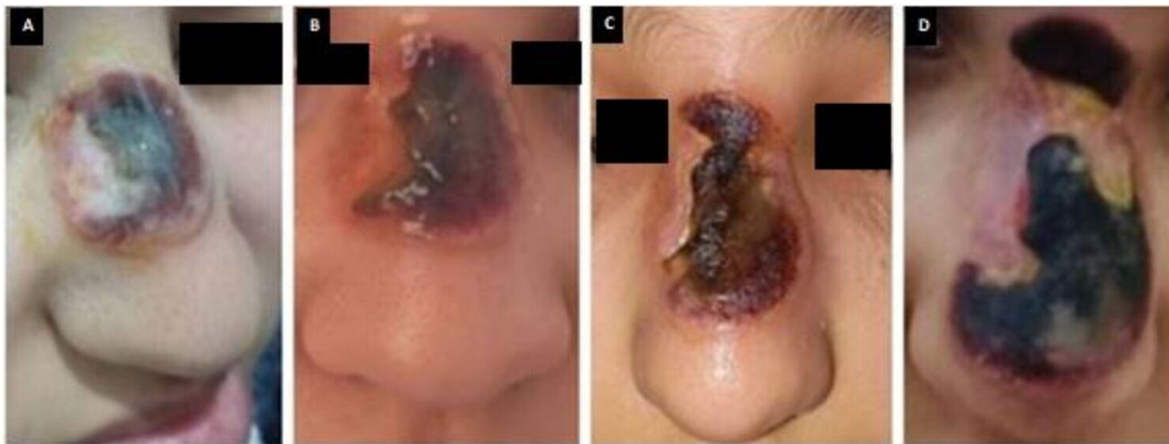

Figure 2: Progressive ulceration and necrosis despite medical treatment. (A) Initial necrotic lesion with central discoloration on the nasal dorsum, (B) extension of necrosis with well-demarcated eschar formation, (C) advanced necrosis involving the nasal dorsum and tip and (D) extensive full-thickness nasal cutaneous necrosis prior to surgical intervention.

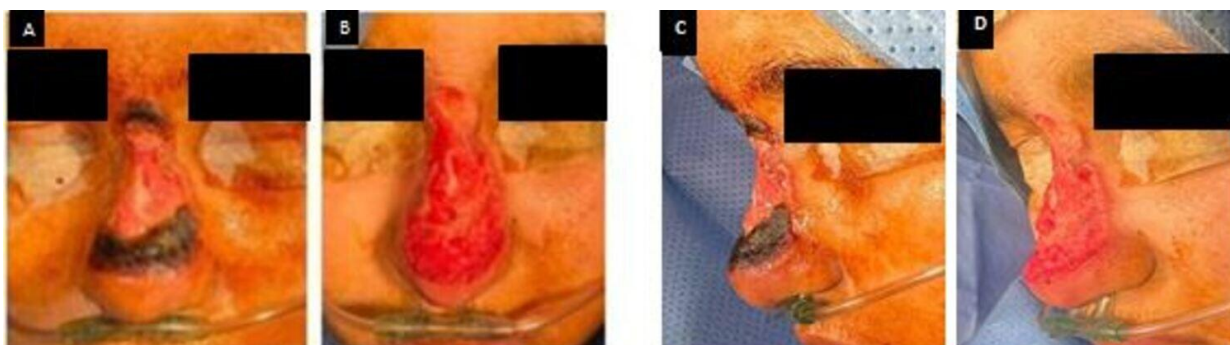


Figure 3: Post-necrosectomy defect involving multiple nasal subunits. (A) Frontal view showing the nasal defect following surgical debridement, (B) frontal immediate postoperative appearance with granulation tissue formation, (C) lateral view of the nasal defect highlighting tissue loss and wound margins and (D) lateral postoperative view demonstrating progressive healing and contour restoration.

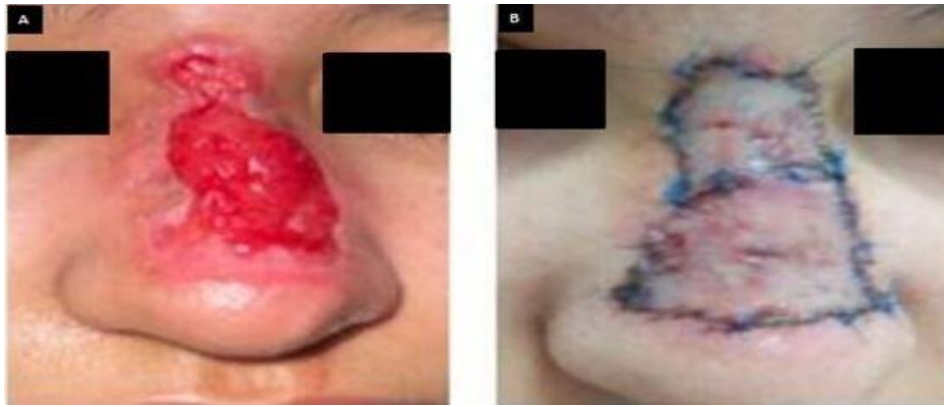


Figure 4: Early postoperative views after skin graft. (A) Frontal view after complete surgical debridement of necrotic nasal tissue, demonstrating a well-vascularized wound bed. (B) Postoperative appearance at day 5 after skin grafting, showing satisfactory graft take and early healing.

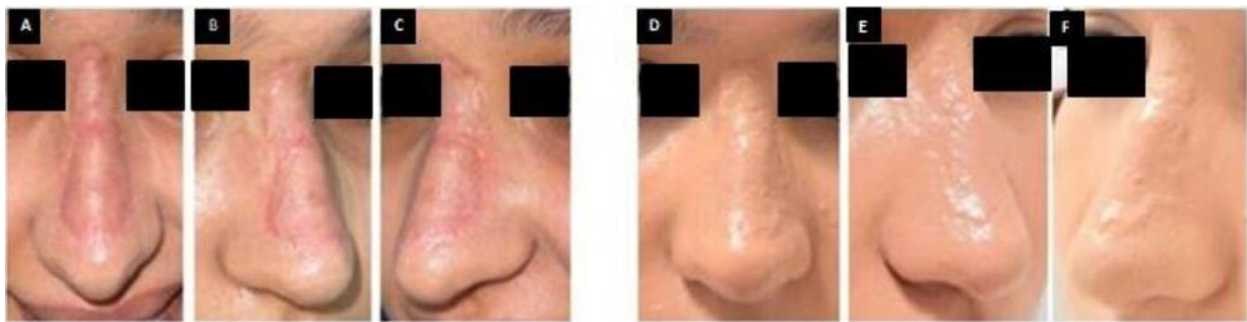


Figure 5: Long-term postoperative outcome after nasal reconstruction. (A–C) Frontal and oblique views at 4 months postoperatively, showing satisfactory contour, skin integration, and progressive scar maturation. (D–F) Frontal and lateral views at 8 months postoperatively, demonstrating stable nasal contour, acceptable symmetry, and favorable cosmetic result.

Surgical management

Due to progressive necrosis and failure of conservative treatment, surgical management was indicated. Complete surgical necrosectomy was performed with excision of all devitalized tissue until healthy margins were obtained, resulting in a defect involving three nasal aesthetic subunits. Meticulous hemostasis was achieved, and the wound was managed with antiseptic greasy dressings (Figure 3).

After resolution of inflammation and adequate wound bed preparation, delayed reconstruction was performed using a split-thickness skin graft harvested from the retroauricular area, achieving complete graft take (Figure 4). The donor site healed uneventfully with minimal morbidity.

Postoperative follow-up

The patient was followed regularly on an outpatient basis. Postoperative care included local wound management, scar monitoring, and pressotherapy to optimize scar maturation and prevent hypertrophic scarring. At follow-up, the graft remained stable, the scar was supple and non-retractile, and no recurrence or inflammatory signs were

observed. Functional and aesthetic outcomes were satisfactory, with good patient satisfaction (Figure 5). The retroauricular donor site showed good healing with satisfactory cosmetic results.

DISCUSSION

Severe cutaneous necrosis following arthropod bites is uncommon and represents a diagnostic challenge due to nonspecific early clinical features.⁸ While most arthropod bite reactions remain benign, necrotic lesions may develop secondary to venom-induced cytotoxicity, immune-mediated hypersensitivity, and microvascular thrombosis.⁹

Necrotic arachnidism, particularly associated with *Loxosceles* species, is the most frequently reported cause of extensive cutaneous necrosis following arthropod exposure.¹⁰ Facial involvement is rare but carries significant functional and aesthetic implications, especially in the nasal region, where soft tissue reserves are limited.¹¹

Once necrosis is established, conservative treatment is insufficient, and surgical excision of devitalized tissue becomes mandatory. Reconstruction should be

individualized according to defect characteristics. Skin grafting remains a reliable option for superficial defects with an adequately vascularized bed.¹² In the present case, staged surgical management allowed satisfactory healing and acceptable aesthetic results.

CONCLUSION

Although arthropod bites are usually benign, clinicians should be aware of their potential to cause severe necrotic complications. Early diagnosis, histopathological confirmation, and timely surgical intervention are essential to limit tissue loss and achieve satisfactory reconstructive outcomes.

Funding: No funding sources

Conflict of interest: None declared

Ethical approval: Not required

REFERENCES

1. Herness J, Snyder MJ, Newman RS. Arthropod bites and stings. *Am Fam Physician*. 2022;106(2):137–47.
2. Isbister GK, Gray MR. Necrotic arachnidism. *Clin Dermatol*. 2004;22(3):213–21.
3. Vetter RS, Bush SP. The diagnosis of arthropod envenomation. *Am J Trop Med Hyg*. 2002;67(6):636–41.
4. Requena L, Yus ES. Arthropod bite reactions. *Semin Diagn Pathol*. 2017;34(3):295–309.
5. Swanson DL, Vetter RS. Loxoscelism. *Clin Infect Dis*. 2005;41(8):1103–13.
6. Bologna JL, Schaffer JV, Cerroni L. *Dermatology*. 4th ed. Elsevier; 2018.
7. Peckruhn M, Elsner P, Tittelbach J. Eosinophilic dermatoses. *J Dtsch Dermatol Ges*. 2019;17(10):1039–51.
8. Atiyeh BS, Costagliola M, Hayek SN. Surgical management of necrotic skin lesions. *Ann Plast Surg*. 2017;78(2):234–41.
9. Orgill DP, Blanco C. Reconstruction after tissue loss. *Plast Reconstr Surg*. 2019;143(3 Suppl):120S–32S.
10. Burget GC, Menick FJ. Aesthetic reconstruction of the nose. *Plast Reconstr Surg*. 1995;95(3):593–602.
11. Tan E, Mortimer N, Salmon P. Full-thickness skin grafts for surgical defects of the nasal ala. *Br J Dermatol*. 2014;170(5):1106–13.
12. Mazzone L, Schiestl C. Management of septic skin necroses. *Eur J Pediatr Surg*. 2013;23(5):349–58.

Cite this article as: Hajar L, Amine WM, Marouane H, Ahlam E, Sara K, Mounia D. Severe nasal cutaneous necrosis following an arthropod bite: surgical management and reconstruction. *Int Surg J* 2026;13:391-4.