

Case Report

Testicular gangrene complicating strangulated groin hernia in an adult

Olaogun Julius Gbenga^{1*}, Adegun Patrick Temi¹, Omotayo John Adetunji²,
Areo Peter Olufemi¹, Dada Samuel Ayokunle³

¹Department of Surgery, Ekiti State University, Ado-Ekiti, Ekiti State, Nigeria

²Department of Anatomic Pathology, Ekiti State University, Ado-Ekiti, Ekiti State, Nigeria

³Department of Medicine, Ekiti State University, Ado-Ekiti, Ekiti State, Nigeria

Received: 18 February 2017

Accepted: 29 March 2017

*Correspondence:

Dr. Olaogun Julius Gbenga,

E-mail: olaogunjulius@yahoo.com

Copyright: © the author(s), publisher and licensee Medip Academy. This is an open-access article distributed under the terms of the Creative Commons Attribution Non-Commercial License, which permits unrestricted non-commercial use, distribution, and reproduction in any medium, provided the original work is properly cited.

ABSTRACT

Testicular infarction/gangrene is most commonly secondary to testicular torsion. Testicular infarction complicating a strangulated inguinal hernia has been well documented in pediatric literature but found to be rare in adults as it has only been reported in only 2 cases and none of which required orchidectomy for treatment. We report a rare case of strangulated inguinoscrotal hernia with testicular gangrene following a delayed presentation in a 25 year old boy with neglected groin hernia. The patient had orchidectomy in addition to primary bowel resection and anastomosis.

Keywords: Bowel strangulation, Complicated groin hernia, Testicular gangrene

INTRODUCTION

Repair of groin hernias is the most commonly performed surgery by general surgeons worldwide.¹ Approximately 75% of all abdominal wall hernias are seen in the groin and about 20 million inguinal herniorrhaphies are performed worldwide every year.^{2,3}

Common complications of groin hernia include irreducibility, bowel obstruction and strangulation when there is negligence and delayed elective repair. Studies have shown a high incidence of these hernia accidents with attendant morbidities and mortalities due to late presentation.^{4,5} However, bowel strangulation is the most dreaded life threatening complication requiring an emergency surgical intervention and the incidence may be up to 5%.⁶ A rare complication of groin hernia in adult is testicular gangrene. Here, we report a case of strangulated inguinoscrotal hernia complicated by testicular gangrene.

CASE REPORT

A 25 year old boy was admitted with irreducible and painful right inguinoscrotal swelling of 2 days duration. He has had a reducible right inguinoscrotal swelling 6 year prior to this time. There was associated colicky central abdominal pain, constipation and 4 episodes of bilious vomiting. There was no preceding history of testicular pain.

Physical examination revealed an acutely ill-looking patient in painful distress with low grade fever (37.9⁰C) and dehydration. The pulse was 108 beats per minute and blood pressure was 120/70mmHg. Abdominal examination revealed a minimally distended abdomen and a huge right inguinoscrotal mass with shiny overlying skin. There was differential warmth over the mass which was tender and irreducible. The right testis could not be evaluated separately from the mass. Per rectum

examination showed empty rectum. A diagnosis of strangulated right inguinoscrotal hernia was made.

The patient was resuscitated and subsequently had right groin exploration after 2 hours of admission. Intraoperative findings revealed 200mls of brownish fluid within the hernia sac, gangrenous ileal segment about 36cm long and 15cm proximal to ileo-caecal junction and testicular gangrene (Figure 1 and 2).

A midline laparotomy incision was later made and resection of the gangrenous ileal segment with primary anastomosis was performed. Hernia repair by nylon darn technique and right orchidectomy was performed.

Postoperative period was uneventful and patient was discharged home on the 7th day of admission.

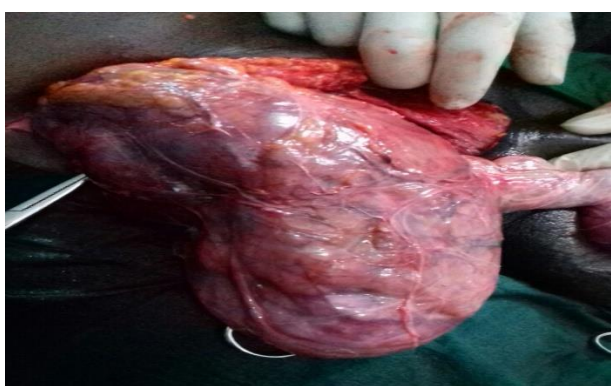

Figure 1: Huge hernia containing strangulated ileum.

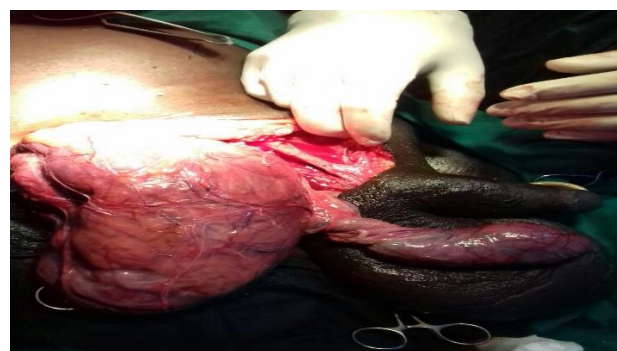


Figure 2: Strangulated right inguinoscrotal hernia with testicular gangrene.

DISCUSSION

Complications arising from groin hernias are still common in our setting. Quite a number of patients still present late and would have experienced one or more symptoms before they consider coming to the hospital perhaps because of fear of surgery, ignorance and financial constraint.⁷

Testicular infarction/gangrene is most commonly secondary to testicular torsion. The latter is a surgical

emergency commonly encountered in adolescents. The diagnosis of this acute condition is mostly clinical but could be confirmed with Doppler ultrasound which is the diagnostic imaging of choice.

Testicular infarction following a strangulated inguinal hernia is a grievous sequelae which is rare in adults. Although, it has been well documented in pediatric literature and this may occur in up to 30% of boys with incarcerated hernias.^{8,9} It is usually as a result of compression and compromise of the vascular supply within the inguinal canal leading to ischemia, infarction and gangrene. In the literature, only 2 adult cases were demonstrated to have testicular compromise due to large obstructed inguinal hernias and both had manual reduction of the hernias with resultant good blood flow to the testicles. None of the patients required orchidectomy.^{10,11} The diagnosis of testicular gangrene may be obscured when this occurs secondary to a complicated hernia as reported in the index case with huge and tender inguinoscrotal swelling who also did not have the benefit of Doppler ultrasound to assess the testicle. The testicular symptoms, as experienced in this case, were most likely masked or overshadowed by features of bowel obstruction and gangrene.

The mechanism of arterial compression in huge obstructed hernia with or without strangulation is most likely analogous to torsion and the time to reduction of the hernia and return of blood flow should be less than 6 hours to prevent permanent ischemia. The testis of the patient in this case could not be salvaged as a result of delayed presentation and he subsequently had orchidectomy in addition to resection of the gangrenous ileal segment and primary anastomosis.

CONCLUSION

In conclusion, testicular infarction, though rare, is a likelihood complication of strangulated inguinoscrotal hernia in adult. With this borne in mind, attempts should always be made to routinely inspect the testis of the affected side intraoperatively most especially where prior ultrasonography is not feasible in order to avoid leaving non-viable gangrenous testis behind.

Funding: No funding sources

Conflict of interest: None declared

Ethical approval: Not required

REFERENCES

1. Kingsworth A, Bennet DH. Hernias, umbilicus: abdominal wall. In: Russell RCG, Williams NS, Bulstrode CJK, eds. Bailey and Love short practice of surgery 23rd ed. London: Arnold; 2000:1149.
2. Garba ES. The pattern of adult external abdominal hernias in Zaria. Nig J Surg Res. 2000;2:12-5.
3. Menakuru SR, Philip T, Ravindranath N, Fisher PW. Outcome of inguinal hernia repair at two rural

- hospitals in northern Scotland. *Surgeon.* 2006;4:343-5.
4. Adesunkanmi AR, Agbakwuru EA, Badmus TA. Obstructed abdominal hernia at the Wesley Guild Hospital, Nigeria. *East Afr Med J.* 2000;77:31-3.
 5. Mbah N. Morbidity and mortality associated with inguinal hernia in Northwestern Nigeria. *West Afr J Med.* 2007;26:288-92.
 6. Uppot RN, Gheyi VK, Gupta R, Gould SW. Intestinal perforation from blunt trauma to inguinal hernia. *Am J Roentgenol.* 2000;174:1538
 7. Eubanks S. Hernias. In: Sabiston DC, ed. *Textbook of surgery, the biological basis of modern surgical practice.* 15th ed. Philadelphia: WB Saunders; 1997:1224-5.
 8. Zamakhshary M, To T, Guan J, Langer JC. Risk of incarceration of inguinal hernia among infants and young children awaiting elective surgery. *CMAJ.* 2008;179:1001-5.
 9. Waseem M, Pinkert H, Devas G. Testicular infarction becoming apparent after hernia reduction. *J Emerg Med.* 2010;38:460-2.
 10. Desai Y, Tollefson B, Mills L, Galli R. Testicular ischemia resulting from an inguinal hernia. *J Emerg Med.* 2012;43(5):e299-301.
 11. Eutermoser M, Nordenholz K. Testicular Compromise due to Inguinal Hernia. *West J Emerg Med.* 2012;13(1):131-2.

Cite this article as: Olaogun JG, Adegun PT, Omotayo JA, Areo PO, Dada SA. Testicular gangrene complicating strangulated groin hernia in an adult. *Int Surg J* 2017;4:1777-9.