

Original Research Article

The use of botulinum toxin in children with chronic constipation

Almoutaz A. Eltayeb^{1*}, Nagla H. Ibrahim², Seham M. Moeen³, Hala M. Imam⁴

¹Department of Pediatric surgery, Assiut University Children Hospital, Assiut, Egypt

²Department of Pediatric, Assiut University Children Hospital, Assiut, Egypt

³Department of Anaesthesiology, Assiut University Hospital, Assiut, Egypt

⁴Department of Gastroenterology Unit, General Medicine Department, Assiut University Hospital, Assiut, Egypt

Received: 15 February 2017

Revised: 28 February 2017

Accepted: 29 March 2017

*Correspondence:

Dr. Almoutaz A. Eltayeb,

E-mail: almoutazeltayeb@hotmail.com

Copyright: © the author(s), publisher and licensee Medip Academy. This is an open-access article distributed under the terms of the Creative Commons Attribution Non-Commercial License, which permits unrestricted non-commercial use, distribution, and reproduction in any medium, provided the original work is properly cited.

ABSTRACT

Background: Conventional therapy of childhood constipation was based on dietary manipulation, stool softeners and oral laxatives. Although these forms of medications are successful in the majority of cases, still small subgroup of patients may fail to respond to this treatment. The aim of this study was to evaluate the role of botulinum toxin in relieving the symptoms of those patients.

Methods: This study was conducted on 20 cases with chronic constipation that fail to respond to conventional medical treatment. Cases under went any previous surgical maneuver will be excluded from study. Anal dilatation was started by Higar dilators then small self-retaining anal retractors were introduced and four injections were made into the four quadrants of the anal canal and rectum at the level of IAS (internal anal sphincter).

Results: twenty cases were included (14 males and 6 females) with age ranged from 8 months to 6 years. The botulinum injection per patients ranged from 1 to 2 injections. The response rate to this treatment was excellent in 6 cases and good in 12 cases and poor in 2 cases. No systemic or local complications occurred in any patients.

Conclusions: botulinum toxin injection could be safe and effective treatment of chronic constipation in infants and children.

Keywords: Botulinum toxin, Chronic constipation, Internal anal sphincter

INTRODUCTION

Anorectal disorders are very common in children and has been estimated that constipation is the chief complaint in 3-5% of all visits to pediatricians.¹ Conventional therapy of childhood constipation was based on dietary manipulation, stool softeners and oral laxatives.² Although these forms of medications are successful in the majority of cases, still small subgroup of patients may fail to respond to this treatment.³ Hurst proposed that one of the possible pathogenic mechanisms of idiopathic constipation might be the failure of the internal sphincter to relax rather than an anal spasm.⁴ The aim of this study

is to evaluate the role of botulinum toxin in management of those patients.

METHODS

This pilot study was conducted on 20 cases with chronic constipation that fail to respond to conventional medical treatment and presented to pediatric surgery unit at Assiut university children hospital from January 2014 to December 2016. Cases under went previous surgical maneuver (myectomy), had anorectal anomalies or learning difficulties were excluded from study. The evaluating parameters included number of bowel

movement, number of fecal impaction or soiling per week and consistency of stool. All patient's parents or guardians were consented to participate in this study. Pre-injection digital rectal examination, gastrografen enema, rectal biopsy and anorectal manometry were done to all patients. Cleaning of the rectum was obtained by phosphate enema the night before botulinum injection which was performed under general anesthesia.

High resolution anorectal manometry (HRARM)

All patients were subjected to HRARM without sedation both before and after Botox injection. HRARM was performed by means of solid state 12 Fr high resolution catheter contains 8 pressure sensors separated by 8.0mm apart (Uni-sensor) and has a rectal balloon at its tip. The system is plotting the pressure changes as high resolution color topography and as pressure wave tracing as well. The software was produced by Medical Measurement System (MMS), Enschede, Netherlands.

All patients were placed in left lateral position with hip flexed in 90 degree. The probe was introduced through the anal verge and the sensors were located at anal verge and the balloon was also at the rectum. Once the catheter at place, the sensors were maintained stationary for the whole of the study. After letting the pressures waves to stabilize, anal pressure was recorded during rest and the average of 3 measurements was considered. Children were asked to squeeze, bear down, and cough to measure anal pressure during these situations. Recto-anal inhibitory reflex was tested by 50ml air balloon inflation. RAIR was considered normal if >20% relaxation was noted with balloon inflation.

Anesthetic technique

All children were received oral midazolam premedication (0.3mg/kg). Induction of anesthesia was carried out using 8% sevoflurane in 100% oxygen through a face mask and the children were not given muscle relaxant. At the end of procedure, anesthetic agents were discontinued and replaced with 100% oxygen. The children were discharged from the operating room to the recovery room, when they were vitally stable, patent airway without any manipulation, and oxygen saturation more than 95% of oxygen in 3L/min flow by face mask.

Injection technique

Botox (*C. botulinum* Toxin Type A, Allergan, Pharmaceuticals, Westport Co. Mayo, Ireland) was suspended in 5 ml of sterile saline to a final concentration of 20 U/ml with a total dose of 5 U/Kg. Then anal dilatation was started by Higar dilators and small anal retractors were used to visualize the anal canal and lower rectum. The internal anal sphincter (IAS) was injected in four quadrants at the level of the dentate line.

The patients were discharged on the same day of injection and followed up monthly thereafter. During the follow up period all the evaluating parameters were recorded. The treatment response rate was scored as; (excellent: patient is passing every day without laxatives, good: patient is passing every other day without laxatives and poor: the patient is passing every three or four days with laxatives).

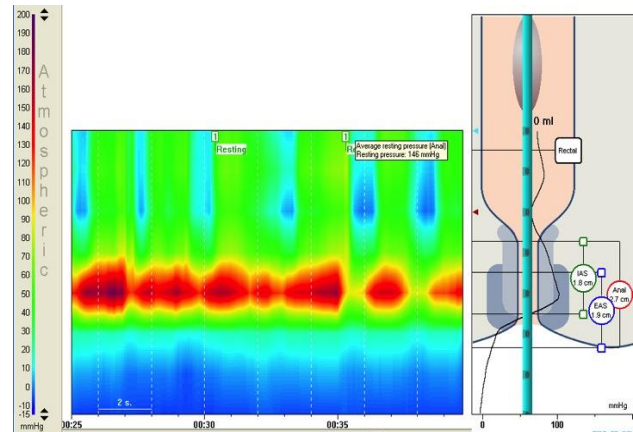


Figure 1: pre injection resting anal canal pressure.

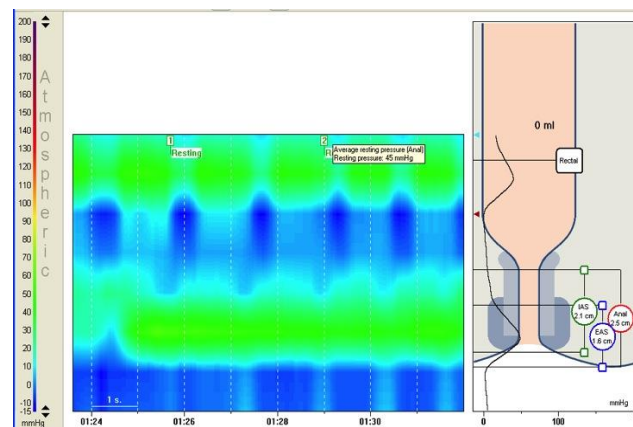


Figure 2: post injection resting anal canal pressure.

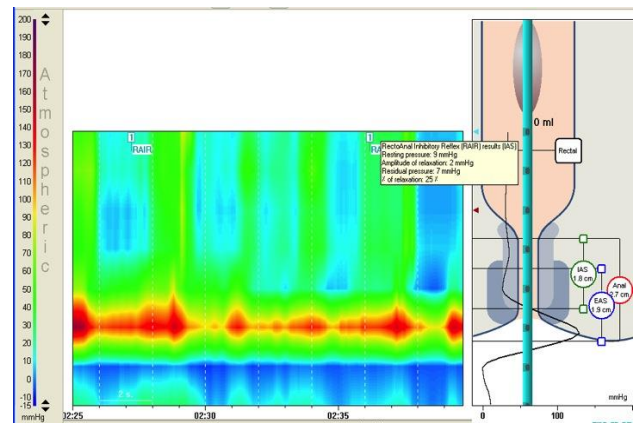


Figure 3: pre injection recto-anal inhibitory reflex.

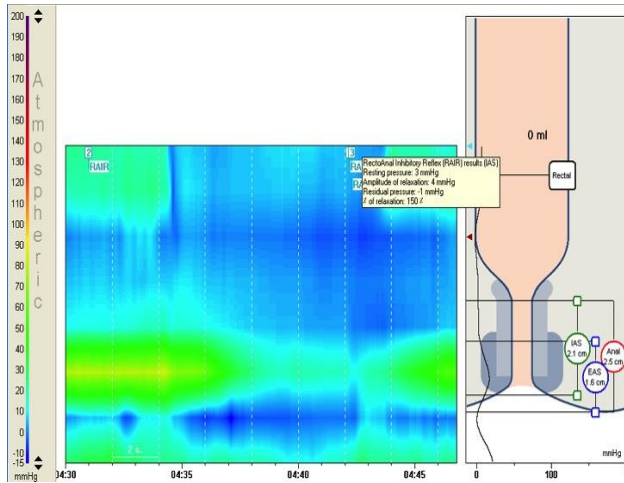


Figure 4: post injection recto-anal inhibitory reflex.

RESULTS

Twenty cases (14 males and 6 females) were included in this study with age ranged from 8 months to 6 years. Prior to botulinum injection bowel movements ranged from once every three days to once every week with a history of passage of hard stool and fecal impaction in 8 cases. Both pre and post injection manometric findings are shown in Figures 1-4. The average pre-injection basal anal resting pressure ranged from (40-150 mmHg) (Figure 1).

The treatment response as shown in Figure 5 was excellent in 6 cases and good in 12 cases and poor in 2 cases that needed another injection after 3 weeks to relief their symptoms and both were passing every three days with laxatives but without enema. This treatment response continued from 3 to 6 months (duration of follow up). There was transient soiling in 4 cases; 3 of them were for 1 week and the fourth lasted for 2 week. All resolved spontaneously after that period. No post injection significant pain, fecal impaction, systemic or local side effects occurred in any patients.

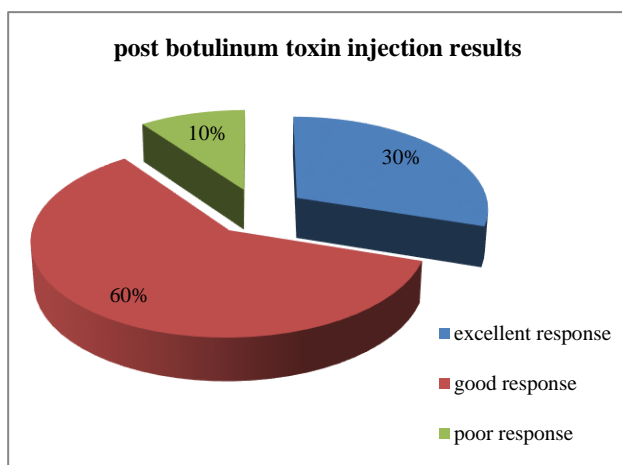


Figure 5: treatment results in the twenty patients.

DISCUSSION

The pathogenesis and pathophysiology of IAS achalasia is still not understood, both intramuscular innervation abnormalities and defective innervation of the neuromuscular junction are believed to be responsible for anal motor dysfunction.⁵ Nitrergic nerve depletion, cholinergic hyperplasia, and abnormal peptidergic innervation have been reported.⁶ Also it has been suggested that there may be an absence of purinergic inhibitory neurons in the distal rectal myenteric plexus of these patients, preventing reflex inhibition of the internal sphincter after cholinergic stimulation in response to rectal distention.⁷

This dysfunction of the IAS could be the cause of chronic constipation either by elevated IAS resting pressure or incomplete RAIR, leading to difficult and painful defecation, fecal soiling, abdominal cramping and distension, and associated behavioral and social consequences in many children.⁸

All cases in this series had ganglion cell in their rectal biopsy, raised resting anal pressure and prolonged threshold for rectal sensation. Only 6 cases have done post injection manometry where all of them showed significant decrease in IAS resting pressure (ranged from 30-100 mmHg) (Figure 2). This is in accordance with the findings of Rodriguez and Flores.⁹ The conventional treatment of IAS dysfunction has involved either forceful anal dilatation or surgical disruption of the IAS via myotomy or myectomy which had reportedly with normalization of the IAS and improvement in constipation.¹⁰⁻¹³ However, while division of the sphincter is an effective method, it risks permanent weakening of the IAS with potential long-term consequences.¹⁴ In contrast, botox has rarely been associated with the development of long-term incontinence.¹⁵

The mechanism of action of *Clostridium botulinum* toxin has been studied extensively. It is a potent bacterial neurotoxin that acts on the neuromuscular junction to block the release of acetylcholine from pre-synaptic cholinergic nerves.^{16,17} This effect is dose-dependent and requires 4 to 6 months to wear off. Botulinum toxin has been used successfully in both adults and children to treat hypertonicity and spasticity of the skeletal and smooth muscles.^{18,19} In patients with esophageal achalasia; a condition associated with esophageal dysmotility, hypertonicity and impaired relaxation of the lower esophageal sphincter (LES), endoscopically delivered injection of this neurotoxin to the LES results in symptomatic relief in 60% of patients for up to six months.^{20,21} Also botulinum toxin has been used to relax the sphincter of Oddi in patients with biliary dyskinesia, injection of botulinum toxin into the anal sphincter has been also useful in adults for the treatment of non-relaxing puborectalis muscle and chronic anal fissures.²²⁻²⁴ More recently it has been used in symptomatic children after pull-through surgery for Hirschsprung disease.²⁵

The reported duration of response following botox injection was highly variable ranging from 1 month to greater than 1 year.⁸ The presumed long-lasting benefit in many patients was due to initial drop in sphincter pressure promoting improved defecation with decompression of the distended rectum. This results in decreased rectal volume and improvement in the RAIR. Thus, the beneficial effect of botox in these patients may be to break the cycle of chronic rectal distension that interferes with normal sphincter relaxation and perpetuates constipation.⁸

The lack of response in some patients was either secondary to a failure of the treatment or was due to other problems; such as an injection outside of the sphincter, injection of inactive toxin, use of too low doses, or misdiagnosis.³

Although two cases in our study were considered as initial treatment failure, they responded to a second injection and were passing every three days with laxatives but none of them needed rectal washouts.

Ciamarra et al, also noticed that repeated injections were helpful for some patients who failed an initial injection and suggested repeating one or two injections before considering a child a treatment failure.³

Both the small number of patients enrolled in this study and relatively short follow period are the main limiting factors in this series.

CONCLUSION

Botulinum toxin injection could be safe and effective treatment of chronic constipation in infants and children who fail to respond to medical treatment.

Funding: No funding sources

Conflict of interest: None declared

Ethical approval: The study was approved by the institutional ethics committee

REFERENCES

- Hatch TF. Encopresis and constipation in children. *Pediatr Clin North Am.* 1988;35:257-80.
- Baker SS, Liptak GS, Colletti RB. Constipation in infants and children: evaluation and treatment. A medical position statement of the North American society for pediatric gastroenterology and nutrition. *J Pediatr Gastroenterol Nutr.* 1996;22:38-44.
- Ciamarra P, Nurko S, Barksdale E. Internal anal sphincter achalasia in children: clinical characteristics and treatment with clostridium botulinum toxin. *J Pediatr Gastroenterol Nutr.* 2003;37:315-9.
- Hurst AF. Anal achalasia and megacolon (Hirschsprung's disease, idiopathic dilation of the colon). *Guy's Hosp Rep.* 1934;84:317-50.
- Kobayashi H, Hirakawa H, Puri P. Abnormal internal anal sphincter innervation in patients with Hirschsprung's disease and allied disorders. *J Pediatr Surg.* 1996;31:794-9.
- Oue T, Puri P. Altered intramuscular innervation and synapse formation in internal sphincter achalasia. *Pediatr Surg Int.* 1999;15:192-4.
- Baumgarten HG, Holstein AG, Stelzner F. Nervous elements in the human colon of Hirschsprung's disease. *Vichows Arch Pathol Anat.* 1973;358:113-36.
- Irani K, Rodriguez L, Doody DP. Botulinum toxin for the treatment of chronic constipation in children with internal anal sphincter dysfunction. *Pediatr Surg Int.* 2008;24:779-83.
- Rodriguez L, Flores A. Internal anal sphincter achalasia: relationship with colonic dysmotility and manometric response to botulinum toxin injection. *J Pediatr Gastroenterol Nutr.* 2005;41:496.
- Freeman NV. Intractable constipation in children treated by forceful anal stretch or anorectal myectomy: preliminary communication. *J R Soc Med.* 1984;77(3):6-8
- De Caluwe D, Yoneda A, Akl U, Puri P. Internal anal sphincter achalasia: outcome after internal sphincter myectomy. *J Pediatr Surg.* 2001;36:736-8.
- Banani AS, Forootan H. Role of anorectal myectomy after failed endorectal pull-through in Hirschsprung's disease. *J Pediatr Surg.* 1994;29:1307-9.
- Holschneider AM, Shauer A, Meister P. Results of spincteromyotomy in anal-spincter achalasia. Histology and postoperative continence. *Chirurg.* 1976;47:294-300.
- Heikkinen M, Lindahl H, Rintala RJ. Long-term outcome after internal sphincter myectomy for internal sphincter achalasia. *Pediatr Surg Int.* 2005;21:84-7.
- Brown SR, Matabudul Y, Shorthouse AJ. A second case of long-term incontinence following botulinum injection for anal fissure. *Colorectal Dis.* 2006;8:452-3.
- Hoogerwerf WA, Pasricha PJ. Botulinum toxin for spastic gastrointestinal disorders. *Baillieres Best Pract Res Clin Gastroenterol.* 1999;13:131-43.
- Hallan RI, Williams NS, Melling J. Treatment of anismus in intractable constipation with botulinum A toxin. *Lancet.* 1988;2:714-7.
- Friedman A, Diamond M, Johnston MV, Daffner C. Effects of botulinum toxin A on upper limb spasticity in children with cerebral palsy. *Am J Phys Med Rehabil.* 2000;79:53-9.
- Brant CQ, Siqueira ES, Ferrari AP Jr. Botox for oropharyngeal dysphagia: case report of flexible endoscope-guided injection. *Dis Esophagus.* 1999;12:68-73.
- Cuilliere C, Ducrotte P, Zerbib F. Achalasia: outcome of patients treated with intrasphincteric injection of botulinum toxin. *Gut.* 1997;41:87-92.

21. Schiano TD, Parkman HP, Miller LS. Use of botulinum toxin in the treatment of achalasia. *Dig Dis.* 1998;16:14-22.
22. Wehrmann T, Seifert H, Seipp M. Endoscopic injection of botulinum toxin for biliary sphincter of Oddi dysfunction. *Endoscopy.* 1998;30:702-7.
23. Jost WH, Schimrigk K. Botulin toxin in therapy of anal fissure. *Lancet.* 1995;345:188-9.
24. Shafik A, El-Sibai O. Botulinum toxin in the treatment of non relaxing puborectalis syndrome. *Dig Surg.* 1998;15:347-51.
25. Minkes RK, Langer JC. A prospective study of botulinum toxin for internal anal sphincter hypertonicity in children with Hirschsprung's disease. *J Pediatr Surg.* 2000;35:1733-6.

Cite this article as: Eltayeb AA, Ibrahim NH, Moeen SM, Imam HM. The use of botulinum toxin in children with chronic constipation. *Int Surg J* 2017;4:1845-9.