

## Review Article

# Uterine fibroids: a review

**Cinthia N. Arguelles-Castillo<sup>1</sup>, Juan A. Reyes Pérez<sup>1</sup>, Yazmin Urbano Rojas<sup>1</sup>,  
Gerardo G. Montero Flores<sup>1</sup>, Noe A. Juárez Menéndez<sup>1</sup>, Luis M. Arenas Montes de Oca<sup>1</sup>,  
Tonalmitl Arzola Maldonado<sup>1</sup>, David Sánchez Paredes<sup>1</sup>, Carolina Tapia Navarro<sup>1</sup>,  
Yoliztli Hernández Cruz<sup>1</sup>, Erick Fernando Hernández<sup>2</sup>, Nalleli Durán-López<sup>3</sup>,  
Sofía Barrientos-Villegas<sup>1</sup>, Alan I. Valderrama-Treviño<sup>4\*</sup>**

<sup>1</sup>Department of Diagnostic and Therapeutic Imaging, Dr. Manuel Gea Gonzalez Hospital, CDMX, Mexico

<sup>2</sup>Department of General Surgery, General Hospital of Mexico "Dr. Eduardo Liceaga", CDMX, Mexico

<sup>3</sup>Department of Pathological Anatomy. Hospital Médica Sur, Mexico City, Mexico

<sup>4</sup>Department of Angiology, Vascular and Endovascular Surgery, General Hospital of Mexico, "Dr. Eduardo Liceaga", CDMX, Mexico

**Received:** 17 April 2024

**Accepted:** 02 May 2024

### \*Correspondence:

Dr. Alan I. Valderrama-Treviño,

E-mail: alan\_valderrama@hotmail.com

**Copyright:** © the author(s), publisher and licensee Medip Academy. This is an open-access article distributed under the terms of the Creative Commons Attribution Non-Commercial License, which permits unrestricted non-commercial use, distribution, and reproduction in any medium, provided the original work is properly cited.

## ABSTRACT

Myomatosis of large elements are benign tumors resulting from the growth of muscular and fibrous tissue, which can be embedded or adhered to the uterine wall and their classification varies between submucosal, intramural or subserous depending on the depth they reach. More frequently, symptomatic patients report the presence of abundant abnormal uterine bleeding, dysmenorrhea, dyspareunia and infertility. This pathology represents 40-60% of all hysterectomies, of the total, 30% in women of childbearing age. Different possible triggers of uterine fibroids have been described, which is why it is considered to be of multifactorial origin. Ultrasound is usually used frequently due to its high availability and low cost, this being the first diagnostic image of choice and the gold standard, through transvaginal ultrasound. The management of myomastomas entails a great social problem, since therapy seeks treatment methods that prevent the recurrence of the disease, and in case of satisfied parity, hysterectomy is the ideal option, but in those patients still of fertile age and with desire of pregnancy, less drastic procedures such as myomectomy will be carried out. Finally, some post-surgical complications have been discussed, among which the generation of adhesions due to the scarring resulting from the surgical intervention was described, which could generate infertility or greater difficulty in conceiving.

**Keywords:** Uterine myomatosis, Fibroma, Hysterectomy, Hysteroscopy, Myoma, Leiomyoma

## INTRODUCTION

Fibroids (uterine myomatosis, leiomyomas) are the main cause of morbidity in women during their fertile age. Its incidence varies depending on different factors, including age and ethnicity.<sup>1</sup> These are benign tumors resulting from the growth of muscular and fibrous tissue, which can be embedded or adhered to the uterine wall and their classification varies between submucosal, intramural or subserous depending on the depth they reach.<sup>2</sup> These

tumors are responsible for causing numerous clinical problems in women's health, including dysmenorrhea, infertility, and obstetric problems. This is why this pathology represents 40-60% of all hysterectomies, of the total, 30% in women of childbearing age. Different possible triggers of uterine fibroids have been described, so it is of multifactorial origin, among which different risk factors stand out, such as hormonal factors in which estrogens and progesterone play a key role.<sup>3</sup> Guo et al carried out a study in 2015 in which they suggested that

inflammation caused by bacteria could also be involved in the pathogenesis of uterine myomatosis, mainly explained by the induction of cell proliferation.<sup>2</sup> In patients with a family history of massive uterine fibroid (large element uterine myomatosis). It was demonstrated through cytogenetic studies that the most frequently found cytogenetic aberrations were on chromosomes 6, 7, 12 and 14, leading to alterations in the HMGIC and HMGIY genes that contribute to the development of these tumors. It has been described that the microRNA of the let-7 family plays an important role in the participation together with the HMGA2 gene. HMGA2 overexpression and loss of Let-7 microRNA expression were found to be more common massive uterine fibroid. The HMGA2 gene was analyzed in previous studies and overexpression was found in many benign pathologies and was also associated with larger tumor size.<sup>4</sup> Several studies report that messenger RNA and protein expression of ER-A and ER-B receptors are found in high concentrations in leiomyomas, compared to healthy myometrium. According to this hypothesis, estrogens can exert the growth action of leiomyomas by stimulating the action of cytokines, growth, and apoptotic factors Campione et al suggested the hypothesis that vitamin D deficiency could facilitate transforming growth factor beta (TGF $\beta$ ) signal transduction, having as a compensatory result the autocrine and paracrine secretion of TGF $\beta$  by neoplastic cells and the tumor environment as a consequence of feedback. Inhibitory, however, they consider that further studies are still needed to confirm it.<sup>5</sup> The management of myomatosis entails a great social problem, since therapy seeks treatment methods that prevent the recurrence of the disease, and in case of satisfied parity, hysterectomy is the ideal option, but in those patients still of fertile age and with desire of pregnancy, less drastic procedures such as myomectomy will be carried out, but they will still generate traumatization of the uterus with the subsequent appearance of scars, which may generate a risk in the pregnancy in the disruption of normal uterine functioning and possible risk of rupture during contractions, among others during the course of childbirth.<sup>6</sup> Shi et al carried out in vitro and in vivo experiments confirming that the PI3K/AKT pathway is highly expressed in uterine myomatosis and reported that the Taohong Siwude decoction used in traditional Chinese medicine inhibited the activation of PI3K/AKT through the miR-21-5p/PTEN axis, achieving the weakening of tumor cell proliferation.<sup>7</sup> Therefore, the etiology of large element myomatosis is multifactorial. It has been established that myomatosis begins in an isolated cell of the myometrium that will present a chromosomal aberration, turning it into a monoclonal disorder. Furthermore, the main factors that will influence the appearance are sexual steroid hormones such as estrogen and progesterone. It has been described how estrogen will promote the growth of fibroids and how they grow during the reproductive years and regress in the presence of low levels of estrogen in the cases of postmenopausal patients. Likewise, several studies reported high concentrations of messenger RNA and proteins of the ER-a and ER-b receptors in fibroids

compared to healthy myomas. Based on this, estrogens can generate greater growth action of fibroids, stimulating the action of cytokines and growth and apoptotic factors. Also, the regression of fibroids was observed with the administration of anti-progesterone agent, which further supports the role of progesterone as a promoter of fibroid growth.<sup>4,8</sup> Likewise, insulin-like growth factors, epidermal growth factor and transforming growth factor have also been described.<sup>9,10</sup> Other risk factors that have been implicated have been delayed onset of menstruation, menopause, obesity, late onset of reproductive life, and nulliparity.<sup>11</sup>

## EPIDEMIOLOGY

The incidence of large element myomatosis increases during fertile age. They do not occur before puberty and their frequency decreases with menopause. The average age of diagnosis in the world is 33.5-36.1 years. They are diagnosed in 20-25% in patients of reproductive age between 15 and 40 years old and in 30-40% in patients over 40 years old. In a lower percentage it has been found in patients between 15 and 19 years old and more frequently it has been reported in patients between 20 and 49 years old in very similar proportions.<sup>12,13</sup> A higher incidence has been detected in African American women, having a higher risk of early-onset leiomyomatosis, and of greater size and quantity, with the symptomatic presentation frequently being the predominant one.<sup>11</sup>

## CLINICAL PRESENTATION

It has been estimated that up to 33.3% of patients with large element myomatosis may be clinically asymptomatic. However, the symptoms will be influenced by different factors, among which age stands out, so the most frequent symptoms are described by age ranges in Table 1. Being the presence of abundant abnormal uterine bleeding, dysmenorrhea, dyspareunia, and infertility the most common symptoms in general.<sup>14</sup> Likewise, the size, number and location of the tumor will generate variations in the clinical presentation. In many cases, the presence of other benign uterine pathologies such as endometriosis has been concomitantly associated.<sup>15</sup>

In cases of larger fibroids, it is common to find symptoms generated by pressure that can be evidenced as symptoms of intestinal and bladder dysfunction, urgency, increased urinary frequency, incontinence and abdominal distension. All of these symptoms will interfere with the quality of life.<sup>16</sup>

## DIAGNOSIS

The initial diagnosis is based mainly on imaging aids together with the patient's clinical context. Likewise, some promising biomarkers for diagnosis have been described, such as growth differentiation factor-15, however, the evidence is limited.<sup>3</sup> Ultrasound is usually used frequently due to its high availability and low cost, this being the first

diagnostic image of choice and the gold standard, through transvaginal ultrasound, tumors can be observed that will be described as well-defined hypoechoic masses. With possible calcification and which may also produce an acoustic shadow. Followed by ultrasound, magnetic resonance imaging is usually preferred, as it can evaluate the depth and extension of the fibroids and may be useful to guide surgical management. Finally, the role of tomography in diagnosis has been discussed, which may have a limited role, however, it is excellent for

demonstrating qualifications that are often found in these tumors, but that can also be found in other pathologies of the uterus.<sup>17</sup>

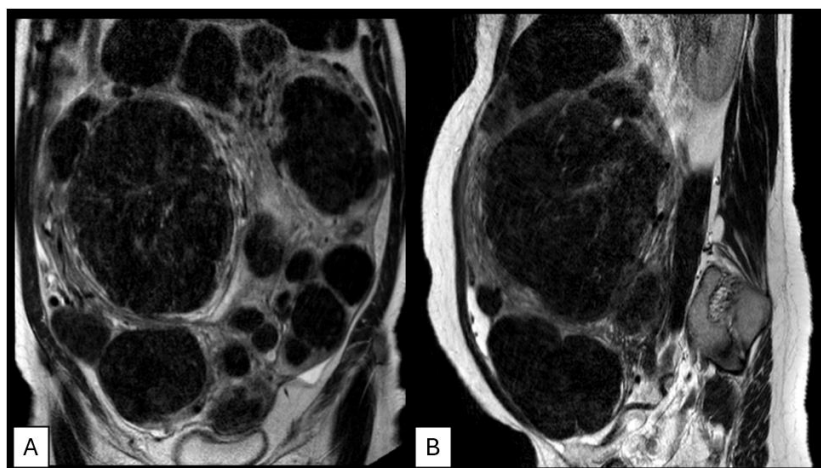
The International Federation of Gynecology and Obstetrics (FIGO) categorized the types of fibroid lesions from 0 to 8 according to their position in the uterus, including those with extrauterine locations. This classification is possible using ultrasound (Table 2).<sup>18</sup>

**Table 1: Main signs and symptoms of uterine fibroids by age range.**

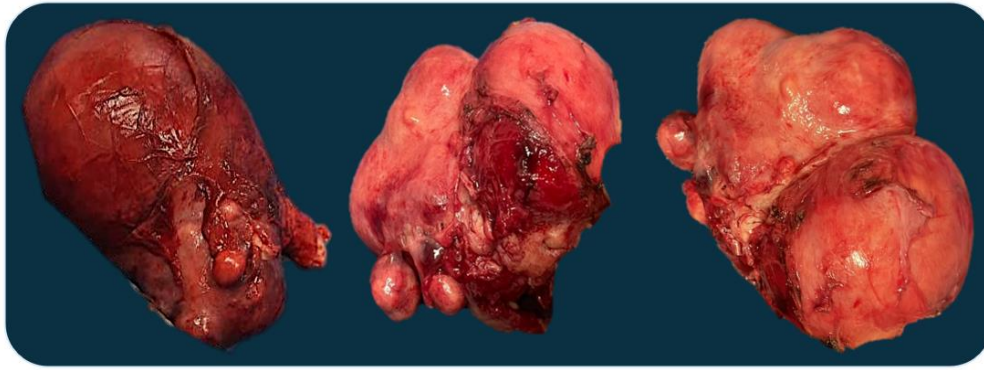
Age (years)	Symptoms	Signs
15-35	Menstrual irregularity, uterine bleeding, pelvic pain, abdominal compression, infertility, dyspareunia. abnormal uterine bleeding	Iron deficiency anemia, pain on abdominal palpation, sensation of abdominal mass on palpation, dyspareunia, abdominal distention
35-45	Infertility, compression symptoms, abnormal uterine bleeding	Abdominal distension, dyspareunia, abdominal pain
>45	Infertility, menometrorrhagia, abnormal uterine bleeding	Iron deficiency anemia

**Table 2: FIGO classification of uterine fibroids.**

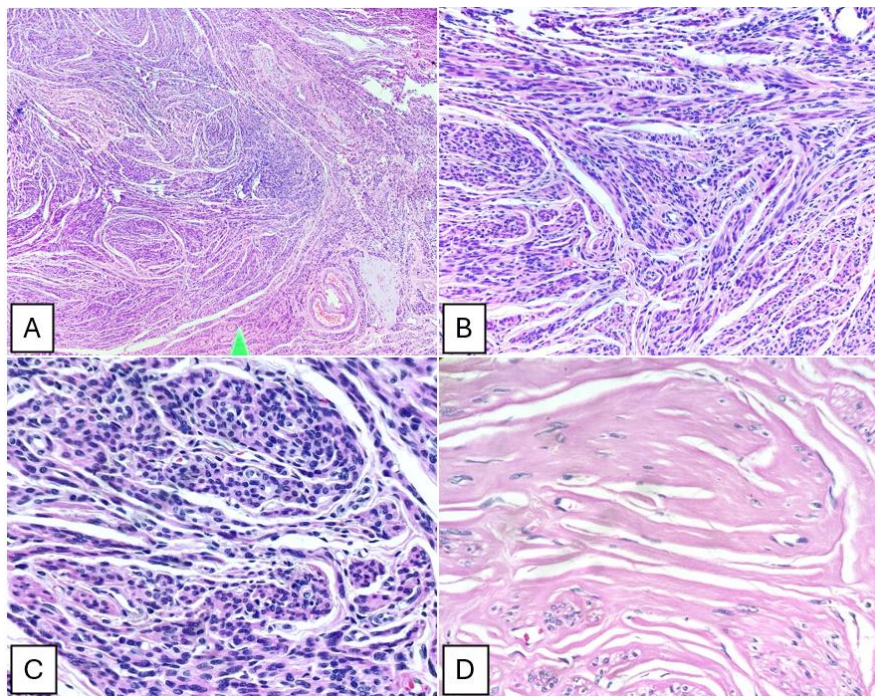
FIGO classification	Characteristics
0	Pedunculated intracavitary: 100% of the fibroid in the uterine cavity
1	Submucosal that is <50% intramural: 50% is within the myometrium and the other portion distorts the endometrium and uterine cavity
2	Submucosal that is ≥50% intramural: less than 50% is within the myometrium and the majority distorts the endometrium and uterine cavity
3	100% intramural but in contact with the endometrium: it is inside the myometrium but touches the endometrium and does not distort the uterine cavity
4	Intramural: completely within the myometrium
5	Subserous that is ≥50% intramural: found predominantly within the myometrium and less than 50% extends outside the myometrium
6	Subserous that is <50% intramural: more than 50% is located outside the myometrium
7	Subserous pedunculate: 100% of the fibroid is located outside the myometrium
8	Other fibroids



**Figure 1: Magnetic resonance imaging in uterine fibroids; (A) T2-weighted MRI in coronal and (B) sagittal sections, showing uterus, measuring 27.8x27.9x14.2 cm in its long axes, heterogeneous myometrium due to multiple images (more than 20) diffusely distributed hypointense nodular lesions with an intramural, subserosa and submucosa location, some with heterogeneous signal inside in relation to hyaline degeneration with different dimensions.**



**Figure 2: Macroscopic image of surgical resections of uterine fibroids.**



**Figure 3: (A) Delimited mesenchymal neoplasm of monotonous spindle cells; (B) cells with indistinct edges arranged in crisscrossing fascicles; (C) cells with round to oval nuclei, with a perinuclear halo, without atypia or dysplasia; and (D) leiomyoma with hyaline degenerative changes.**

## MAGNETIC RESONANCE

Magnetic resonance imaging is the best technique for complete visualization of fibroids (Figure 1). It has the highest sensitivity and specificity compared to other imaging studies available. This image will provide information such as quantity, size and location of them. Also, it will allow identifying the vascular action of the fibroid and its relationship with the different structures, among which the endometrium and serous surface stand out.<sup>8</sup> Furthermore, its use does not represent exposure to ionizing radiation and can easily delimit the anatomy by areas of the uterus, being able to differentiate between submucosal, intramural and subserosal fibroids. Axial and sagittal T2W images and T1W images in at least one plane must be included.<sup>19</sup>

## TREATMENT

Myomatosis of large elements, being a chronic condition, requires lifelong medical attention or surgical management (Figure 2). No medications specifically approved for the management of myomatosis have been described, but some have been described to relieve symptoms, such as bleeding and pain. These medications include nonsteroidal anti-inflammatory drugs, progestins, oral contraceptives, and gonadotropin-releasing hormone analogues.<sup>15</sup>

Currently, the surgical management choice must be considered taking into account the gestational desire in cases where the patient is of a fertile age, since the procedure will change depending on the patient's context. Myomectomy is the management of choice in patients with

the desire to become pregnant. The technique of choice should be endoscopic, whenever possible; however, the route of choice will depend on the location, number and size of the fibroid. Hysteroscopic and laparoscopic myomectomy being the gold standard. This is because it has been shown that with this method there will be less blood loss, lower rates of adhesions and less postoperative morbidity compared to an open technique. In the long term, it could allow better pregnancy rates. This surgery is indicated for those submucous and intramural fibroids that affect the endometrial cavity.<sup>20</sup> In those patients who have a satisfied parity, a more radical surgical management such as hysterectomy will be the management of choice, potentially avoiding the recurrence of the pathology. The use of diode laser for hysteroscopy has been described as a safe and effective alternative treatment to surgical intervention using the outpatient "observe and treat" approach, achieving a reduction in costs, waiting times and the need for anesthesia. However, new studies must be carried out to consolidate the evidence in patient use. Among the possible post-surgical complications, intraoperative bleeding, infection, and pain in the operated area along with possible hematomas have been described. In cases where the treatment of choice has been the diode laser, abdominal pain should not be overlooked, due to the possible ischemic necrosis of the fibroids and their risk of infection. Finally, the generation of adhesions due to the healing product of the surgical intervention was frequently described and could cause infertility or greater difficulty in conceiving.<sup>14</sup>

## DISCUSSION

It is of great value to understand how uterine fibroids alter normal uterine function, frequently leading to endometrial dysfunction. The importance of an adequate management approach in patients has been discussed, considering the clinical context and the patient's expectations.<sup>21</sup> The patient's presentation will arouse the treating physician's suspicion of a possible diagnosis through an adequate anamnesis along with a complete pelvic examination. Initial identification with the use of ultrasound will be the imaging aid of choice due to its low cost and high availability; However, magnetic resonance imaging is among the most preferred and most useful diagnostic aids due to its effectiveness in characterizing fibroids and their exact location. In some cases, they are found in asymptomatic patients and incidental findings have frequently been reported during imaging performed for other indications.<sup>19,22</sup> The best way to perform timely detection in patients is through education about possible symptoms and when to consult in the context of having any of the following risk factors for suffering from uterine fibroids: African descent, age >40 years, menarche before the age of 10, family history, nulliparity and obesity. The ideal management will vary depending on the patient's context, surgical intervention is the most recommended, with myomectomy being the most frequently performed and mainly seeks 4 objectives: improve symptoms, reduce

the size of fibroids, maintain fertility if desired, and do no harm. In those patients with asymptomatic clinical presentation in any age range, clinical follow-up is recommended. In the case of presenting symptoms, each patient must be characterized according to their wishes. In the case of young patients in the age range of 15 to 35 years who wish to become pregnant, the treatment to choose will be myomectomy by minimally invasive methods or medical management depending on the condition (Figure 3), it has been accepted that patients under 35 years of age have seen higher post-myomectomy fertility, even more so in those with sterility of less than 3 years.<sup>23</sup> If the patient is in the same group mentioned above, and has satisfied parity, but hysterectomy is not an option, myomectomy or uterine arterial embolization is recommended. For those symptomatic patients who have satisfied parity and want radical management, hysterectomy by minimally invasive methods is recommended. The age range here can vary depending on the patient's wishes; however, it has been reported that the greatest number of hysterectomized women are those over 60 years of age.<sup>21</sup>

## CONCLUSION

Large element uterine myomatosis, caused by the growth of benign tumors composed of muscular and fibrous tissue in the uterine wall, is a condition that significantly affects the health of women of childbearing age. This condition of multifactorial origin can be influenced by hormonal, genetic and environmental factors. The most common symptoms include heavy abnormal uterine bleeding, dysmenorrhea, dyspareunia and infertility, significantly affecting the quality of life of patients. In addition, large fibroids can cause additional symptoms due to the pressure they put on neighboring organs, such as bowel and bladder dysfunction. The diagnosis is based on clinical evaluation together with imaging techniques such as transvaginal ultrasound, which is the diagnostic modality of choice due to its availability and low cost. MRI may be useful to evaluate the extent of fibroids and guide surgical management. The treatment will be chosen according to the needs and desires of the patient. Myomectomy, especially by endoscopic routes, is preferred in women desiring pregnancy, as it preserves fertility and has lower postoperative complication rates compared to an open technique. However, hysterectomy remains the primary option in women with satisfied parity.

The emerging use of technologies such as diode laser hysteroscopy offers a safe and effective alternative to traditional surgical intervention, with the advantage of being less invasive and allowing an outpatient approach. Some postsurgical complications, such as intraoperative bleeding, infection, and adhesion formation, may occur and should be considered in treatment planning.

*Funding: No funding sources*

*Conflict of interest: None declared*

*Ethical approval: Not required*

## REFERENCES

1. Rosales Costa K, Bastos Metzger P. Endovascular treatment of uterine myomatosis: a systematic review. *J Vasc Bras.* 2020;19:e20190149.
2. Medina-Bastidas D, Camacho-Arroyo I, García-Gómez E. Current findings in endometrial microbiome: impact on uterine diseases. *Reproduction.* 2022;163:R81-96.
3. Onishi K, Zhang, Blanck JF. A systematic review of matrix metalloproteinases as potential biomarkers for uterine fibroids. *Fertil Steril Rev.* 2022;3(4):2666-5719.
4. Medikare V, Kandukuri LR, Ananthapur V, Deenadayal M, Nallari P. The genetic bases of uterine fibroids; a review. *J Reprod Infertil.* 2011;12(3):181-91.
5. Campione E, Di Prete M, Costanza G, Saggini A, Agostinelli S, Terrinoni A, et al. Increased Occurrence of Cutaneous Leiomyomas and Dermatofibromas in Patients with Uterine Leiomyomas without Fumarate Hydratase Gene Mutations. *Dermatopathology.* 2023;10:231-43.
6. Kuznetsova MV, Tonoyan NM, Trubnikova EV, Zelensky DV, Svirepova KA, Adamyan LV, et al. Novel Approaches to Possible Targeted Therapies and Prophylaxis of Uterine Fibroids. *Diseases.* 2023;11:156.
7. Shi S, Luo L, Peng F, Yu C. Potential mechanism of Taohong Siwu Decoction in uterine fibroid treatment based on integrated strategy of network pharmacology and experimental verification. *Chinese Med.* 2023;18:95.
8. Hernández-Valencia M, Valerio-Castro E, Tercero-Valdez-Zúñiga CL, Barrón-Vallejo J, Luna-Rojas RM. Uterine myomatosis: Implications on reproductive health. *Gynecol Obstet Méx.* 2017;85(9):611-33.
9. Lethaby A, Vollenhoven B. Fibroids uterine myomatosis, leiomyomas. *BMJ Clin Evid.* 2007;08:14.
10. Torres de la Roche LA, Becker S, Cezar C, Hermann H, Larbig A, Leicher L. Pathobiology of myomatosis uteri: the underlying knowledge to support our clinical practice. *Arch Gynecol Obstet.* 2017;296:701-7.
11. Montiel-Jarquín AJ, García-Ramírez UN, Morales-Castillo JC, Bobadilla-Valenzuela R, Mendoza-García AV, López-Hernández A. Leiomiomatosis uterina de grandes elementos en una paciente joven. *Revista Médica del Instituto Mexicano del Seguro Social.* 2008;46(6):677-80.
12. Sparic R, Mirkovic L, Malvasi A, Tinelli A. Epidemiology of Uterine Myomas: A Review. *Int J Fertil Steril.* 2016;9(4):424-35.
13. Zimmermann A, Bernuit D, Gerlinger C, Schaeffers M, Geppert K. Prevalence, symptoms and management of uterine fibroids: an international internet-based survey of 21,746 women. *BMC Womens Health.* 2012;26:12:6.
14. Etrusco A, Buzzaccarini G, Laganà AS, Chiantera V, Vitale SG, Angioni S. Use of Diode Laser in Hysteroscopy for the Management of Intrauterine Pathology: A Systematic Review. *Diagnostics.* 2024;14:327.
15. Tokarz J, Adamski J, Tea Rižner TL. Metabolomics for Diagnosis and Prognosis of Uterine Diseases? A Systematic Review. *J Pers Med.* 2020;10:294.
16. Donnez J, Dolmans MM. Uterine fibroid management: from the present to the future. *Hum Reprod Update.* 2016;22(6):665-86.
17. Sun S, Bonaffini P, Nougaret S, Fournier L, Dohan A, Chong J, et al. How to differentiate uterine leiomyosarcoma from leiomyoma with imaging. *Diagnost Intervent Imaging.* 2019;100(10):619-34.
18. Palheta MS, Medeiros FDC, Severiano ARG. Reporting of uterine fibroids on ultrasound examinations: an illustrated report template focused on surgical planning. *Radiol Bras.* 2023;56(2):86-94.
19. Wilde S, Scott-Barrett S. Radiological appearances of uterine fibroids. *Indian J Radiol Imaging.* 2009;19(3):222-31.
20. Morales HSG, López RR, López GGP, Mondragón PJC, Cortés DV, Hernández HS, et al. Surgical approach to uterine myomatosis in patients with infertility: open, laparoscopic, and robotic surgery; results according to the quantity of fibroids. *JBRA Assist Reprod.* 2022;26(1):44-9.
21. De La Cruz M Syl D, Buchanan EM. Uterine Fibroids: Diagnosis and Treatment. *Am Fam Physician.* 2017;95(2):100-7.
22. Gao M, Bhosale P, Devine C, Palmquist S, Javadi S. US, MRI, CT Performance and Interpretation of Uterine Masses. *Seminars in Ultrasound, CT and MRI.* 2023;44(6):541-59.
23. Fábregues F, Peñarrubia J. Mioma uterino. Manifestaciones clínicas y posibilidades actuales de tratamiento conservador. *Med Integral.* 2002;40(5):190-5.

**Cite this article as:** Arguelles-Castillo CN, Pérez JAR, Rojas YU, Flores GGM, Menéndez NAJ, Montes de Oca LMA, et al. Uterine fibroids: a review. *Int Surg J* 2024;11:1041-6.