

Case Report

Rectus sheath hematoma in post-lower segment caesarean section patient

Sunaina Kamboj*, Naresh Pal, Bhavinder Kumar Arora

Department of General Surgery, P. G. I. M. S, Rohtak, Haryana, India

Received: 22 April 2024

Accepted: 21 May 2024

*Correspondence:

Sunaina Kamboj,

E-mail: sunainakamboj110@gmail.com

Copyright: © the author(s), publisher and licensee Medip Academy. This is an open-access article distributed under the terms of the Creative Commons Attribution Non-Commercial License, which permits unrestricted non-commercial use, distribution, and reproduction in any medium, provided the original work is properly cited.

ABSTRACT

Rectus sheath hematoma is a rather uncommon and often misdiagnosed clinical condition, usually follows abdominal trauma and anticoagulation. The daily activities of patient like sitting and lying in the bed produced the trauma which led to formation of hematoma. This trauma led to tear of inferior epigastric artery, which started bleeding with in the rectus sheath leading to formation of a big hematoma. Exploratory laparotomy was done. A hematoma of size 5×6 cm was visualized between anterior rectus sheath and rectus muscle on right side. Rectus muscle hematoma is due to shearing force to the inferior epigastric vessels due to routine activity of the patient.

Keywords: Rectus sheath hematoma, Inferior epigastric artery, Lower segment caesarean section

INTRODUCTION

Rectus sheath hematoma is a rather uncommon and often misdiagnosed clinical condition, usually follows abdominal trauma and anticoagulation.¹ Lower abdominal surgeries may put local tissue in unnatural tension leading to increased stress on vessel wall.² The rectus sheath hematoma presenting in post-operative period in lower segment caesarean section (LSCS) is of rare occurrence. With increasing use of anticoagulants it is becoming a source of significant morbidity and mortality. The diagnosis is usually made clinically and later confirmed with CT abdomen.³ Considering its potential to occur spontaneously leading in some cases to death, rectus sheath hematoma should be included in the differential diagnosis of an abdominal mass of sudden onset, more so in patients receiving anticoagulants, pregnancy and those who had lower abdominal surgeries.⁴ Here we presented a case of a woman with pre-eclampsia presenting with spontaneous abdominal wall hematoma post-LSCS.

CASE REPORT

The patient, a 23-year-old female with a history of LSCS, 7 days back in a peripheral hospital was admitted to labor room of a tertiary care hospital. She complained of fever and discharge from incision line of LSCS. She also complained of non-passage of stool and flatus. The patient had LSCS 7 days back in view of pre-eclampsia and previous LSCS (under SA). Patient was shifted to ICU in view of increased BP. After 1 day of ICU stay patient was shifted back to ward. On POD3 she had abdominal distention and discharge from incision line. On POD7 patient was referred to PGIMS where a diagnosis of fever with anemia with SBO with thrombocytopenia was made. On POD13 a swelling of size ~5×6 cm developed in the right lumbar region which was globular, firm, tender, non-pulsatile and non-expansile with no skin changes. On ultrasonography a hypo echoic lesion of ~7×10 cm was in the vicinity of right rectus muscle. A hematoma was seen. A quick CBC revealed a hemoglobin of 6.5 gm/dl. Patient received 2 units of PRBC preoperatively. After initial workup, patient was operated under department of obstetrics and gynecology with assistance from general surgeons. A diagnosis of anterior abdominal wall hematoma was

made. Exploratory laparotomy was done. A hematoma of size 5×6 cm was visualized between anterior rectus sheath and rectus muscle on right side (Figure 1). Actively bleeding right inferior epigastric artery was visualized. Evacuation of hematoma was done and hemostasis achieved with ligation of right inferior epigastric artery. Post-operatively patient was transferred to surgery ward, where 2 units each of PRBC and FFP was transfused. Patient was discharged on POD4 under stable condition for OPD based follow up.

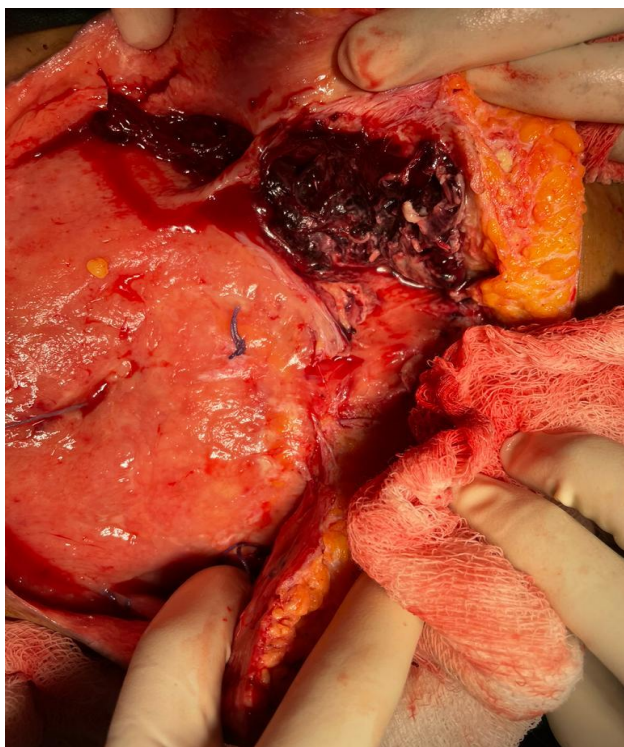


Figure 1: A large rectus sheath hematoma.

DISCUSSION

Rectus sheath hematoma although rare, are rarely clinically inconspicuous when they do form. Usually, they result from a traumatic or spontaneous rupture of inferior epigastric artery, more often than superior epigastric artery, and in very unusual case rupture of muscle itself.⁵ The pooling of blood and hematoma formation happens on the posterior surface of rectus abdominis muscle. Patient presented with sudden onset pain abdomen associated with a swelling which rapidly increased in size. Sometimes patient presented with shock more so in cases of inferior epigastric artery bleed due to lack of a posterior sheath and the tamponade effect it creates.⁶ The patient, mostly female, often had a history of recent trauma, lower abdominal surgery or on anticoagulation. In our case the rectus muscle hematoma was formed after LSCS.⁷ The incision was open and infected. The inferior epigastric artery formed hematoma

in right rectus muscle. A large hematoma was formed, which presented as swelling and bleeding at the site of LSCS incision.⁸ The bleeding was just an ooze. The patient was explored. A big hematoma was seen in the right rectus sheath. The hematoma was evacuated and bleeding vessels were seen which were ligated. The wound was closed. The mechanism of injury to the inferior epigastric vessels appears to be shearing force to the vessels which started bleeding and formed a hematoma.⁹ There was no bleeding from the LSCS wound due to secondary hemorrhage. The formation of rectus muscle hematoma after LSCS incision is the first of case reported in medical literature.

CONCLUSION

Rectus muscle hematoma formation after LSCS is of rare occurrence and is due to shearing force to the inferior epigastric vessels due to routine activity of the patient, while sitting and lying in the bed. Although the LSCS wound was opened, still there was no bleeding from the wound.

Funding: No funding sources

Conflict of interest: None declared

Ethical approval: Not required

REFERENCES

1. Allen M, Sevensma KE. Rectus sheath hematoma. Treasure Island: StatPearls Publishing; 2023.
2. Cherry WB, Mueller PS. Rectus sheath hematoma: review of 126 cases at a single institution. *Medicine*. 2006;85(2):105-10.
3. Hatjipetrou A, Anyfantakis D, Kastanakis M. Rectus sheath hematoma: a review of the literature. *Int J Surg*. 2015;13:267-71.
4. Ducatman BS, Ludwig J, Hurt RD. Fatal rectus sheath hematoma. *JAMA*. 1983;249(7):924-5.
5. Sobkin PR, Bloom AI, Wilson MW, LaBerge JM, Hastings GS, Sheth HS, et al. Massive abdominal wall hemorrhage from injury to the inferior epigastric artery: a retrospective review. *J Vasc Interv Radiol*. 2008;19(3):327-32.
6. Kaldas H, Smith RE. Evaluation of risk factors for rectus sheath hematoma. *Clin Appl Thromb Hemost*. 2016;22(3):292-6.
7. Drinnon K, Simpson SS, Puckett Y, Ronaghan CA, Richmond RE. Rectus sheath hematoma: A rare surgical emergency. *Cureus*. 2020;12(12).
8. Bello G, Blanco P. Giant rectus sheath hematoma. *Ultrasound J*. 2019;11(1):1-5.
9. Rimola J, Perendreu J, Falcó J, Fortuño JR, Massuet A, Branera J. Percutaneous arterial embolization in the management of rectus sheath hematoma. *Am J Roentgenol*. 2007;188(6):497-502.

Cite this article as: Kamboj S, Pal N, Arora BK. Rectus sheath hematoma in post-lower segment caesarean section patient. *Int Surg J* 2024;11:1027-8.