

Case Report

A heterotopic pregnancy at 12 weeks pregnancy

Wiwin Suhandri*, Diki Riandi

Department of Obstetrics and Gynecology, Faculty of Medicine, University of Riau/Arifin Achmad General Hospital, Pekanbaru, Indonesia

Received: 19 April 2024

Revised: 09 May 2024

Accepted: 13 May 2024

*Correspondence:

Dr. Wiwin Suhandri,

E-mail: wiwinsuhandri@lecturer.unri.ac.id

Copyright: © the author(s), publisher and licensee Medip Academy. This is an open-access article distributed under the terms of the Creative Commons Attribution Non-Commercial License, which permits unrestricted non-commercial use, distribution, and reproduction in any medium, provided the original work is properly cited.

ABSTRACT

Heterotopic pregnancy (HP) represents a rare and complex condition where simultaneous pregnancies occur at different implantation sites, with only one located within the uterine cavity. Typically diagnosed in the first trimester, HP presents diagnostic challenges due to its rarity and varying clinical presentations. Here, we present a unique case of HP diagnosed at Bengkalis Hospital involving a 42-year-old multipara at 12 weeks of gestation. The patient's presentation included regular uterine contractions and upper abdominal pain, with a positive Plano test upon admission. Despite experiencing vaginal bleeding two days prior and an initial refusal of care, further examination revealed a 2.13 cm gestational sac in the intrauterine cavity, consistent with the gestational age. Additionally, free intra-abdominal fluid was observed in the Douglas cavity. Haematological examination indicated a low haemoglobin level of 7.2 g/dl and elevated leukocytes at 16,000. An emergency laparotomy revealed a ruptured right ovarian tube containing a gestational sac, which was managed with hemostasis and a subsequent salpingectomy. The left ovarian tube underwent a tubectomy as a preventive measure. The patient received multiple blood transfusions, leading to an improvement in haemoglobin levels to 10.2 g/dl postoperatively. Following a two-day hospitalisation, the patient was discharged in good general condition. HP cases often necessitate laparotomies for tubal pregnancies, and ultrasound plays a crucial role in diagnosis, especially given its prevalence of 1 in 7000 due to assisted reproduction. Treatment typically involves laparoscopic or laparotomic intervention, highlighting the multidisciplinary approach required for managing this rare condition.

Keywords: Acute abdomen, Ectopic pregnancy, Heterotopic pregnancy, Second-trimester diagnosis

INTRODUCTION

Heterotopic pregnancy (HP) is a rare condition marked by the simultaneous occurrence of two pregnancies at different implantation sites, one being in the uterus. Its prevalence varies widely, from approximately 1 in 30,000 in natural cycles to around 1 in 100 in cases involving assisted reproduction.^{1,2} Although HP shares symptoms with ectopic pregnancy, such as abdominal pain, vaginal bleeding, and positive pregnancy tests, diagnosing it can be more complex. Despite advancements in ultrasound technology, diagnosis often hinges on the presence of acute abdominal symptoms.³ If undetected in the first trimester, HP can result in a nontraumatic acute abdomen. We present an exceptional case of HP discovered at 26

weeks of gestation, with the patient experiencing hemoperitoneum post-tubal rupture. This represents, to our knowledge, the first reported instance of such a late-onset symptomatic HP in medical literature.⁴

CASE REPORT

A 42-year-old multipara presented at Bengkalis Hospital at 12 weeks of pregnancy due to regular uterine contractions and upper abdominal pain. The plano test upon admission was positive. She had complained of vaginal bleeding two days prior and had been denied care. The patient had no significant medical or gynaecological history and had received prenatal care at a private facility separate from the hospital. She had never undergone an

ultrasound examination before. Upon scanning in the emergency unit, the adnexa were assessed. An ultrasound examination revealed a gestational sac in the intrauterine cavity with a diameter of 2.13 cm, consistent with 12 weeks' gestation. Additionally, another gestational sac was found in the intrauterine cavity with a diameter of 2.17 cm, also consistent with 12 weeks' gestation. Furthermore, an image of free intra-abdominal fluid was detected, specifically in the Douglas cavity.

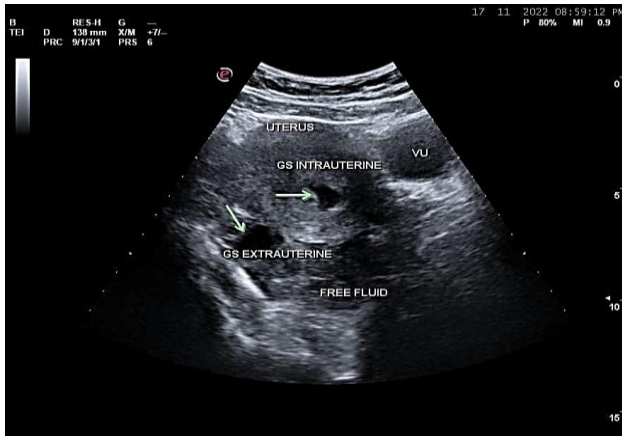


Figure 1: Ultrasound examination.

The patient underwent a haematological examination, revealing a low Hb level of 7.2 g/dl and an increase of 16,000 leukocytes. Upon physical examination, tenderness was noted in the right lower abdomen, with normal intestinal peristalsis, and the conjunctiva appeared anemic. Portio livide was observed during speculum examination, with a closed os uteri externum (OUE) and positive fluxus. Subsequently, a vaginal touch examination was conducted, revealing a supple portio with lingering pain. Based on the history, physical examination findings, and additional support, the decision was made to perform an emergency laparotomy with the preparation of 3 units of packed red blood cells (PRC). Given the patient's age of 42 and having three living children, both the husband and patient requested a tubectomy concurrently.

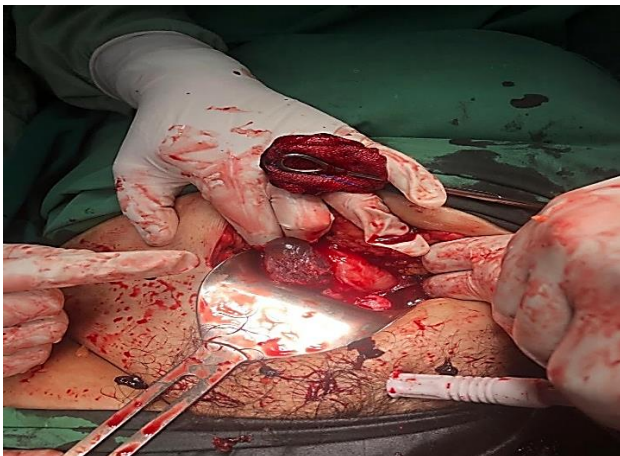


Figure 2: Gestational sac intra operation.

During the operation, numerous blood clots were discovered in the abdominal cavity, which were subsequently removed. The area was then explored, revealing a gestational sac and a ruptured right ovarian tube. Hemostasis was achieved using long clamps, followed by a salpingectomy on the right ampullary ovarian tube and a tubectomy on the left ovarian tube. The abdominal lining was sutured layer by layer. Throughout the procedure, the patient received two blood transfusions and one bag of fluid in the operating room. Following the transfusions, a haematological examination was conducted, yielding a result of 10.2 g/dl. The patient remained hospitalised for 2 days before being discharged in good general condition.

DISCUSSION

Diagnosing heterotopic pregnancy presents clinical challenges, often necessitating laparotomies for tubal pregnancies. Concurrently, the uterus may exhibit congestion, softening, and enlargement, typically detectable via ultrasound, revealing gestational products. Initially estimated at 1 in 30,000 pregnancies, recent data suggest a higher incidence, particularly due to assisted reproduction techniques, with rates around 1 in 7000 for natural conception and up to 1 in 900 with ovulation induction.⁵ The rising prevalence of multiple pregnancies from ovulation induction and IVF increases the risks of ectopic and heterotopic pregnancies. Patients with a history of tubal surgeries may face heightened risks, in this case, the patient had no history of tubal surgery.^{6,7}

Heterotopic pregnancy can manifest diversely, including a higher likelihood of abortion, especially post-assisted reproduction or with persistent chorionic gonadotropin levels after dilatation and curettage.⁸ Hematometra and lower quadrant pain may occur in early pregnancy, but they were not found in this patient. While most ectopic pregnancies in heterotopic cases involve the fallopian tube, cervical and ovarian heterotopic pregnancies have been reported. Though rare, singleton intrauterine pregnancies are the most common, with triplet and quadruplet heterotopic pregnancies reported even more rarely.^{9,10}

Clinical analysis can be complicated by other surgical conditions mimicking heterotopic gestation, like bicornuate uterus with gestation in both cavities. High-resolution transvaginal ultrasound with color Doppler imaging aids diagnosis, showing increased blood flow to trophoblastic tissue in the adnexa with a decreased resistance index. Treatment typically involves laparoscopy or laparotomy for the tubal pregnancy.^{11,12}

CONCLUSION

The illustrated case had no risk factor for heterotopic pregnancy and offered ruptured tubal pregnancy with hemodynamic instability due to hemoperitoneum. A heterotopic pregnancy, although extraordinarily uncommon, can still result from a herbal idea; it requires

an excessive index of suspicion for an early and well-timed diagnosis, and a well-timed intervention can result in successful final results for the intrauterine fetus.

Funding: No funding sources

Conflict of interest: None declared

Ethical approval: Not required

REFERENCES

1. Govindarajan M, Rajan R. Heterotopic pregnancy in natural conception. *J Hum Reprod Sci.* 2008;1:37.
2. Tulandi T, Vilos G, Gomel V. Laparoscopic treatment of interstitial pregnancy. *Obstet Gynecol.* 2016;85:465-7.
3. Glassner MJ, Aron E, Eskin BA. Ovulation induction with clomiphene and the rise in heterotopic pregnancies. A report of two cases. *J Reprod Med.* 2000;35:175-8.
4. Chi H, Qiao J, Li H, Liu P, Ma C. Double measurements of serum HCG concentration and its ratio may predict IVF outcome. *Reprod Biomed Online.* 2010;20(4):504-9.
5. Shavit T, Paz-Shalom E, Lachman E, Fainaru O, Ellenbogen A. Unusual case of recurrent heterotopic pregnancy after bilateral salpingectomy and literature review. *Reprod Biomed Online.* 2013;26(1):59-61.
6. Payne S, Duge J, Bradbury W. Ectopic pregnancy concomitant with twin intrauterine pregnancy. A case report. *Obstet Gynecol.* 2011;38:905-6.
7. Lautmann K, Staboulidou I, Wüstemann M, et al. Heterotopic Pregnancy: Simultaneous Intrauterine and Ectopic Pregnancy Following IVF Treatment with the Birth of a Healthy Child. *Ultraschall in der Medizin - European Journal of Ultrasound* 2017;30: 71–3.
8. Nabi U, Yousaf A, Ghaffar F, Sajid S, Ahmed MMH. Heterotopic Pregnancy - A Diagnostic Challenge. Six Case Reports and Literature Review. *Cureus.* 2019;11(11):e6080.
9. Govindarajan M, Rajan R. Heterotopic pregnancy in natural conception. *J Hum Reprod Sci.* 2018;1:37.
10. Sherer DM, Scibetta JJ, Sanko SR. Heterotopic quadruplet gestation with laparoscopic resection of ruptured interstitial pregnancy and subsequent successful outcome of triplets. *Am J Obstet Gynecol.* 2005;172:216-7.
11. Alsunaidi MI. An unexpected spontaneous triplet heterotopic pregnancy. *Saudi Med J.* 2005;26:136-8.
12. Cheng P-J, Chueh H-Y, Qiu J-T. Heterotopic Pregnancy in a Natural Conception Cycle Presenting as Hematometra. *Obstet Gynecol.* 2004;104:1195-8.

Cite this article as: Suhandri W, Riandi D. A heterotopic pregnancy at 12 weeks pregnancy. *Int Surg J* 2024;11:967-9.