

Case Series

Better out than in: a case series of retained rectal foreign bodies in a New York Community Hospital

Jane Tian¹, Patrick Kiarie², Catherine Olang², Christina Sneed², Luis Fernandez², Andrew Miele³, Stephen Curry², Martine A. Louis^{1*}, Neil Mandava¹

¹Department of General Surgery, Flushing Hospital Medical Center, New York, USA

²Saint George's University School of Medicine, True Blue, Grenada, USA

³Department of Clinical Research, Medisys Health Network, New York, USA

Received: 04 April 2024

Revised: 13 May 2024

Accepted: 20 May 2024

*Correspondence:

Dr. Martine A. Louis,

E-mail: mlouis2.flushing@jhmc.org

Copyright: © the author(s), publisher and licensee Medip Academy. This is an open-access article distributed under the terms of the Creative Commons Attribution Non-Commercial License, which permits unrestricted non-commercial use, distribution, and reproduction in any medium, provided the original work is properly cited.

ABSTRACT

Retained rectal foreign bodies (FB) are rare and present diagnostic dilemmas due to the varying clinical presentations and embarrassment experienced by patients, preventing patients from being forthcoming about the cause of their symptoms. Furthermore, the variability in size, shape, and depth of insertions calls for physicians and surgeons to be resourceful and creative with their management. We present 8 cases of rectal foreign bodies between October 2012 and April 2023. We excluded patients that had foreign bodies from oral ingestion. Of the patients, 62.5% came during the night shift; 75% of patients were forthcoming about inserting their foreign bodies. 12.5% of cases successfully passed the FB in the emergency department (ED), 50% underwent rectal examination under anesthesia (EUA), two were successfully removed, 25% underwent exploratory laparotomy, and 12.5% refused intervention. The median time from incident to presentation to the ED was 2.5 days; the median hospital length of stay (LOS) was one day. Further investigation regarding seasonality, time/day of presentation, and time from insertion to presentation could benefit in increasing healthcare awareness of FB. Our results showed that most patients presented during the night hours, which increased clinical suspicion for patients presenting with complaints consistent with retained foreign bodies since faster diagnosis and interventions are associated with reduced complications and improved patient outcomes.

Keywords: Foreign body extraction, Rectal foreign bodies, Retained rectal foreign bodies

INTRODUCTION

The annual incidence of presentations for rectal foreign bodies (FB) increased from 1.2 in 2012 to 1.9 per 100,000 persons in 2021.¹ Males have a bimodal age distribution peaking in the 5th decade, while females have a right-skewed age distribution peaking in the 2nd decade.² Patients presenting with a rectal FB are often embarrassed and reluctant to seek medical attention, attempting self-retrieval via digital or instrumental manipulation before presentation. Retained rectal FB can vary and can be seen on imaging and sometimes palpated by digital rectal exam (DRE). Management of retained rectal FBs requires an

individualized approach based on the impacted FB's size, shape, nature, and location, sometimes requiring retrieval via laparoscopy or laparotomy in cases of perforation. Reducing the time between insertion and presentation to the emergency department (ED) for removal is imperative in improving patient outcomes and sparing complications; there is little literature on the seasonality of presentation, and we found no literature evaluating the most common presentation time. Increased clinical suspicion during typical times of presentation can help reduce rates of complications and hospital length of stay (LOS). We present our experience with retained rectal FBs in a New York (NY) community hospital (Table 1).

CASE SERIES

Patient 1

A 48-year-old male with no medical history presented to the ED with bright red blood per rectum after a rectal insertion of a foreign body by the patient a few hours while he was having sexual intercourse. The object, a deodorant spray, became entrapped, and multiple attempts to retrieve it failed. A radiograph of the abdomen revealed a cylindrical radiopaque foreign body in the rectosigmoid junction (Figure 1). The patient underwent EUA for trans-anal foreign body retrieval. The distal end of the can was about 7 cm from the anal verge and could be palpated at the level of the umbilicus. A Kocher clamp was used to grasp the edge of the can and was removed trans anally. The patient was extubated, transferred to recovery in stable condition, and discharged home later that day.

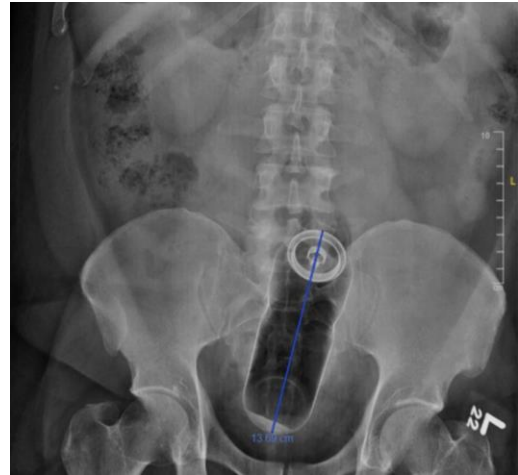


Figure 1: Abdominal radiograph showing a cylindrical radiopaque foreign body in the rectosigmoid junction.

Table 1: Patient presentation, demographics, chief complaint, FB characteristics, LOS, and removal method.

Patient	Age	Sex	Chief complaint	Retained foreign body	Incident to ED	Month of presentation	LOS (days)	FB location	Removal
1	48	M	Retained FB, bright red blood per rectum	Deodorant spray can	14 hours	November	1	Rectum	Operating room (OR): examination under anesthesia (EUA) with trans anal removal with coker clamp
2	33	F	Retained FB, abdominal pain	16 heroin packets	3 days	July	1	Distal colon	ED: spontaneous passage
3	30	M	Abdominal pain, constipation	Remote control	3 days	February	12	Colon	OR: exploratory laparotomy
4	64	F	Incidental finding	Unknown	Un-known	August	17	Rectum	None: refused evaluation of foreign body
5	72	M	Retained FB	Prostate massager	2 days	April	1	Rectum	OR: EUA with trans anal removal with sponge clamp
6	35	M	Retained FB	Aluminium bullet sex toy (vibrating)	5 days	June	1	Rectum	None documented: left against medical advice
7	52	M	Retained FB	Rubber sex toy	17 hours	August	1	Rectum	OR: EUA with trans anal removal with ringed forceps
8	42	M	Retained FB, witnessed seizures, vomiting.	12 cocaine packages (a few ruptured)	Unknown	March	17	Stomach, small bowel, colon, rectum	OR: exploratory laparotomy

Patient 2

A 23-year-old female with a past medical history of asthma and gastroesophageal reflux disease (GERD) was brought in by police after being apprehended at the local

international airport for internal concealment of heroin pellets ingested and rectally inserted. The patient had been in police custody for the past three days and had passed 11 packets in the feces before admission. A computed tomography (CT) scan of the abdomen revealed five

radiopaque foreign bodies seen in the distal colon and an abdominal X-ray was also performed, and no perforation was noted. The patient was admitted to telemetry for observation and monitoring until the remaining pellets were passed. The patient was given magnesium citrate, and a surgical consult was called in the event of obstruction or rupture. The patient remained clinically stable, passed the remaining five intact pellets in feces, and was discharged to police custody.

Patient 3

A 30-year-old male presented to the ED with a 3-day history of abdominal pain and nausea after binge drinking with friends the days prior. The patient stated he felt a foreign body in his rectum but denied recollection of its insertion. He had no bowel movements since his drinking binge, denying any fevers, chills, or other symptoms. The patient admitted to smoking marijuana. On admission, the patient was normotensive but tachycardic. Labs were significant only for a white blood cell (WBC) count of 15.9. An abdominal radiograph revealed a large, cylindrical foreign body measuring approximately 25 cm projecting from the rectum to the left mid abdomen (Figure 2). The next day, the patient underwent an EUA as the FB could not be palpated by digital exam, even with manipulation on the abdomen. A colonoscopy revealed a black structure at 20 cm labeled "Samsung," but it was too large to snare or grasp. Overnight, the patient was noted to have increased pain, requiring IV pain medication, and a repeat abdominal X-ray revealed free air in the abdomen. He required an exploratory laparotomy, which revealed a 3 cm perforation of the descending colon with a foreign body protruding through the perforation. The foreign body was a remote-control device. The colonic segment containing the perforation was resected, and the proximal colon was then mobilized and brought out as an ostomy. The patient was admitted to the surgical intensive care unit (SICU), where he was extubated on postoperative day one and then transferred to the floor. He was eventually discharged but was lost to follow-up.

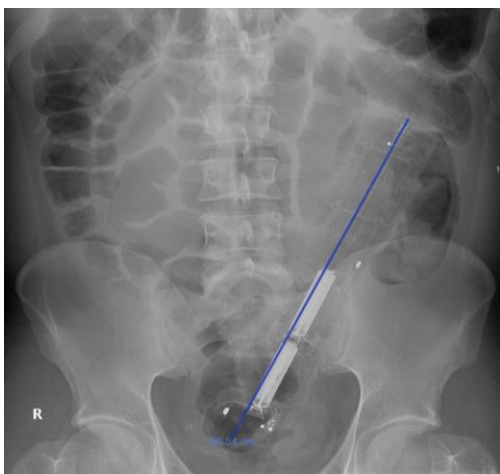


Figure 2: Abdominal radiograph revealing the retained remote control device.

Patient 4

A 61-year-old female with a past medical history of end-stage renal disease (ESRD) on hemodialysis, diabetes mellitus type 2 with neuropathy, iron deficiency anemia, multivitamin deficiency, and pressure ulcers with a catheter placement for long-term dialysis. The patient came into the ED for an infected hemodialysis catheter, and her hospital course was complicated by sepsis requiring vasopressors. A CT of the abdomen and pelvis revealed a nonspecific 2.1 cm foreign body in the rectum. The patient refused further evaluation of the rectal foreign body. The patient was stabilized and discharged without further evaluation.

Patient 5

A 72-year-old male with a past medical history of benign prostatic hypertrophy (BPH) presented to the ED with complaints of a foreign body, a prostate massager, in his rectum for the past two days. The patient denied abdominal pain, rectal pain, bleeding, or other symptoms. On physical exam, the abdomen was soft, nondistended, without tenderness, rebound, or guarding. An abdominal radiograph revealed an 11 cm radiopaque foreign body in the pelvis (Figure 3).

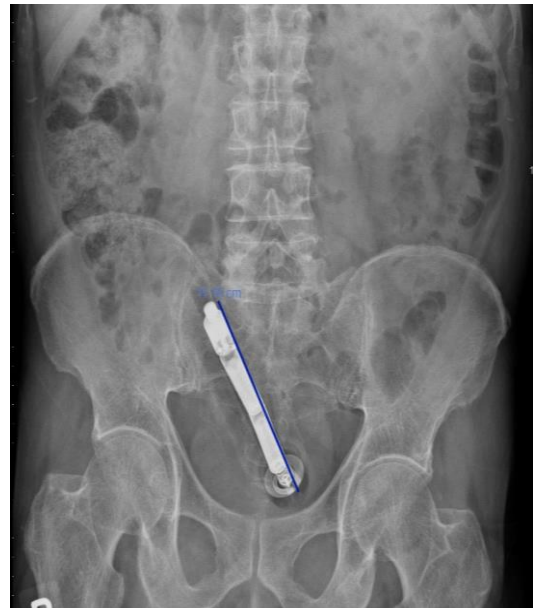

Figure 3: Abdominal radiograph showing an 11 cm radiopaque prostate massager in the pelvis.

The patient was admitted to surgical service. He underwent an EUA and a rectal FB removal in a prone position under spinal anesthesia. Anal dilation was completed using rectal retractors; the bottom of the elongated tubular foreign body was identified. Using gentle traction, the foreign body was removed intact (Figure 4). There was no bleeding or perforation, and he was taken to the recovery room in stable condition. The patient was discharged a day later.

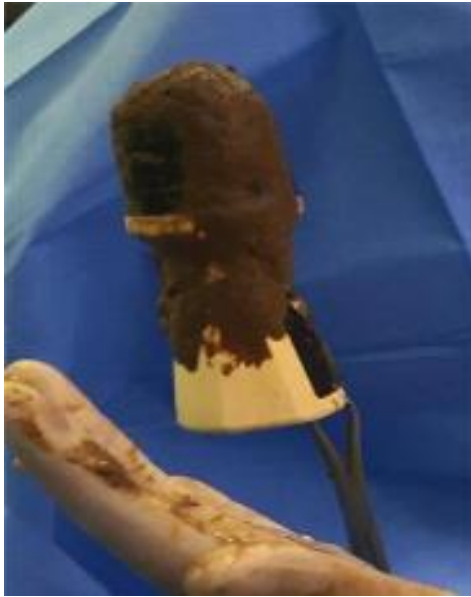

Figure 4: Picture of the prostate massager that was removed trans anally during EUA.

Patient 6

A 35-year-old male presented with a foreign body in the rectum and associated abdominal pain. The patient had inserted an aluminum bullet-shaped sex toy in his rectum five days prior that he was unable to remove as it continued to vibrate. On the physical exam, the abdomen was soft, without distension, tenderness, palpable mass, or guarding. There was no object palpated on the rectal exam. He was given polyethylene glycol and underwent a contrast CT of the abdomen after plain radiographs were inconclusive. The CT scan was done with oral contrast, precluding the foreign body's location. The patient refused to wait for repeated studies and requested to leave against medical advice (AMA). He was discharged with instructions to follow up in the surgery clinic in 3-5 days. The patient was lost to follow-up.

Patient 7

The patient is a 52-year-old male presenting with a foreign body in the rectum for 17 hours. The patient states that he has inserted a phallic rubber sex toy in the rectum. The physical exam was unremarkable, apart from the rectal exam that showed a soft, rubbery foreign body palpable at the pelvic inlet. The patient was sent for an abdominal X-ray; however, since the foreign body could not be visualized, a follow-up CT scan was ordered, showing an iso-dense filling of the rectum (Figure 5). The patient was admitted and scheduled for an EUA. With the patient sedated and paralyzed, the anus was dilated and examined circumferentially, and the foreign body was palpated approximately 10 cm from the anal verge. It was grasped and slowly “milked out” of the rectum using two fingers and a ringed forceps clamp. There was no bleeding, and no other anorectal pathology was appreciated. The morning

after the procedure, the patient had no pain and was surgically cleared to be discharged home.

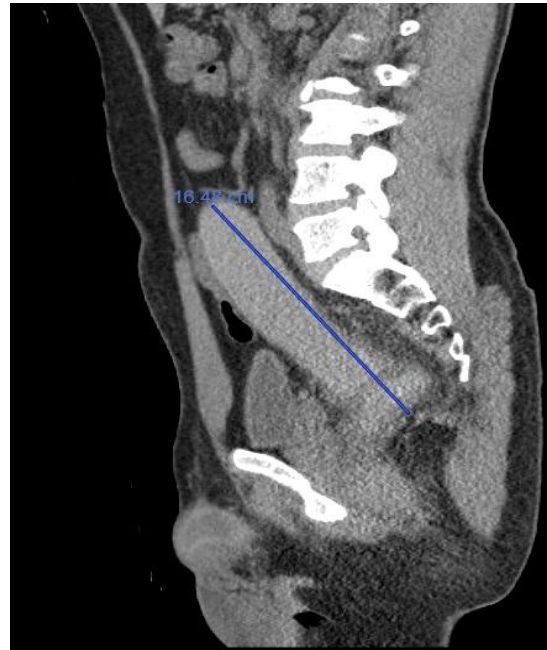


Figure 5: Sagittal CT scan visualizing a retained rubber sex toy after the failure of visualization on plain radiograph.

Patient 8

A 36-year-old man with a past medical history of hepatitis C and polysubstance abuse on methadone was brought in by police from the local international airport. In the airport, the patient had a 30-second seizure and vomited 5 pellets, one of which ruptured. The patient admitted to ingesting 50 tabs of cocaine and inserted ten rectally. He had a second tonic-clonic seizure at the airport and was brought into the hospital. Upon presentation, the patient was hypertensive, tachycardic, and diaphoretic. He had multiple seizures and was intubated for airway protection and placed on levetiracetam. A CT of the head was negative, and an electroencephelography (EEG) showed no seizure activity. A CT scan of the abdomen and pelvis showed multiple pellets in the stomach and the sigmoid colon. The patient was admitted to the medical ICU and given polyethylene glycol and activated charcoal through a nasogastric tube. On day two, a rectal exam revealed three additional packets in the rectum, and the patient was extubated and downgraded to telemetry. On day 3, a rapid response was called in telemetry for ventricular tachycardia; a repeat EKG showed normal sinus rhythm and nonspecific ST-T wave changes. On the same day, the patient became restless, with worsening tachycardia, hypertension, and tonic-clonic seizures; he was re-intubated. Etomidate and propofol were given, causing the resolution of the seizures. A repeat CTAP was ordered, revealing multiple radiopaque foreign bodies throughout the gastrointestinal tract, with hyperdense material in the

colon thought to be secondary to the rupture of some of the packets (Figure 6).

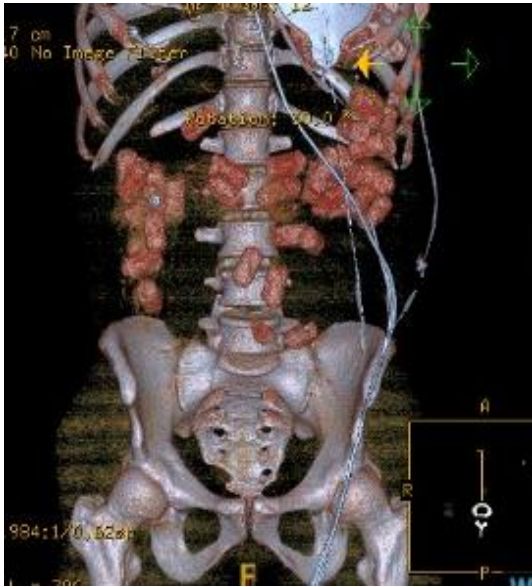

Figure 6: Three-dimensional reconstruction images of the drug packets visualized on a CT scan of the abdomen and pelvis.

The patient underwent exploratory laparotomy with findings of multiple packs in the stomach, colon, small bowel, and ascending colon. Segmental resection of the terminal ileum and ascending colon containing all the packs and balls of wrapping materials to avoid cross-contamination of the abdominal cavity was done. Afterward, the patient was extubated and downgraded to the floor and remained on seizure prophylaxis. The patient was discharged into police custody after a twelve-day hospital stay.

DISCUSSION

The annual incidence of presentations for rectal FB increased from 1.2 in 2012 to 1.9 per 100,000 persons in 2021.¹ Males have a bimodal age distribution peaking in the 5th decade, while females have a right-skewed age distribution peaking in the 2nd decade.² In a 2021 Malaysian case series of 5 patients, all were male with a bimodal distribution age in the 2nd and 6th decade.³ Our patients had a mean age of 47 years, predominantly male (75%) and Hispanic (75%).

The type of object inserted varies widely but often includes sexual devices, bottles, caps, jars, drugs/paraphernalia, cans, writing tools, balls, fruits, and vegetables.² FB are most commonly inserted but may be ingested, pass through the entire gastrointestinal tract, and get lodged in the rectum.⁴ In a review of 291 cases, Zhang et al found 68.4% were ingested, and 29.9% were self-inserted, mainly located in the distal rectum or anal canal.¹ Rectal FB can be categorized as voluntary versus involuntary and sexual versus nonsexual; an epidemiological study of FB

showed that 55.4% of FB were sexual devices.² In contrast, sexual devices comprised 37.5% of inserted FB in our sample group. Sexual gratification, psychiatric illness, loneliness, and isolation have been cited as motivations for rectal FB insert.⁵

Timing from insertion to removal is often prolonged due to patients' hesitation to seek help and to be forthcoming during the initial encounter due to embarrassment. Studies have shown the mean interval from insertion to initial presentation for assistance can range from 10 hours to 23 hours; we found a much longer interval in our sample's median time from incident to ED at 2.5 days.^{4,6} This is significant because delayed removal is associated with an increased risk of perforation, extended inpatient hospital stay, surgery risk and increased morbidity, mortality, and financial burden, especially if the time to presentation is longer than two days.^{7,8} This was the case for one of the patients in our sample who presented to the ED three days after insertion and throughout the hospital course, who had a perforation of the gastrointestinal tract and underwent an exploratory laparotomy with the need for a colostomy; the length of stay came to 12 days.

The seasonality and time of presentation of the retained FB can be a clinical clue, with the most diagnoses occurring in July, August, September, and October, with October having the highest frequency.^{9,10} This could reflect how changing seasons, day length, climate, sleep patterns, or reduced sexual activity can affect patient behavior.¹⁰ We had one patient present in July, two in August, and none in October, and these comprised two of the three patients who had inserted sexual devices. Interestingly, we noted in our sample that 75% of ED visits occurred between 7:00 pm and 8:00 am EST during the night shift. We hypothesize that this is an attempt to encounter fewer hospital staff. Most studies report the presenting time of the year and the associated factors, but we have yet to find studies evaluating the time of day and the day of the week patients present with rectal FBs. This is important because there are fewer hospital staff, especially surgical staff, at night. Thus, maintaining vigilance during this time can aid in timely diagnosis and prevent unnecessary investigations.

Diagnosis of retained rectal FBs starts with a detailed patient history and physical exam. Information from the patient regarding object description, timing, and history of prior trauma or previous removal attempts is valuable. However, preliminary studies have reported that only 10% to 30% of patients provide an accurate history, citing accident or assault rather than intentional insertion.⁴ This contrasts with our patient population, where 75% of our patients were forthcoming about inserting the foreign body. However, the patients who presented with retained drug packets were brought in by authorities after being discovered at John F. Kennedy Airport (JFK). The chief complaint may include abdominal pain, anorectal pain, change in bowel movements, and leakage of blood or mucus per rectum, and physical findings of severe abdominal or pelvic pain, fever, and hypotension should

raise concern for perforation.⁴ 62.5% presented without symptoms other than concern for a rectal foreign body, 25% of our patients presented with abdominal pain, 12.5% presented with rectal bleeding, and 12.5% presented with a witnessed seizure and vomiting secondary to cocaine intoxication from perforated drug packets.

Imaging must be obtained to characterize FBs for anatomical location and any associated complications. The primary diagnostic modality for retained rectal FBs consists of imaging studies starting with flat and upright radiographs of the abdomen and pelvis to determine size, shape, and location; this was the case for the identification of most of the foreign bodies, except the unidentified mass that patient 4 chose to refuse evaluation. An erect chest x-ray can help identify perforation with free air under the diaphragm.⁴ Indications for a CT scan include radiolucent FBs such as fruits or vegetables, high location, concern for perforation, abscess, and small bowel obstruction.¹¹ A CT was obtained to identify the anatomical location of the rubber sex toy, as it was not adequately visualized on plain radiography (Figure 5). In addition, a CT scan was used to evaluate the FB's anatomical location further. Failure to note the FB on radiography does not rule out FB, in which case sigmoidoscopy may be helpful for confirmation of a rectal FB.⁴ Biplanar plain radiographs of the abdomen and pelvis delineated the FB in three of our patients, the rest requiring a CT scan to aid in anatomical location and evaluating complications associated with the FBs.

Many factors and considerations must be made to facilitate the removal of retained rectal foreign objects depending on the object's physical properties. In the absence of mechanical bowel obstruction, firm and spherical objects possessing physical properties amenable to spontaneous passage may benefit from an early trial of strong laxatives.¹² Similarly, from our patient sample, we had one patient pass 16 heroin packets in the ED with the help of a magnesium citrate laxative. Retained FBs can migrate proximally towards the rectum; consequently, the colonic lumen may create a vacuum seal, preventing simple removal. In addition, presentation delays are common, so resultant mucosal edema can make removal more difficult.¹³ Furthermore, the object can lead to anteflexion of the rectum, creating an intrarectal suction effect, especially with glass or bottles, making extraction impossible period. If FB is of small diameter and a suction effect is absent, fleet enema or oral cathartics such as magnesium sulfate may be used; however, there is a risk of bleeding, further body impaction, and bowel perforation.^{8,12} For these cases, it is recommended to sedate the patient and place them in bed to allow for peristalsis to descend the FB, usually within 12 hours.⁸ FB retained for more than two days and those that are thicker, longer, and greater than 10 cm in size, sharp, and glass, present a significant challenge to the operator during removal. Various techniques can be used depending on the size and substance of the object of interest, and some approaches may be more beneficial than others.¹⁴

Among our patient samples, EUA to facilitate trans anal extraction and maximum dilation had a 75% success rate, whereas digital manipulation with a clamp was used to extract the foreign body and further proctoscopy to evaluate for injuries or perforation. Most FB can be removed via trans anal digital manipulation or with standard techniques starting with analgesia, sedation, and anesthesia. However, manipulation of the rectum may cause the mucosa to become edematous, leading to sphincter spasms and bowel atony, limiting further manipulation and extraction attempts.¹² Comparable to our outcomes, studies show a 60% to 70% successful removal rate via the trans anal approach, with all patients requiring general anesthesia in the OR.¹⁵ On the other hand, migration into the sigmoid colon presents more significant challenges, as the physical distance and acute angulation of the rectosigmoid junction restrict the effectiveness of straight surgical instruments.¹²

Sedation in the lithotomy position and sphincter dilation is recommended for extraction, with or without devices such as a proctoscope or sigmoidoscope for direct vision to minimize iatrogenic injuries. Forceps, rubber-lined blades, vaginal spatulas, wire and plastic snakes, rubber-covered clamps, and polyp snares have been used. For glass FBs, a foley catheter may be passed around the object, and air may be introduced to interrupt luminal suction and facilitate trans anal extraction. Furthermore, posterior sphincterotomy to remove larger objects has been proposed but should be avoided since the sphincter mechanism is at risk of permanent damage.⁸ Trans anal minimally invasive surgery (TAMIS) uses a pneumonectomy through insufflation to distend colonic walls and break the vacuum and can be considered before laparotomy in cases of failed trans anal extraction.¹³ Koornstra et al described using a new technique of removal, a pneumatic dilatation balloon for removing a retained tanning spray to overcome the suction effect.¹⁶ In our sample, a can of men's hairspray was successfully extracted from the rectum using a Kocher clamp, and anal dilation was augmented using retractors.

Anesthesia is crucial for pain control and patient comfort; furthermore, it facilitates the maximal dilation of the sphincter muscles to aid extraction. In a 10-year single hospital center case series from of 20 retained foreign bodies, 18 patients had successful manual removal in the ED without anesthesia, 2 of which received intravenous pain control; two patients required general anesthesia and removal in the operating room; two patients required laparotomy for vacuum seal and sigmoid perforation.¹⁷ In our series, 37.5% required general anesthesia, 25% required regional anesthesia, and 37.5% required no anesthesia.

Some cases of retained FB may require hospitalization, mainly due to complications. Female sex, balls, marbles, or drugs/paraphernalia are associated with reduced odds of hospitalization in the United States.² However, for patients with rectal FB who required inpatient admission, inpatient

females have higher rates of perforation and peritonitis (12.8% versus 5.2%), and sepsis (4% versus 1%) and even in-hospital death (4.8% versus 0.4%) compared to inpatient male counterparts.¹⁷ Patients aged 38 years or older were more likely to be hospitalized than younger patients aged less than 27 years.⁹ Especially since the median age of our patients was 47, it is essential to maintain a high index of suspicion as these patients are at a greater risk of serious complications. A study showed that 71.1% of patients with retained rectal FB were successfully treated and released without admission or transfer, 22.4% were admitted, and 2% left the ED without treatment.⁹ In our sample, only one of our patients was treated in the ED. The median hospital length of stay of admitted patients varies from 24 hours post-removal to 17 days post-extraction. Complications include tearing, bleeding, and ischemia of anal sphincters and rectal mucosa.² Post-extraction complications include fecal incontinence, anorectal fistula formation, and stenosis. These can occur later, and sigmoidoscopy is recommended but not mandatory.¹²

When all attempts are unsuccessful, or perforation is a concern, an exploratory laparotomy is performed with surgeons using laparoscopy to access the object and push it distally into the rectum for trans anal removal; this is known as milking. If the distal milking of the object fails, a colotomy and removal of the FB are needed.⁶ A 2020 study found a 10% perforation rate comparable to our sample, which had a 12.5% perforation rate.⁴

One of our patients underwent exploratory laparotomy secondary to perforation discovered by pneumoperitoneum on abdominal X-ray. The foreign body was a remote-control device and was removed by resection of the perforated colon and a diverting colostomy.

CONCLUSION

Retained rectal FB introduced into a narrow lumen comes with a unique set of challenges due to the varied nature, potential migration into the sigmoid colon, and difficulty negotiating the acute angulation of the rectosigmoid junction. As objects vary in size, shape, depth of insertion, each case may require improvisation and creativity to remove the foreign body successfully. Outcomes range from residual rectal discomfort after a successful transanal extraction to perforation, peritonitis, and sepsis requiring an exploratory laparotomy, ICU admission, prolonged LOS, and long-term sequelae.

Funding: No funding sources

Conflict of interest: None declared

Ethical approval: Not required

REFERENCES

1. Zhang Y, Han Y, Xu H, Chen D, Gao H, Yuan H, Zeng X. A retrospective analysis of transanal surgical

- management of 291 cases with rectal foreign bodies. *Int J Colorectal Dis.* 2022;37(10):2167-72.
2. Loria A, Marianetti I, Cook CA, Melucci AD, Ghaffar A, Juviler P, et al. Epidemiology and healthcare utilization for rectal foreign bodies in United States adults, 2012-2021. *Am J Emerg Med.* 2023;69:76-82.
3. Pang WS, Tan JH, Tan HCL, Tan JKG. Case series of retained rectal foreign body. A Malaysian experience. *Malays Fam Physician.* 2021;16(2):78-82.
4. Kim JH, Um E, Jung SM, Shin YC, Jung SW, Kim JI, et al. The Management of Retained Rectal Foreign Body. *Ann Coloproctol.* 2020;36(5):335-43.
5. Lovisetto F, Guala A, Facciotto G, Zonta S. COVID-19 and psychiatric illness: rectal foreign bodies (30 stylus batteries) in a young male patient affected by Asperger syndrome. *J Surg Case Rep.* 2020;2020(10):rjaa345.
6. Coskun A, Erkan N, Yakan S, Yildirim M, Cengiz F. Management of rectal foreign bodies. *World J Emerg Surg.* 2013;8(1):11.
7. Frendt E, Masroor M, Saied A, Neeki A, Youssoffi S, Malkoc A, et al. Characteristics and Outcomes Associated With Emergent Rectal Foreign Body Management: A Retrospective Cohort Analysis. *Cureus.* 2023;15(11):e49413.
8. Ploner M, Gardetto A, Ploner F, Scharl M, Shoap S, Bäcker HC. Foreign rectal body - Systematic review and meta-analysis. *Acta Gastro-Enterologica Belgica.* 2020;83(1):61-5.
9. Sheets NW, Waldrop I, Carpenter WC, Dubina E, Kondal B, Schultz H, et al. Rectal Foreign Bodies: A 10-Year Review of the National Electronic Injury Surveillance System. *Cureus.* 2023;15(7):e41471.
10. Pathak R, Karmacharya P, Alweis RL. Seasonal Variation of Rectal Foreign Bodies: Data from Nationwide Inpatient Sample. *North Am J Med Sci.* 2016;8(4):191-3.
11. Pinto A, Miele V, Pinto F, Mizio VD, Panico MR, Muzj C, et al. Rectal foreign bodies: Imaging assessment and medicolegal aspects. *Semin Ultrasound CT MR.* 2015;36(1):88-93.
12. Grantham JP, Hii A, Bright T, Liu D. Successful Expulsion of a Golf Ball from the Sigmoid Colon Using Volume Laxatives. *Case Rep Surg.* 2023;2023:5841246.
13. Zhao B, Roper MT, Tomassi MJ, Wenger SJ, Klaristenfeld D. Techniques for the extraction of high rectal foreign bodies by transanal minimally invasive surgery. *Tech Coloproctol.* 2021;25(3):339-42.
14. Sajjad H, Paish LM. *Rectum Foreign Body Removal.* Treasure Island (FL): StatPearls Publishing. 2023.
15. Ologun G O, Stevenson Y, Cagir B. Successful Retrieval of a Retained Rectal Foreign Body in the Emergency Department. *Cureus.* 2018;10(1):e2025.
16. Koornstra JJ, Weersma RK. Management of rectal foreign bodies: Description of a new technique and

clinical practice guidelines. *World J Gastroenterol.* 2008;14(27):4403-6.

17. Odagiri H, Yasunaga H, Matsui H, Fushimi K, Iizuka T, Kaise M. Difference in Outcomes of Rectal Foreign Bodies between Males and Females: A Retrospective Analysis of a National Inpatient Database in Japan. *Digestion.* 2015;92(3):165-70.

Cite this article as: Tian J, Kiarie P, Olang C, Sneed C, Fernandez L, Miele A, et al. Better out than in: a case series of retained rectal foreign bodies in a New York Community Hospital. *Int Surg J* 2024;11:953-60.