

## Original Research Article

# Double faced buccal mucosal graft urethroplasty for near obliterative inflammatory urethral stricture: a retrospective study comparing two different techniques

Manu K. Nagabhairava, Tarun Javali, Dokania Kanishk, Manasa Thimmegowda\*,  
Ameya R. Sangle, Amit Patil

Department of Urology, M.S. Ramaiah Medical College, Bengaluru, Karnataka, India

**Received:** 26 March 2024

**Revised:** 29 March 2024

**Accepted:** 30 March 2024

### \*Correspondence:

Dr. Manasa Thimmegowda,

E-mail: [manasat7@gmail.com](mailto:manasat7@gmail.com)

**Copyright:** © the author(s), publisher and licensee Medip Academy. This is an open-access article distributed under the terms of the Creative Commons Attribution Non-Commercial License, which permits unrestricted non-commercial use, distribution, and reproduction in any medium, provided the original work is properly cited.

## ABSTRACT

**Background:** Double-faced urethroplasty offers improved outcomes for the management of complex urethral strictures. In our study, we compared two different techniques of double faced buccal mucosal graft (BMG) urethroplasty.

**Methods:** 46 patients who underwent double faced BMG urethroplasty at Ramaiah Medical College were retrospectively reviewed and grouped into A (Enzo Palminteri technique) and B (Joel Gelman technique). Post operatively, patients were followed up with AUA-SS, uroflowmetry and postvoid residual assessment. The data analysis was done using the statistical package for the social sciences (SPSS) version 21.0. A  $p < 0.05$  was considered statistically significant.

**Results:** 24 patients belonged to group A and 22 patients belonged to group B. The mean stricture length measured was  $4.42 \pm 1.632$  cm in group A and  $4.11 \pm 1.634$  cm in group B with the preoperative mean  $Q_{max}$  and AUA score was  $7 \pm 1.318$  ml/s and  $19.75 \pm 3.286$  in group A and  $7.3 \pm 1.497$  ml/s and  $18.68 \pm 3.469$  in group B. Mean operative time was  $162.7 \pm 12.156$  minutes versus  $181.36 \pm 7.429$  minutes. Group A patients had significant intraoperative blood loss. Recurrence was noted in two patients, one from each group. Mean  $Q_{max}$  and mean AUA score at recent follow up was  $19.3 \pm 1.63$  ml/s and  $6.4 \pm 2.10$  versus  $19.8 \pm 1.59$  ml/s and  $6.6 \pm 2.03$  for group A and group B with a mean follow up of  $36.6 \pm 12.63$  months and  $36.8 \pm 11.48$  months respectively.

**Conclusions:** Double faced BMG urethroplasty for near obliterative urethral stricture is safe, efficacious with ventral onlay associated with lesser operative time.

**Keywords:** Buccal mucosal graft urethroplasty, Enzo palminteri, Joel Gelman technique

## INTRODUCTION

Plethora of options are available for surgical repair of stricture urethra. The plan of treatment is based on the stricture site, number, length and the degree of spongiofibrosis associated. Excision and primary anastomosis is conventionally used for Bulbar urethral strictures of 1-2 cm length with good long-term results.<sup>1-4</sup> Strictures  $> 2$  cm, multiple strictures require a substitution urethroplasty with a free graft. Currently buccal mucosa

graft (BMG) is the most popular choice for substitution urethroplasty, with a high success rate approaching 92%.<sup>3,5</sup> BMG urethroplasty can involve placement of a graft either dorsal/ventral in an onlay or inlay fashion with all of them producing equally good results.<sup>6-10</sup>

In patients with near obliterative strictures (defined in this study as urethral caliber less than 6 Fr), the management involves either a two stage urethroplasty or single stage with buccal mucosa, albeit with poorer results.<sup>8-10</sup> Recently

Palminteri et al and Gelman et al have described a double faced buccal mucosal graft urethroplasty with different configurations with regard to graft placement and have reported a success rate of 89.6% and 94% respectively.

We at our institute have adopted this technique for the management of near obliterative urethral strictures in order to improve our desired results. The reason for this paradigm shift in management has been based on the hypothesis that “Urethral strictures are circumferential and not restricted to one wall of the urethra.” Hence, substituting just one wall of the urethral mucosa with buccal mucosa especially in near obliterative strictures, may lead to poorer outcomes as evidenced by the high attrition rate of 31.6% as noted in previous studies.<sup>11</sup> Therefore our study was aimed at comparing the two different techniques of double faced buccal mucosal graft urethroplasty including their perioperative outcomes.

## METHODS

This study was a retrospective analysis from our urethroplasty database and was undertaken in our hospital after obtaining institutional ethical committee clearance. Between August 2010 and October 2015, all 255 patients who underwent buccal mucosal urethroplasty at Department of Urology, Ramaiah Medical College were retrospectively reviewed. 46/255 patients with near obliterative bulbar urethral stricture of >2 cm length who underwent a patch urethroplasty, using a dorsal plus a ventral double BMG were included in this study. All anterior urethral strictures <2 cm, prior urethroplasty and patients with contraindications for buccal mucosal graft were excluded from the study. These patients were further divided into two groups based on the operative technique used. Group A (n=24) included patients who underwent Enzo Palminteri technique (dorsal inlay with ventral onlay) in which, the stenotic urethral segment was opened along its ventral surface; the exposed dorsal urethra was incised in the midline to create an elliptical area over the tunica albuginea where the dorsal inlay BMG was placed and quilted to the corpora to augment dorsally the urethral plate. Subsequently, the ventral onlay BMG was sutured to the urethral lateral margins to complete the augmented urethroplasty. Finally, the spongiosum was closed over the graft.

Group B (n=22) underwent Joel Gelman technique (dorsal onlay with ventral inlay) in which, the mobilized corpus spongiosum was incised dorsally without transection, thereby preserving the continuity of the blood supply within the spongy tissue. Buccal mucosa was quilted to the corporal bodies to reconstruct the dorsal aspect of the urethra. Additional buccal mucosa was quilted to the dorsally incised, non transected corpus spongiosum in continuity with the distally and proximally spatulated urethra. The repair was then completed by approximating dorsal and ventral buccal mucosal graft segments.

All relevant data pertaining to preoperative evaluation were collected which included a detailed clinical history and physical examination, urine culture, serum creatinine, uroflowmetry, ultrasound of kidney-ureter bladder with post void residual urine, retrograde urethrography, sonourethrogram, and urethroscopy findings with a 6/7.5 Fr semi-rigid ureteroscope. All the surgeries were performed by a single surgeon.

The surgical technique for urethroplasty was based on intraoperative findings (tissue planes and ease of dissection) as well as surgeon preference. The buccal mucosa graft was harvested from the cheek using a two team approach. The donor site was closed with 3-0 polyglactin. Grafts were taken from both the cheeks and lingual grafts were not used in any patients. All 46 patients received perioperative antibiotics in form of intravenous third generation cephalosporin and aminoglycosides at induction of anaesthesia and for two postoperative days, followed by oral cephalosporin till catheter removal. In all the patients catheter was removed at 21 days after performing peri-catheter dye study was performed to rule out extravasation. Follow up protocol consisted of uroflowmetry and postvoid residual assessment and American Urological Association symptom score (AUA-SS), every 4 months for the first 2 years and then 6 monthly thereafter. Retrograde urethrography and urethroscopy was performed if a restructure was suspected based on the obstructive symptoms, deterioration of flow rate or AUA-SS score or increase in postvoid residual volumes. Successful reconstruction was defined as normal voiding without the need for any postoperative procedure including dilation at all follow up. Failure was defined as requirement of any post procedure intervention like dilatation/VIU/ redouurethroplasty.

The data analysis was done using the statistical package for the social sciences (SPSS) version 21.0, (Inc., Armonk, NY, USA). Categorical variables are presented as numbers and percentages and continuous variables are presented as mean (SD) and median. Normality of data was tested by the Kolmogorov–Smirnov test. If the normality was rejected, then a non-parametric test was used. A  $p < 0.05$  was considered statistically significant.

## RESULTS

Of 255 patients who underwent urethroplasty at our centre, 46 patients who had near obliterative stricture and underwent double faced BMG urethroplasty were included in the final analysis. Out of the 46 patients, 24 patients (group A) underwent dorsal inlay with ventral onlay BMG urethroplasty (Enzo Palminteri technique) and 22 patients (group B) underwent dorsal onlay with ventral inlay BMG urethroplasty (Joel Gelman technique). Mean age of patient was  $43.1 \pm 9.50$  years in group A and  $43.6 \pm 9.46$  years in group B. The aetiology of urethral stricture was an inflammatory cause in 19 and 17 patients for group A and group B respectively and iatrogenic in 5 patients for each of the groups. The mean stricture length measured was

4.42±1.632 cm (range: 2.5–5 cm) in group A and 4.11±1.634 cm in group B (range: 2.5–5 cm) with the mean number of dilatations prior to the BMG urethroplasty being 2±1.383 (range: 0-5) and 2.3±1.554 (range: 0-5) respectively. Uroflowmetry demonstrated a preoperative mean Q<sub>max</sub> of 7±1.318 ml/s and 7.3±1.497 ml/s respectively with a mean preoperative AUA-SS score being 19.75±3.286 and 18.68±3.469 respectively in a and b groups with no significant difference (Table 1).

However, significant difference was noted statistically in the mean operative time between the two groups with group A requiring 162.7±12.156 minutes (range: 155-200 minutes) and group B requiring 181.36±7.429 minutes (range: 165-200 minutes) (p<0.05). Group A patients had significant intraoperative blood loss as deduced by their fall in haemoglobin [1.79±1.009 mg/dl (range: 1.3-3.9) and 0.66±0.269 mg/dl (range: 0.4-1.2 mg/dl) in group B] and increased need for blood transfusion during the post-operative period. Postoperative complications included wound infection in three patients (2 in group A and 1 in group B), and transient epididymo-orchitis in two patients (1 in group A and 1 in group B). All were grade 1 as per Clavien-Dindo classification and the difference was not significant statistically.<sup>12</sup> Two patients, one from each group had recurrent stricture and required a single session of VIU 2 years and 2.5 years after the surgery respectively, post which they remained symptom free till the end of their follow up period (Table 2).

The success rate was noted to be 95.8% and 95.4% for group A and B respectively, with a mean follow up of 36.6±12.63 months (range: 12–62 months) and 36.8±11.48

months (range: 12–62 months) for group A and group B respectively. Mean Q<sub>max</sub> and mean AUA score at last follow up was 19.3±1.63 ml/s and 6.4±2.10 versus 19.8±1.59 ml/s and 6.6±2.03 for group A and group B respectively.

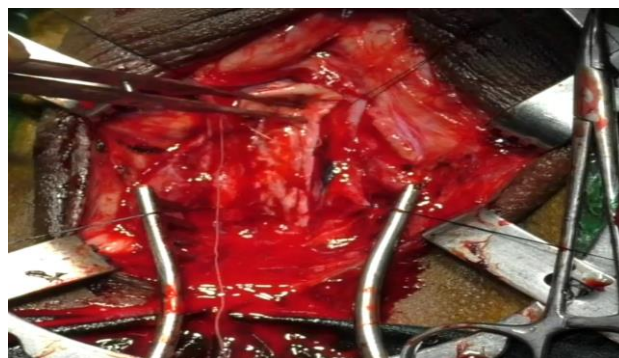


Figure 1: Dorsal inlay.

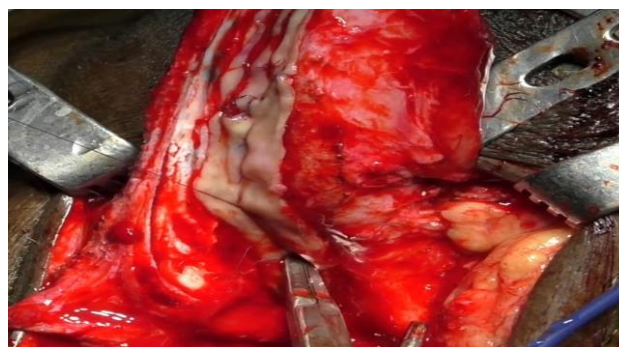

Figure 2: Ventral inlay.

Table 1: Demographic and clinical data across the study population (n=46).

Variables	Group A (n=24)	Group B (n=22)
Total no. of patients	36	34
Mean age in years	43.1±9.50 (range: 24–61)	43.6±9.46 (range: 28–62)
Mean no of prior treatment (dilatation/VIU)	2±1.383 (range: 0–5)	2.3±1.554 (range: 0–5)
Stricture length (cm)	4.42±1.632 (range: 2.5–5)	4.11±1.634 (range: 2.5–5)
Mean preoperative Q <sub>max</sub> (ml/s)	7±1.318	7.3±1.497
Mean preoperative AUA-SS	19.75±3.286	18.68±3.469

Table 2: Clinical characteristics across the study population (n=46).

Variables	Group A (n=24)	Group B (n=22)
Total no of patients with complications	3	2
Wound infection	2	1
Transient epididymo-orchitis	1	1
Mean operative time (in minutes)	162.7±12.156 (range: 155–200)	181.36±7.429 (range: 165–200)
Total no of patients who required blood transfusion	1	0
Mean fall in haemoglobin level (mg/dl)	1.79±1.009 (range: 1.3–3.9)	0.66±0.269 (range: 0.4–1.2)
Mean follow up (months)	36.6±12.634 (range: 12–62)	36.8±11.482 (range: 12–62)
Mean Q <sub>max</sub> at last follow up (ml/s)	19.3±1.636	19.8±1.592
Mean AUA-SS at last follow up	6.4±2.105	6.6±2.036
Success rate (%)	95.8	95.4



## DISCUSSION

In the past, variety of techniques have been described to manage near obliterative strictures of anterior urethra.<sup>8</sup> These techniques include substitution urethroplasty, augmented anastomotic urethroplasty, and staged repair. In substitution urethroplasty, only the strictured urethra is incised leaving behind the rest of the scar tissue which leads to high chances of failure and recurrence. Augmented urethroplasty is an alternative to overcome this problem as this procedure involves complete excision of disease segment but the limitation is that it can be performed for strictures of 2-5 cm only. Staged repair can be used for long segment strictures with excellent outcomes. Despite better outcomes patients prefer a single stage procedure owing to the morbidity associated with such a procedure.<sup>1-4</sup> In order to achieve better outcomes, improve the postoperative results and also decrease the morbidity associated with staged repair, double faced urethroplasty has been described to manage these complex urethral strictures.<sup>12</sup>

The two techniques described in literature for double face urethroplasty are Enzo Palminteri technique (dorsal inlay with ventral onlay) and Joel Gelman technique (dorsal onlay with ventral inlay).<sup>13,14</sup> In ventral approach the corpus spongiosum is incised longitudinally along the ventral aspect and also incised through the dorsal corpus spongiosum, graft is placed along the corporal bodies, add an additional graft is placed ventrally to complete the tubularization, and then cover the ventral buccal with corpus spongiosum. Mobilization of the corpus spongiosum is not required in the ventral approach giving it an advantage. Though dorsal approach requires mobilization of corpus spongiosum, it does not compromise vascularity as the existing dorsal and bulbar supply are preserved. A ventral approach may in fact compromise the blood flow within the spongy tissue when the dissection extends through both the ventral and dorsal corpus spongiosum, which is not seen in the dorsal approach.

Moreover, along the distal aspect of bulbar urethra and penile urethra, the corpus spongiosum is relatively less developed as compared to proximal bulbar urethra and less robust in the event of any atrophy or spongiobrosis. Hence the ability of the 2 halves of the incised corpus spongiosum to cover the graft may be limited with the ventral approach and when tissue is used to cover the ventral graft, it may provide a less reliable graft fixation than the quilting of the graft to the recipient bed. On the contrary, with the dorsal approach, the spongy tissue can be easily splayed to accommodate a graft of 10-14 mm width, and the remaining graft is tacked to the corpora with a width of 16-20 mm and above.

Despite the differences both techniques are associated with higher success rates. Palminteri et al reported has reported a success rate of 89.6% at an average follow up at 12 months.<sup>13</sup> Similarly, Gelman et al demonstrated a 94%

success rate in 18 patients using their technique even a follow up duration of 50 months.<sup>14</sup> Our study reproduces the same results while comparing both the techniques without a significant difference in their outcomes. Although the above mentioned techniques are slightly more complex as compared to the two stage or single stage urethroplasty with one sided graft, the surgery is well tolerated with a lower re-stricture rate and lesser morbidity.

### Limitations

A prospective randomised study with real time data is required for further validation of results. Further studies with larger cohorts should be investigated and compared.

## CONCLUSION

Double faced buccal mucosal graft urethroplasty for near obliterative urethral stricture is safe, efficacious, and well tolerated. The result of this study showed that both the techniques of double faced buccal mucosal urethroplasty are successful for management of near obliterative stricture. The ventral onlay technique however was associated with lesser operative time but increased blood loss in comparison to dorsal onlay technique.

### Recommendations

Double faced buccal mucosal graft urethroplasty should be the preferred surgical option in near obliterative urethral stricture. The Enzo Palminteri technique and the Joel Gelman technique have similar results. Double faced buccal mucosal graft urethroplasty is safe and efficacious with better treatment outcomes.

*Funding: No funding sources*

*Conflict of interest: None declared*

*Ethical approval: The study was approved by the Institutional Ethics Committee*

## REFERENCES

1. Santucci RA, Mario LA, McAninch JW. Anastomotic urethroplasty for bulbar urethral stricture: analysis of 168 patients. *J Urol.* 2002;167(4):1715-9.
2. Guralnick ML, Webster GD. The augmented anastomotic urethroplasty: indications and outcome in 29 patients. *J Urol.* 2001;165(5):1496-501.
3. Elliott SP, Metro MJ, McAninch JW. Long-term followup of the ventrally placed buccal mucosa onlay graft in bulbar urethral reconstruction. *J Urol.* 2003;169(5):1754-7.
4. Wessels H, McAninch JW. Use of free grafts in urethral stricture reconstruction. *J Urol.* 1996;155(6):1912-5.
5. Baskin LS, Duckett JW. Buccal mucosa grafts in hypospadias surgery. *Br J Urol.* 1995;76(3):23-30.
6. Barbagli G, Palminteri E, Rizzo M. Dorsal onlay graft urethroplasty using penile skin or buccal

- mucosa in adult bulbourethral strictures. *J Urol.* 1998;160(4):1307-9.
7. Pansadoro V, Emiliozzi P, Gaffi M, Scarpone P. Buccal mucosa urethroplasty for the treatment of bulbar urethral strictures. *J Urol.* 1999;161(5):1501-3.
  8. Morey AF, McAninch JW. When and how to use buccal mucosal grafts in adult bulbar urethroplasty. *Urology.* 1996;48(2):194-8.
  9. Kane CJ, Tarman GJ, Summerton DJ, Buchmann CE, Ward JF, O'Reilly KJ, et al. Multi-institutional experience with buccalmucosa onlay urethroplasty for bulbar urethral reconstruction. *J Urol.* 2002;167(3):1314-7.
  10. Barbagli G, Palminteri E, Guazzoni G, Montorsi F, Turini D, Lazzeri M. Bulbar urethroplasty using buccal mucosa grafts placed on the ventral, dorsal or lateral surface of the urethra: are results affected by the surgical technique? *J Urol.* 2005;174(3):955-8.
  11. Blaschko SD, McAninch JW, Myers JB, Schlomer BJ, Breyer BN. Repeat urethroplasty after failed urethral reconstruction: outcome analysis of 130 patients. *J Urol.* 2012;188(6):2260-4.
  12. Dindo D, Demartines N, Clavien PA. Classification of surgical complications: a new proposal with evaluation in a cohort of 6336 patients and results of a survey. *Ann Surg.* 2004;240(2):205-13.
  13. Palminteri E, Manzoni G, Mordondoni E, Di Fiore F, Testa G, Poluzzi M, et al. Combined dorsal plus ventral double buccal mucosa graft in bulbar urethral reconstruction. *Eur Urol.* 2008;53:81-90.
  14. Gelman J, Siegel JA. Ventral and Dorsal Buccal Grafting for 1-Stage Repair of Complex Anterior Urethral Strictures. *Urology.* 2014;83(6).

**Cite this article as:** Nagabhairava MK, Javali T, Kanishk D, Thimmegowda M, Sangle AR, Patil A. Double faced buccal mucosal graft urethroplasty for near obliterative inflammatory urethral stricture: a retrospective study comparing two different techniques. *Int Surg J* 2024;11:715-9.