

Case Report

Zinner syndrome in a case of male infertility: a case report

Rashika M.*, Vishal Jain, S. B. S. Netam, Ghanshyam Verma

Department of Radiodiagnosis, Pt. JNMMC and Dr. BRAM Hospital, Raipur, Chhattisgarh, India

Received: 28 February 2024

Revised: 28 March 2024

Accepted: 01 April 2024

*Correspondence:

Dr. Rashika M.,

E-mail: monyrashika2@gmail.com

Copyright: © the author(s), publisher and licensee Medip Academy. This is an open-access article distributed under the terms of the Creative Commons Attribution Non-Commercial License, which permits unrestricted non-commercial use, distribution, and reproduction in any medium, provided the original work is properly cited.

ABSTRACT

Zinner syndrome is a rare congenital malformation formed by the developmental anomaly of distal portion of the wolffian duct. It is an unusual cause of infertility and dysuria among young males. It is associated with ipsilateral renal agenesis, seminal vesical cyst, and ejaculatory duct obstruction. We herein report a rare case of a Zinner syndrome, in a patient of primary infertility. He also presented with complaints of chronic pelvic pain and dysuria. Any young patients of male infertility or unspecified pelvic complaints should be evaluated for Zinner syndrome and surgical intervention is the mainstay treatment for symptomatic patients.

Keywords: Zinner syndrome, Seminal vesical cyst, Unilateral renal agenesis, Infertility, Magnetic resonance imaging

INTRODUCTION

Zinner syndrome is a rare congenital malformation of the urogenital system which occurs during early embryogenesis affecting the distal portion of the mesonephric duct. The incidence of Zinner syndrome is 1 in 3000 to 1 in 4000 newborns. This is considered to be the counterpart of Mayer-Rokitansky-Kuster-Hauser (MRKH) in males.¹

Seminal vesicle cysts were first described by Smith in 1872 and the association of congenital seminal vesicle cysts with unilateral renal agenesis was first reported by Zinner in 1914 and was therefore termed Zinner syndrome. The prevalence of Zinner syndrome is found to be 0.0001%.²

It comprises of unilateral renal agenesis, ipsilateral seminal vesicle cyst, and ipsilateral ejaculatory duct obstruction. It manifests usually in the form of voiding difficulties such as dysuria, prostatism, urgency, painful ejaculation, hematospermia, perineal pain/discomfort, and can lead to serious complications, particularly infertility.³

It is often diagnosed in the second and third decades of life when the person is sexually active. The clinical presentation is non-specific; thus, majority of patients remain asymptomatic until beginning sexual activity.^{2,3}

CASE REPORT

A 35 years-old male, presenting with complaints of infertility came to the department of Radiodiagnosis of Dr. BRAM. Hospital, Raipur.

The physical examination, routine blood tests and hormonal assay were normal.

On urine microscopic examination, few red blood cells 5-10/hpf noted and other urine laboratory examinations were normal.

On semen analysis, low ejaculate of volume 1 ml and sperm count of 5,00,000/ml with presence of red blood cells (15-20/hpf) in the ejaculate noted.

On abdominal and pelvic computed tomography (CT), there is absence of right kidney with a right sided retro-

vesical well-defined round to oval shaped hypodense cystic lesion with dilated tubular structures showing no contrast enhancement, s/o seminal vesical cyst with ejaculatory duct obstruction (Figure 1).

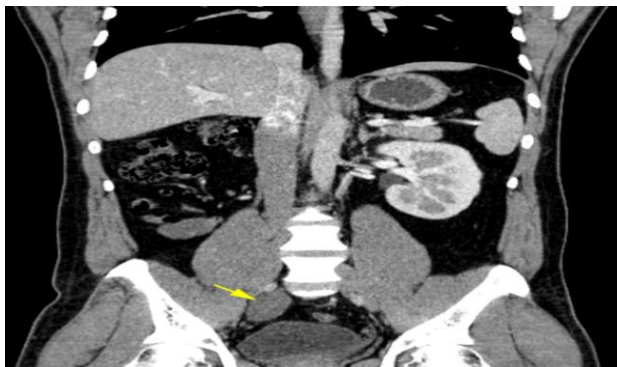

Figure 1: CECT image showing agenesis of right kidney. A well-defined round to oval shaped non-enhancing hypodense lesion noted in the pelvis, s/o seminal vesical cyst (yellow arrow).

On pelvic magnetic resonance imaging (MRI), there is a well-defined round to oval shaped cystic lesion communicating with cystic tubular structure noted in the retro-vesical region on the right side showing T1 hyperintensity, T2/STIR hyperintensity with T2 shading sign. The left seminal vesicle did not show any abnormality. Above features suggestive of right sided seminal vesical cyst along with ipsilateral unilateral ejaculatory duct obstruction, representing Zinner syndrome (Figures 2 and 3).

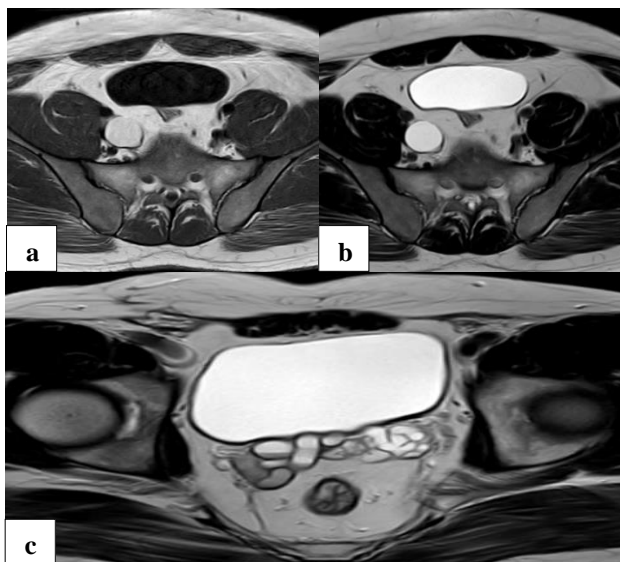


Figure 2 (a and b): MRI axial images showing a well-defined round to oval shaped T1 hyperintense, T2 hyperintense lesion with fluid-fluid level in the pelvis posterior to the bladder, s/o seminal vesical cyst; and (c) MRI coronal image showing dilated tubular structure showing T2 hyperintensity with fluid-fluid level (T2 shading sign), s/o dilated ejaculatory duct.

The patient underwent seminal vesical cyst excision. He was asymptomatic during the follow-up periods.

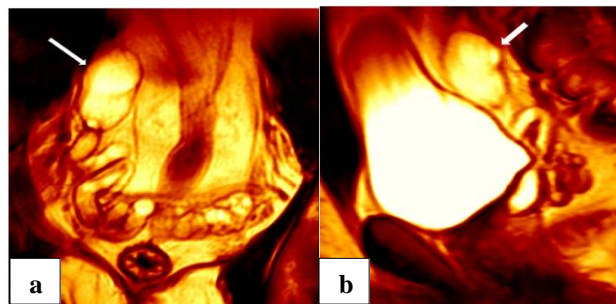


Figure 3 (a and b): Reconstructed MRI images in coronal and sagittal section showing seminal vesical cyst (white arrow) communicating with the dilated obstructed ejaculatory duct.

DISCUSSION

The causes of male infertility are multifactorial such as metabolic disorder, systemic illness, post-traumatic/intervention, infection, genetic disorder, neoplasm, torsion, and last but not the least congenital abnormalities. The congenital causes of male infertility are cryptorchidism, hypospadias, ambiguous genitalia, and congenital anomalies of the kidney and urinary tract.⁴

In utero, the developing fetus is usually ambisexual, and the development of genitourinary system begins at around the first trimester of gestation in response to the gonadal hormones. The urogenital system arises from intermediate mesoderm which forms a urogenital ridge on both the sides of aorta. The intermediate mesoderm forms the pronephros, mesonephros and metanephros. In this, the organs of urogenital system are derived from the mesonephric/wolffian duct and mesonephric tubules. The mesonephric duct develops into seminal vesicle, ductus deference and epididymis, whereas the mesonephric tubules form the efferent ductules. The most distal part of the wolffian duct forms an outgrowth called ureteric bud. This structure will finally meet and induce the transformation of the metanephric blastema into adult kidney.⁵

Maldevelopment of the distal mesonephric duct along with abnormal ureteral budding leads to the atresia of the ejaculatory duct causing consequent obstruction and cystic dilatation of the seminal vesicles along with ipsilateral renal agenesis or dysgenesis. Thus, there is an association between congenital malformations of the seminal vesicle and the ipsilateral upper urinary tract and these are collectively known as Zinner syndrome.⁶

It is defined as the triad of a seminal vesicle cyst, ejaculatory duct obstruction and ipsilateral renal agenesis. It can be associated with absent or incomplete ipsilateral ureter or may have an abnormal course towards the seminal vesicle. It is commonly found on the right side,

with a right to left side ratio of 2: 1 but can also be seen bilaterally in only 2% of cases. In only 4 cases of seminal vesicle cysts, contralateral renal agenesis is reported.⁷

It also includes other abnormalities like polycystic renal disorders, ipsilateral testicular agenesis, atresia of the vas deferens and hemivertebra. In some rare conditions, ureteric bud remnant may be associated with Zinner syndrome which happens in some metanephric mesenchyme development disorder. In many cases, ureteric bud remnant coexists and may open into seminal vesicle cyst.^{6,7}

Imaging modality for diagnosis and surgical planning is MRI which is considered as the “gold standard”. It helps in better characterization of the cyst content (hemorrhage and a high proteinaceous concentration of the seminal fluid) and precise localization of it. It can be also detected

in CT scan, but it may be insufficient to confirm the diagnosis.^{8,9}

The seminal vesicle cyst is classified into 4 types based on the size, calcification, density, wall thickness and nodule or solid mass within the cyst and managed accordingly (Table 1). Asymptomatic cysts such as type I and II cysts are usually treated with conservative therapy or periodic follow-ups. Surgical intervention is needed when they are symptomatic causing unspecific pelvic complaints or infertility. The treatment methods include the transrectal or trans-perineal aspiration drainage of the cyst, recanalization of the vas deferens with the resection of the cyst, unroofing of transurethral cyst, laparoscopic surgery and open surgical excision. The type I-III cysts can be treated in laparoscopic approach whereas type IV cysts require an open surgical excision.⁹⁻¹¹

Table 1: Classification of seminal vesicle cyst.⁹

Parameters	Type I	Type II	Type III	Type IV
Density	Homogenous in density/signal. On CT: <20 HU value; on MRI: T1 hypointensity and T2 hyperintensity	Heterogenous in density/signal. On CT: >20 HU value; on MRI: T1 hyperintensity and T2 hyperintensity. Fluid levels can also be seen.	Heterogenous in density/signal. On CT: >20 HU value; on MRI: T1 hyperintensity and T2 hyperintensity. Fluid levels can also be seen.	Heterogenous in density/signal. On CT: >20 HU value; on MRI: T1 hyperintensity and T2 hyperintensity. Fluid levels can also be seen.
Wall	Thin	Thin	Thick	Thick
Calcification	Present/absent	Present/absent	Present/absent	Present/absent
Nodule/mass	Absent	Absent	Absent	Present

CONCLUSION

Zinner syndrome is an uncommon cause of infertility and dysuria in men and should also be suspected if a young patient presents with multiple and unspecific pelvic symptoms.

Recommendations

Any young male patient of infertility presenting with complaints such as hypospermia or hematospermia should be ruled out for Zinner syndrome.

Funding: No funding sources

Conflict of interest: None declared

Ethical approval: Not required

REFERENCES

- Gianna P, Giuseppe PG. Mayer-Rokitansky-Küster-Hauser syndrome and the Zinner syndrome, female and male malformation of reproductive system: Are two separate entities? J Chinese Clin Med. 2007;2:11.
- Sarvani M, Bharadwaja ASS, Chakravarthi KK, Maruti B, Prasad MLV. A Case Report of Three Port Management of Zinner Syndrome. EAS J Med Surg. 2022;4(4):92-6.
- Pereira BJ, Sousa L, Azinhais P, Conceição P, Borges R, Leão R, et al. Zinner's syndrome: an up-to-date review of the literature based on a clinical case. Andrologia. 2009;41(5):322-30.
- Punjani N, Lamb DJ. Male infertility and genitourinary birth defects: there is more than meets the eye. Fertil Steril. 2020;114(2):209-18.
- Shah S, Patel R, Sinha R, Harris M. Zinner syndrome: an unusual cause of bladder outflow obstruction. BJR Case Rep. 2017;2:20160094.
- Florim S, Oliveira V, Rocha D. Zinner syndrome presenting with intermittent scrotal pain in a young man. Radiol Case Rep. 2018;13(6):1224-7.
- Sundar R, Sundar G. Zinner syndrome: an uncommon cause of painful ejaculation. BMJ Case Rep. 2015;bcr2014207618.
- Ghonge NP, Aggarwal B, Sahu AK. Zinner syndrome: A unique triad of mesonephric duct abnormalities as an unusual cause of urinary symptoms in late adolescence. Indian J Urol. 2010;26(3):444-7.
- Tan Z, Li B, Zhang L, Han P, Huang H, Taylor A, et al. Classifying seminal vesicle cysts in the diagnosis and treatment of Zinner syndrome: A report of six cases and review of available literature. Andrologia. 2020;52(1):e13397.
- Liu T, Li X, Huang L, Li H, Cai K, Jiang J, et al. Zinner syndrome: an updated pooled analysis based

on 214 cases from 1999 to 2020: systematic review. *Ann Palliat Med.* 2021;10(2):2271-82.

11. Mehra S, Ranjan R, Garga UC. Zinner syndrome-a rare developmental anomaly of the mesonephric duct diagnosed on magnetic resonance imaging. *Radiol Case Rep.* 2016;11(4):313-7.

Cite this article as: Rashika M, Jain V, Netam SBS, Verma G. Zinner syndrome in a case of male infertility – a case report. *Int Surg J* 2024;11:825-8.