

## Case Report

# A rare case of bowel perforation in an adult with antithyroid medication induced neutropaenic enterocolitis

Alexander Yuen\*

Department of Surgery, Gold Coast University Hospital, Gold Coast, Queensland, Australia

**Received:** 14 February 2024

**Accepted:** 29 February 2024

**\*Correspondence:**

Dr. Alexander Yuen,

E-mail: [alexanderyuen@outlook.com](mailto:alexanderyuen@outlook.com)

**Copyright:** © the author(s), publisher and licensee Medip Academy. This is an open-access article distributed under the terms of the Creative Commons Attribution Non-Commercial License, which permits unrestricted non-commercial use, distribution, and reproduction in any medium, provided the original work is properly cited.

### ABSTRACT

Neutropaenic enterocolitis (NE) is a life-threatening complication of neutropenia rarely seen in adults. Cases of NE arising outside the context of haematological malignancies or oncological treatments remain extremely infrequent. We present a case of bowel perforation secondary to NE in a female adult patient who developed agranulocytosis after commencement of thionamide antithyroid medications for hyperthyroidism. Patients recently commenced on thionamides should be educated on the symptoms of agranulocytosis and present to the hospital. Emergency physicians and surgeons alike should have a high index of suspicion for NE in this group of patients and prompt surgical intervention may be required to reduce the significant mortality rate.

**Keywords:** Neutropaenic enterocolitis, Typhlitis, Antithyroid medications, Thionamide, Neutropaenic enterocolitis in adults

### INTRODUCTION

Neutropaenic enterocolitis (NE) is a rare and life-threatening gastrointestinal complication of neutropaenia, typically affecting the caecum and sometimes the surrounding terminal ileum and ascending colon. Presentations include abdominal pain, diarrhoea, fever and tachycardia.<sup>1</sup> While traditionally seen in the paediatric population, NE is increasingly reported in adults receiving aggressive chemotherapy or with haematological malignancies with an incidence rate of 5.3% in this group.<sup>1,2</sup> The mortality rate is around 50%.<sup>3</sup>

Cases of NE out of the context of chemotherapy and haematological malignancies are exceedingly rare. We report a case of a bowel perforation in a female adult patient with necrotising enterocolitis secondary to agranulocytosis caused by thionamide antithyroid medications. Only one other case was found in literature.<sup>4</sup>

### CASE REPORT

A 35-year-old female patient presented to our emergency department in a thyrotoxic crisis and acute tonsillitis. Her

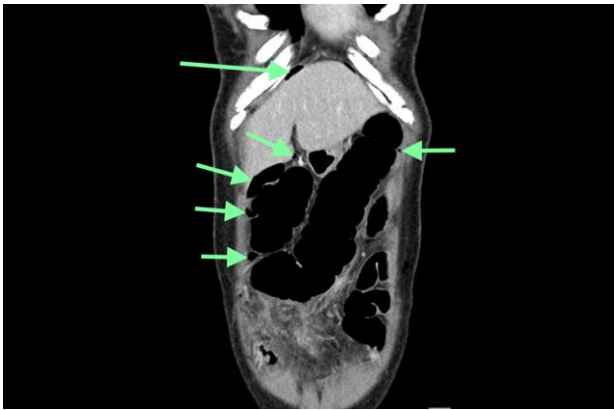history revealed a 1 week history of a sore throat and malaise and a 2 day history of subjective fevers with associated nausea, vomiting and diarrhoea. She was fit and well except for recently diagnosed Grave's disease, treated with methimazole for 4 weeks overseas but was changed to propylthiouracil by her local general practitioner only 2 days before her presentation.

On physical examination, she was tachycardic at 140 bpm and she was febrile to 38.8°C with bilateral tonsillar swelling with exudate and mild left abdominal and suprapubic tenderness on palpation. Her white cell count was  $0.32 \times 10^9/L$  (reference range  $4.0-11.0 \times 10^9/L$ ) with a neutrophil count of  $0.02 \times 10^9/L$  (reference range  $2.00-8.00 \times 10^9/L$ ). A screen for faecal microorganisms and *Clostridium difficile* toxin was negative. She was commenced on intravenous (IV) fluid, broad-spectrum antibiotics for febrile neutropaenia (piperacillin-tazobactam in our institution) and hydrocortisone. Her propylthiouracil was stopped for lugol's iodine.

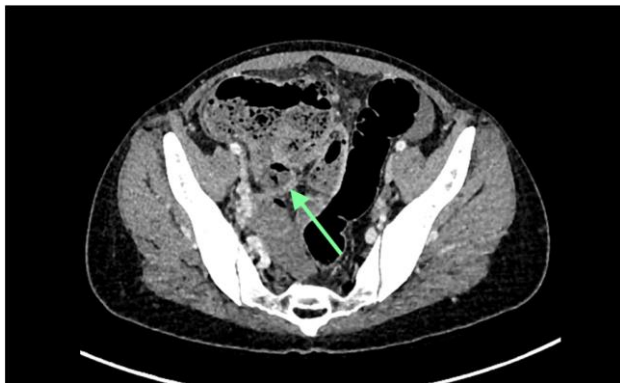
On day 9 of her admission, she had an improvement in her symptoms and was scheduled for an emergency total thyroidectomy for the next day. However, she developed

significant sharp lower abdominal pain that night despite her bowel motions returning back to normal. On examination of the general surgical registrar, her observations were normal but she was uncomfortable and was locally peritonitic in the left lower quadrant.

A contrast-enhanced computed tomography (CT) scan in the early hours of day 10 of her admission (Figure 1) showed moderate pneumoperitoneum in the anterior abdomen and right upper quadrant without a clear site of perforation. A small collection was found in the region of the appendix (Figure 2) and a ruptured appendix was thought to be the source but there was also thickened bowel wall in the caecum and terminal ileum.



**Figure 1: A contrast enhanced computed tomography scan of the abdomen and pelvis showing moderate volume pneumoperitoneum in the anterior and right upper quadrant (marked by the arrows).**



**Figure 2: A contrast enhanced computed tomography scan of the abdomen and pelvis showing a possible collection from the caecum, likely the site of perforation (marked by the arrow). It also shows the thickened bowel walls of both the caecum and ileum.**

By the time the CT scan was done, the patient developed generalised peritonism and was urgently brought to the operating theatre and her thyroidectomy was cancelled. Laparoscopy revealed large volume four quadrant purulent peritonitis with a 5mm perforation lateral to the appendix base with an appendix that was not grossly

inflamed. The caecum, ascending colon and 20 cm of ileum were found to be thickened and indurated. A right hemicolectomy with an end ileostomy was performed. Histology revealed ulceration of the caecum and ascending colon, transmural inflammation with necrosis and perforation in the caecum adjacent to the base of the appendix. The appendix was not inflamed.

Her recovery was complicated by intra-abdominal collections which were managed non-operatively with IV antibiotics and she had an uncomplicated total thyroidectomy 21 days after her initial operation. She was discharged and a plan for reversal of her ileostomy is being made.

## DISCUSSION

NE is a life-threatening gastrointestinal complication of neutropenia that is rarely seen in adults, previously only reported in the paediatric realm. Also known as typhlitis or ileocaecal syndrome, it is characterised by oedema, ulceration, necrosis and perforation of primarily the caecum but oftentimes also the adjoining ascending colon and terminal ileum.<sup>1</sup> Bowel perforation has been reported in 5-10% of cases and it is associated with a very high mortality rate of greater than 50%.<sup>3,4</sup>

The pathogenesis is uncertain and is probably multifactorial. Proposed factors include a reduction of immune response against invasion of intestinal microorganisms, haemorrhage from thrombocytopenia and a shift of organisms to opportunistic organisms, especially in those who have had antibiotic treatment.<sup>1</sup> Patients can present with non-specific abdominal pain as in this case, distention and diarrhoea in the context of fevers and tachycardia.

While traditionally associated with paediatric patients, NE is increasingly recognized in adults with aggressive chemotherapy for malignancies. The pooled incidence of NE has been reported as 5.3% in patients hospitalised with haematological malignancies, for high-dose chemotherapy or for aplastic anaemia.<sup>2</sup>

While thionamide antithyroid medications are a commonplace treatment for hyperthyroidism, agranulocytosis can be a rare side effect,<sup>5</sup> affecting approximately 0.2-0.5% of patients in patients recently started on these medications.<sup>6</sup> This adverse effect is usually benign but, as this case shows, can be potentially life threatening. Patients commenced on thionamides should be counselled regarding the symptoms of agranulocytosis and should discontinue their medication and present to hospital.

This case demonstrates a need for vigilance by surgeons for NE in adult patients with agranulocytosis not only in the context of oncological patients but patients with recently commenced thionamides as well. Interestingly, this case also shows that perforation can occur even 9

days after presentation in hospital. Acute abdominal symptoms in these groups of patients should trigger timely diagnosis with a CT scan if stable or prompt surgical intervention otherwise. This may prevent the high mortality associated with the syndrome as in this case.

## CONCLUSION

NE is a life-threatening gastrointestinal complication of neutropaenia that is increasingly seen in adults. Patients recently commenced on thionamide antithyroid medications should be educated on the symptoms of agranulocytosis and present to the hospital. Emergency physicians and surgeons alike should have a high index of suspicion for NE in this group of patients and prompt surgical intervention may be required to reduce the significant mortality rate.

*Funding: No funding sources*

*Conflict of interest: None declared*

*Ethical approval: Not required*

## REFERENCES

1. Nesher L, Rolston KV. Neutropenic enterocolitis, a growing concern in the era of widespread use of aggressive chemotherapy. Clin Infect Dis. 2013;56(5):711-7.
2. Gorschlüter M, Mey U, Strehl J, Ziske C, Schepke M, Schmidt-Wolf IG, et al. Neutropenic enterocolitis in adults: systematic analysis of evidence quality. Eur J Haematol. 2005;75(1):1-13.
3. Alt B, Glass NR, Sollinger H. Neutropenic enterocolitis in adults: Review of the literature and assessment of surgical intervention. Am J Surg. 1985;149(3):405-8.
4. Degerli V, Yilmaz Duran F, Kucuk M, Atasoy I. A rare cause of neutropenic enterocolitis: Propylthiouracil-induced agranulocytosis. Hong Kong J Emergency Med. 2018;25(5):286-9.
5. Gomez L, Martino R, Rolston KV. Neutropenic enterocolitis: spectrum of the disease and comparison of definite and possible cases. Clin Infect Dis. 1998;27(4):695-9.
6. Sheng WH, Hung CC, Chen YC, Fang, CT, Hsieh SM, Chang SC, et al. Antithyroid-drug-induced agranulocytosis complicated by life-threatening infections. QJM. 1999;92(8):455-61.

**Cite this article as:** Yuen A. A rare case of bowel perforation in an adult with antithyroid medication induced neutropaenic enterocolitis. Int Surg J 2024;11:633-5.