

Case Report

Spontaneous superficial femoral artery pseudoaneurysm: a rare case report

Naveenraj R.^{1*}, Bhavin Patel¹, Hiten Patel², Ajay Tiwari¹

¹Department of General Surgery, GMERS Medical College, Vadodara, Gujarat, India

²Department of Vascular Surgery, GMERS Medical College, Vadodara, Gujarat, India

Received: 22 January 2024

Accepted: 05 March 2024

*Correspondence:

Dr. Naveenraj R.,

E-mail: Naveenrajreddy002@gmail.com

Copyright: © the author(s), publisher and licensee Medip Academy. This is an open-access article distributed under the terms of the Creative Commons Attribution Non-Commercial License, which permits unrestricted non-commercial use, distribution, and reproduction in any medium, provided the original work is properly cited.

ABSTRACT

Spontaneous femoral artery pseudoaneurysm (PSA) is a rare disease and there are few reported cases. We report a case of a 45 year-old male with painless, non-pulsatile swelling in the medial aspect of left lower thigh, which is gradually increasing in size for a period of 2 months. He had no history of trauma or surgery. CT Angiography confirmed a large pseudoaneurysm of the left distal superficial femoral artery (SFA). Then patient had sudden rupture of the pseudoaneurysm and it was treated surgically by ligation of SFA proximal and distal to pseudoaneurysm with excision of large surrounding hematoma.

Keywords: Pseudoaneurysm, SFA, Vascular surgery

INTRODUCTION

A pseudoaneurysm (PSA) is a cavity that communicates with the lumen of an artery through a disruption on its wall.¹

Spontaneous PSA of the superficial femoral artery (SFA) is rare condition and only few cases reported. Femoral artery pseudoaneurysm usually occurs after endovascular procedures and trauma. Other causes include infection (mycotic) and connective tissue disorders.

The common clinical features of pseudoaneurysm includes pulsatile swelling, pain locally, distal ischemic features due to thrombosis or distal embolization. Pseudoaneurysms can resemble cutaneous abscesses owing to the presence of features of inflammation.¹

CASE REPORT

A 45 years old male presented to the department of general surgery and vascular surgery, GMERS medical

college and hospital, Gotri, Vadodara with a painless, non-pulsatile swelling in the medial aspect of left lower thigh for past 2 months. There was no history of trauma. On examination a single swelling of size 14×12 cm was noted in left lower thigh, which was soft in consistency, non-tender, non-reducible, non-compressible. On auscultation, no bruit was appreciated.

Lower limb CT Angiography shows 11.1 (AP)×11.6 (T) ×14.5 (CC) cms sized hypodense lesion seen on medial aspect of left distal thigh in intramuscular and subcutaneous plane displacing the vastus muscles, it is seen arising from distal SFA with active opacification of size 5.9×5.3 cm within, suggestive of distal SFA pseudoaneurysm with partial thrombosis.

Then excision of pseudoaneurysm with grafting of SFA was planned, unfortunately patient developed spontaneous rupture of pseudoaneurysm during hospital stay, then patient taken for emergency surgery. Intraoperatively, pseudoaneurysm of SFA with large infected hematoma surrounding it was observed

involving the muscles of anteromedial lower thigh. Since active infection was suspected, reconstruction procedures were not performed, removal of hematoma with ligation of SFA proximal and distal to pseudoaneurysm with silk 2-0 was done.

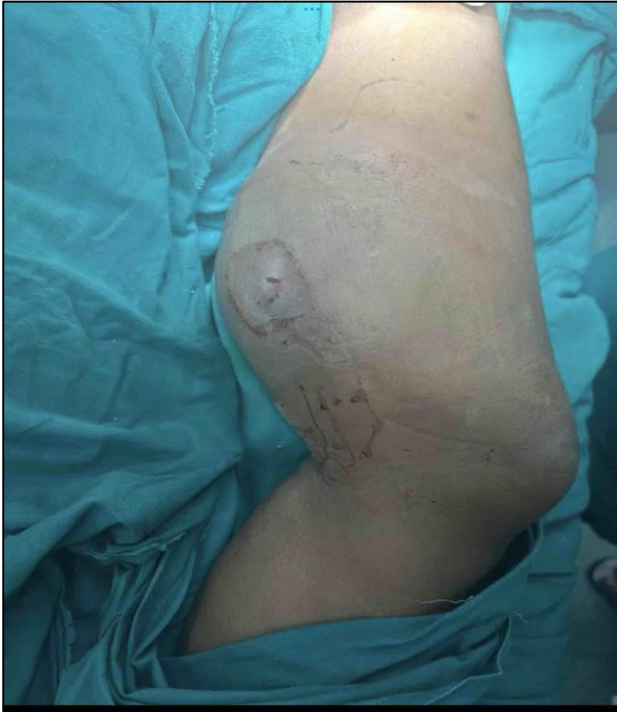

Figure 1: Left lower thigh superficial femoral pseudoaneurysm.

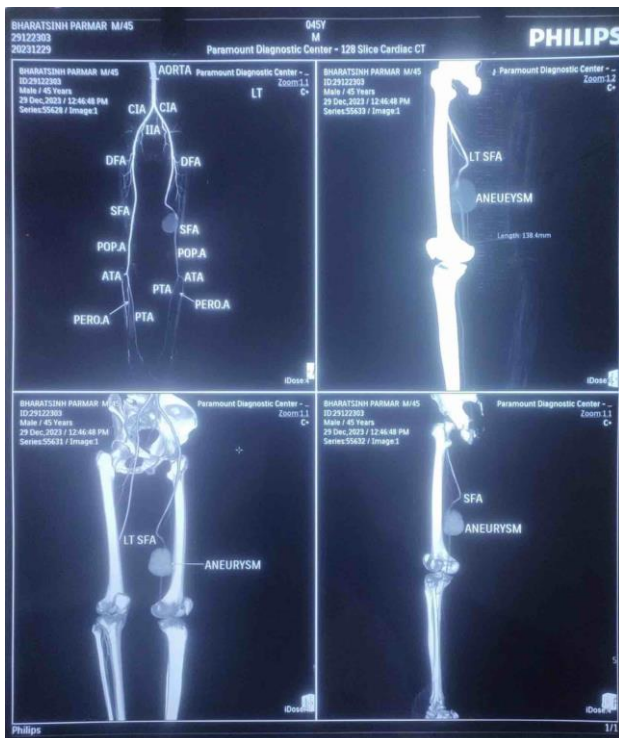


Figure 2: CT angiography showing left distal SFA pseudoaneurysm.

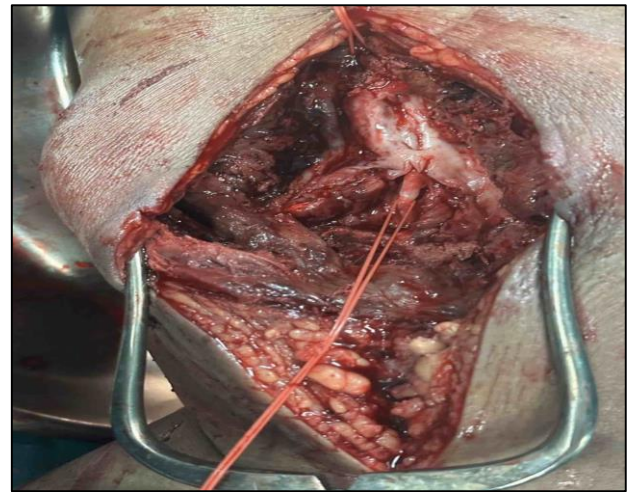


Figure 3: Intra operative picture of distal SFA pseudo-aneurysm.

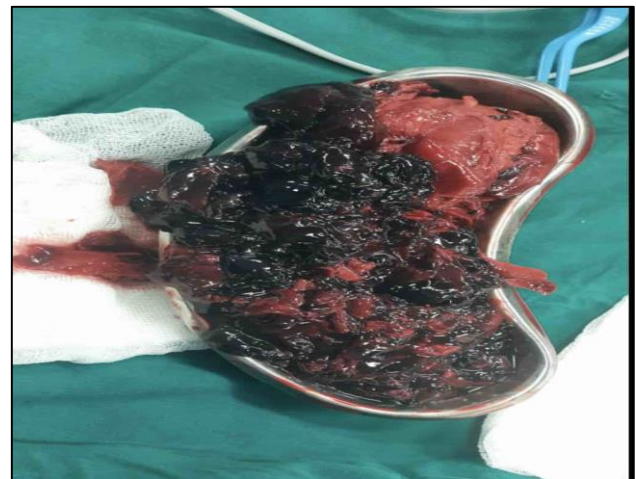

Figure 4: Blood clots removed from pseudo-aneurysm

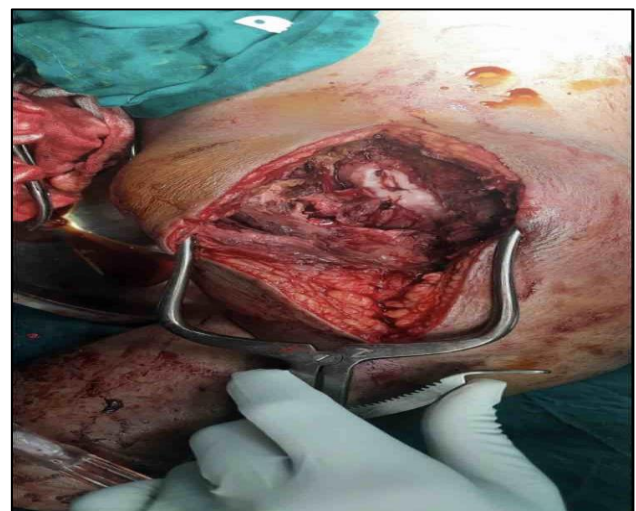


Figure 5: After removal of clot and SFA ligation.

Intra-op tissue cultures were negative, histopathological aspect corresponding to pseudoaneurysm of SFA.

At the one month follow up, surprisingly there is no permanent arterial compromise to the left lower limb after the surgery i.e., patient don't have any complaints of the claudication pain or signs of the distal limb ischaemia.

DISCUSSION

Spontaneous pseudoaneurysm is a rare entity and very limited number of cases have been reported and some of them are mentioned below.²

Table 1: Literature review of spontaneous PSAs of the SFA.

Reports	Age (in years)	Gender	Imaging	Laterality	Size (mm)	Treatment
Case present first operation	17	M	US, CTA	Left, proximal	67×50×80	Surgical treatment
Case present second operation	17	M	CTA	Left, mid segment	83×107×90	Surgical treatment
Ugurlucan et al ³	45	M	US, CTA	Left, mid segment	117×63×75	Surgical treatment
Fukunaga et al ⁴	77	M	CTA	Right, proximal	N/A	Surgical treatment
Samara et al ⁵	62	F	US, MRA, A	Left, distal	70×60	Covered stent
Alsmady et al ⁶	29	M	CTA	Right, lower third	N/A	Surgical treatment
Kouvelas et al ⁷	71	F	CTA	Right, proximal	100	Surgical treatment
Siani et al ⁸	86	F	US, CTA, MRA, A	Left, mid segment	40	Covered stent
Lossef et al ⁹	70	M	A	Right SFA muscular branch	2.5	Spontaneous obliteration
Ramus et al ¹⁰	74	M	US, MRA, CA	Left, proximal	40 and 50 (bilobed)	Covered stent
Goh et al ¹¹	15	M	US, MRI, CA	Bilateral muscular SFA branches	N/A	Embolisation and surgical treatment
Lenartova et al ¹²	82	F	A	Right SFA muscular branch	N/A	Surgical treatment

US=ultrasound, MRI=magnetic resonance imaging, A=angiography, CIA=computed tomography angiogram, N/A=not available.

Etiopathogenesis of spontaneous SFA aneurysm is still not clear usually most of femoral artery pseudoaneurysm occur as a complication of endovascular procedures via femoral access, infection/trauma. Congenital abnormality of the arteries as a cause has also been proposed.¹¹

In elderly people, atherosclerosis may lead to weakness of arterial wall causes pseudoaneurysm. In our case, patient don't have any comorbidities, trauma and other diseases predisposing to pseudoaneurysm suggesting spontaneous SFA pseudoaneurysm.

Usually, vascular swellings like pseudoaneurysm presents with pulsatile, compressible swellings and on auscultation bruit may be heard, but in our case, patient presented with painless, non-pulsatile and non-compressible swelling, on auscultation also bruit was not appreciated probably because of large hematoma surrounding pseudoaneurysm. CT angiography suggestive of large distal SFA pseudoaneurysm with partial thrombosis on medial aspect of distal thigh in intramuscular and subcutaneous plane various treatment options are available for pseudoaneurysm like the ultrasound-guided thrombin injection, coil embolization, endovascular procedures like stenting and grafting and open surgical repair. As compared with cases in above mentioned table various treatment modalities are used, in our case spontaneous rupture of pseudoaneurysm occurred, emergency open surgical procedure of SFA

ligation was performed. Still open surgical repair is gold standard for aneurysmal repair since surgical outcome is better and long-term complications are less.

CONCLUSION

Spontaneous pseudoaneurysm of SFA is very rare and that too spontaneous rupture is extremely rare. In young patients congenital disorders should be considered. There are no specific guidelines for the management of spontaneous pseudoaneurysms, many treatment modalities are available, the optimal treatment option is decided by the surgeon according to the location of the pseudoaneurysm, his experience and that of his center and the availability of minimally invasive treatment.

Funding: No funding sources

Conflict of interest: None declared

Ethical approval: Not required

REFERENCES

- Baird RJ, Doran ML. The false aneurysm. Can Med Assoc J. 1964;91(6):281-4.
- Darigny S, Astarci P, Elens M. A rare case of spontaneous superficial femoral artery pseudoaneurysm in a young patient: case report and review of literature. J Surgical Case Rep. 2021;(8):rjab327.

3. Ugurlucan M, Sendil S, Sayin OA, Barburoglu M, Gok E, Turkyilmaz G, et al. Spontaneous superficial femoral artery pseudoaneurysm in Behcet's disease. *Case Rep Med.* 2014;2014:860243.
4. Fukunaga N, Koyama T, Konoshi Y, Murashita T, Okada Y. Spontaneous rupture of superficial femoral artery. *Ann Vasc Dis.* 2013;6:212-4.
5. Samara O, Saleh AI, Alomari A, Al Ryalat N, Hadidy A, Alsmady M. Giant spontaneous femoral artery pseudoaneurysm treated with covered stents: report of a rare presentation and review of literature. *Sultan Qaboos Univ Med J.* 2013;13(3):E472-5.
6. Alsmady M, Abdallah F, Shanti H, Samara O. Spontaneous femoral artery pseudoaneurysm in a young patient. *J Surg Case Rep.* 2012;2012:18.
7. Kouvelos GN, Papa N, Matsagkas MI. Spontaneous superficial femoral artery giant false aneurysm. *ANZ J Surg.* 2011;81:655-6.
8. Siani A, Flishman I, Siani L, Mounayergi F, Zaccaria A, Schioppa A, et al. Spontaneous rupture of the superficial femoral artery treated via an endovascular approach. *Tex Heart Inst J.* 2008;35:66-8.
9. Lossef SV, Gomes MN, Barth KH. Hemorrhage from spontaneous rupture of muscular branches of the superficial femoral artery. *J Vasc Interv Radiol.* 1994;5:147-8.
10. Ramus JR, Gibson M, Magee T, Torrie P. Spontaneous rupture of the superficial femoral artery treated with endovascular stent grafting. *Cardiovasc Intervent Radiol.* 2007;30:1016-9.
11. Goh BK, Chen CY, Hoe MN. Bilateral spontaneous rupture of the muscular branch of the superficial femoral artery with pseudoaneurysm formation. *Ann Vasc Surg.* 2004;18(6):736-9.
12. Lenartova M, Tak T. Iatrogenic pseudoaneurysm of femoral artery: case report and literature review. *Clin Med Res.* 2003;1:243-7.

Cite this article as: Naveenraj R, Patel B, Patel H, Tiwari A. Spontaneous superficial femoral artery pseudoaneurysm: a rare case report. *Int Surg J* 2024;11:658-61.