

## Case Report

# Percutaneous nephrolithotomy in case of crossed fused renal ectopia: a case report

Ankit Anand<sup>1\*</sup>, Prakriti Gupta<sup>2</sup>, Sumit Gupta<sup>1</sup>, Arpit Tripathi<sup>1</sup>, Shailja Mishra<sup>1</sup>

<sup>1</sup>Department of General Surgery, TS Mishra Medical College and Hospital, Lucknow, Uttar Pradesh, India

<sup>2</sup>Department of Anesthesia, TS Mishra Medical College and Hospital, Lucknow, Uttar Pradesh, India

**Received:** 16 January 2024

**Accepted:** 14 February 2024

### \*Correspondence:

Dr. Ankit Anand,

E-mail: [Dr.ankitanand19@gmail.com](mailto:Dr.ankitanand19@gmail.com)

**Copyright:** © the author(s), publisher and licensee Medip Academy. This is an open-access article distributed under the terms of the Creative Commons Attribution Non-Commercial License, which permits unrestricted non-commercial use, distribution, and reproduction in any medium, provided the original work is properly cited.

### ABSTRACT

Crossed renal ectopia is a rare congenital anomaly that is frequently associated with gastrointestinal, cardiovascular, genital, and bone malformations. To best of our knowledge, there aren't many cases of inferior crossed fused renal ectopia of the right kidney documented in the literature at this time. A case of crossed-fused renal ectopia is presented here. A 32-year-old man arrived at our hospital complaining of pain in the right flank. Diagnosis: We suspected a single right kidney based on abdominal ultrasonography. An inferior left to right crossed-fused ectopic kidney with calculus in the right (normal) renal pelvis was the patient's diagnosis when combined with 3D computed tomography. Interventions: percutaneous nephrolithotomy with DJ stenting. Because the management of renal stone in this uncommon malformation is complicated, a preoperative assessment with contrast computed tomography is required before moving forward with surgery in order to explore a single kidney with calculi and avoid missing the diagnosis of crossed fused renal ectopia.

**Keywords:** Cross-fused renal ectopia, Kidney congenital anomaly, Percutaneous nephrolithotomy

### INTRODUCTION

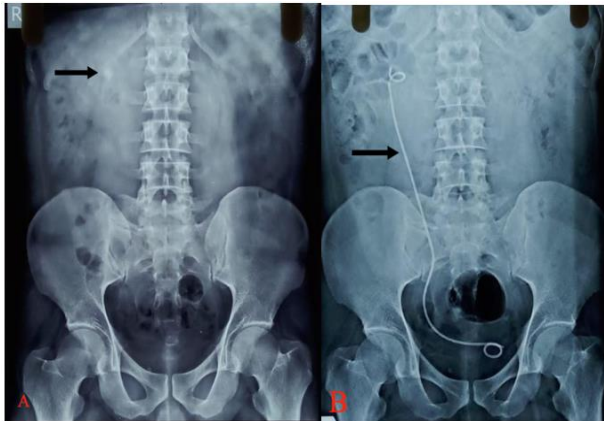
A rare congenital condition known as crossed renal ectopia occurs when the ureter of the ectopic kidney still descends to the normal location on the bladder, but the kidneys are located on the same side. There are two types of renal ectopia: crossed-unfused and crossed-fused, with the latter being more prevalent.<sup>1</sup> According to reports, the prevalence of crossed-fused renal ectopia at autopsy and live birth is approximately 1:7500 and 1:1000, respectively, with a predominance in males.<sup>2-7</sup> The majority of people cannot be diagnosed with the anomaly until they have a medical examination because the symptoms are not readily apparent<sup>3</sup>. The anomaly is linked to numerous malformations, such as

nephrolithiasis, renal tumors, cystic dysplasia, and obstruction of the ureteropelvic junction, according to published studies that are currently available.<sup>4</sup>

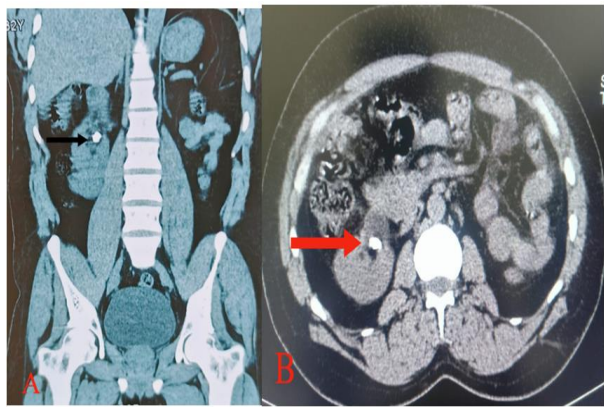
### CASE REPORT

A 32-year-old male patient presented to us in the hospital with chief complaints of right flank pain associated with burning micturition and hematuria. On examination, the patient had moderate tenderness in the right flank region. The patient's family history was unremarkable. Laboratory investigations and routine urine examination showed a hemoglobin count of 14 g/dl; white blood cell count of 10-12 HPF; Renal function tests showed a creatinine level of 1.0 mg/dl. X-ray KUB showing right

renal calculus (Figure 1). A computed tomography (CT) urogram with contrast showed the right kidney measuring 17 cm in length and an absent left kidney (Figure 2).



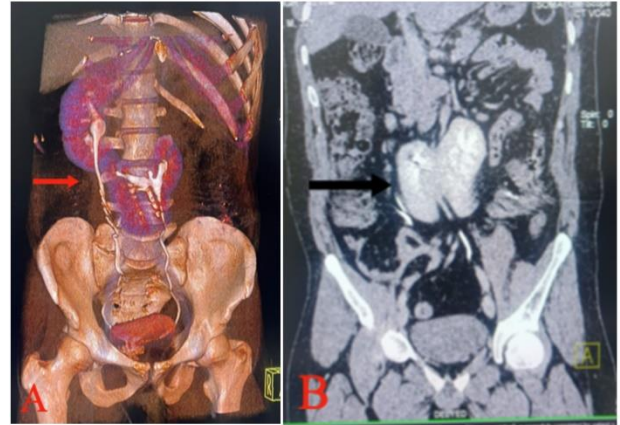
**Figure 1: (A) Preoperative X-ray KUB revealed stone shadows (arrow) in the right abdominal area, (B) Postoperative KUB showed no stone shadows and arrow show DJ stent.**



**Figure 2: NCCT KUB: (A & B) arrow showing 1.5 cm calculus in right kidney.**

The right kidney showed a malrotated anteriorly faced duplex collecting system, with both ureters draining separately into the urinary bladder. Within the right renal upper collecting pelvis, a calculus with a maximum diameter of 1.5 cm and a mean density of 1000 HU was observed (Figure 3). The right ureter was normal. Left kidney is in midline, upper pole of left kidney fused with lower pole of right kidney. The patient then decided to have the calculus removed by percutaneous nephrolithotomy (PCNL). First, the patient was put in the lithotomy position and cystoscopy was performed. Once the right ureteric orifice was seen, a guidewire was passed along a 5-Fr open-ended ureteric catheter. Then, the patient was switched to the prone position. A stiff guidewire 0.0034 fr was passed into the renal pelvis, and serial dilatation was performed using 6, 7, 8, 9, 10, and 12-Fr dilators, followed by central rod placement, and five dilators were passed over the central rod and guidewire. A 24-Fr sheath was then passed through a

19.5- Fr nephroscope. A hard stone measuring 1.5 cm was seen. The stone was removed in toto. A DJ stent was placed, and a dry dressing was applied. No complications occurred during or after the surgery. On post operative day 1 X-ray KUB was done no ROD present. Patient was discharged on post operative day 2. A follow-up for stent removal was planned after one month.



**Figure 3: 3D computed tomography; (A) CECT KUB, (B) revealed Left to right crossed-fused renal ectopia.**

## DISCUSSION

Crossed-fused renal ectopia is about 10 times more common than unfused renal ectopia, with an autopsy incidence rate of roughly 1:7500.<sup>1-3</sup> In crossed-unfused renal ectopia, the ureter of the ectopic kidney descends, crosses the midline, and enters the urinary bladder in the normal position, but the renal parenchyma of the ectopic kidney does not fuse with that of the normal kidney. The ectopic kidney crosses to the other side and fuses with the normal kidney in crossed-fused renal ectopia. Usually, the ectopic kidney with fusion is situated inferiorly to the normal kidney. Crossed-fused renal ectopia is a rare congenital abnormal development of the urinary system.<sup>4,5</sup> There are 6 subtypes of the anomaly: Inferior ectopia, in which the ectopic kidney lies inferior to the normal kidney, superior ectopia, in which the upper pole of the normal kidney fuses with the lower pole of the ectopic kidney, sigmoid or S-shaped, lump or pancake, L-shaped; and disk.<sup>6</sup> Abdominal ultrasound, KUB, retrograde pyelography, and 3D computed tomography can all be used to confirm the diagnosis of crossed-fused renal ectopia prior to surgery. First, the absent kidney can be seen with ultrasonography. The size and location of any stones present can be ascertained with the aid of KUB and retrograde pyelography. The 3D CT results are important to pay attention to because they identify vital vessels that will permit access while preventing bleeding and needless accidents.

Percutaneous Nephrolithotomy (PCNL), is more common in patients with high stone burdens. However, because of the ectopic kidney's location and abnormal vascular supply, there is a higher risk of bleeding and

gastrointestinal harm. According to Gupta et al 46 patients (52 renal units) with aberrant kidneys, including 4 patients with crossed-fused ectopic kidneys, were treated with PCNL.<sup>8</sup> The stones had an average size of 22 mm and an average operating time of 80 minutes (with a range of 70-100 minutes).<sup>9</sup> Two cases of crossed-fused renal ectopia one with 20 mm stones and the other with 15 mm stones were reported by Huang et al.<sup>10</sup> After undergoing PCNL, one patient had all of the stones removed. Another alternative treatment, laparoscopic nephrolithotomy, which combines laparoscopic pyeloplasty and concurrent pyelolithotomy, was described in a study by Aminsharifi et al.<sup>11</sup> However, because of the complex anatomical malformations and fragile renal vasculature that increase the risk of injury to the aberrant renal vessels and make it difficult to define the anatomical structures of the ectopic kidney, this demanding surgery requires considerable professional surgical techniques and a lengthy learning curve.<sup>11</sup> Furthermore, to the best of our knowledge, Resorlu et al reported the first instance of RIRS being used in a patient who had a 15 mm stone and crossed-fused renal ectopia, confirming that RIRS is a safe and practical minimally invasive option for use in cases of this anomaly.<sup>12</sup>

## CONCLUSION

The diagnosis of crossed renal ectopia necessitates precise and thorough preoperative examinations and assessments due to the anomaly's rarity. The urologist's experience, the size of the stones, the degree of hydronephrosis, and the vascular anatomy all play a role in the treatment plan for CRE with stones. The cases from the literature indicate that the treatment of CRE with stones and carcinoma has been moving toward minimally invasive surgery. Urologists treating CRE with abnormalities involving stones, carcinoma, and other malformations should select safe, adequate, and workable treatment strategies.

*Funding: No funding sources*

*Conflict of interest: None declared*

*Ethical approval: Not required*

## REFERENCES

1. Dyer RB, Chen MY, Zagoria RJ. Classic signs in uro-radiology. *Radiographics.* 2004;24(1):S247-80.
2. Ectopic kidney. Available at: <https://radiopaedia.org/articles/ectopic-kidney-1>. Accessed on July 2023.
3. Ratola A, Almiro MM, Lacerda Vidal R, Neves N, Bicho A, et al. Crossed renal ectopia without fusion: an uncommon cause of abdominal mass. *Case Rep Nephrol.* 2015;2015:679342.
4. Naseri M. Cross-fused renal ectopia associated with vesicoureteral reflux; a case report. *J Renal Inj Prev.* 2016;5:200-2.
5. Babu C, Sharma V, Gupta OP. Renal fusion anomalies: a review of surgical anatomy. *Anat Physiol.* 2015;5:S5.
6. Akdogan L, Oguz AK, Ergun T, Ergun I. The rarest of the rare: crossed fused renal ectopia of the superior ectopia type. *Case Rep Nephrol.* 2015;2015:742419.
7. Rahim TA, Mittal P. Crossed renal ectopia with a fused supernumerary kidney. *Cureus.* 2020;12:e7669.
8. Gupta NP, Mishra S, Seth A, Anand A. Percutaneous nephrolithotomy in abnormal kidneys: single-center experience. *Urology.* 2009;73:71004.
9. Huang L, Lin Y, Tang Z. Management of upper urinary tract calculi in crossed fused renal ectopic anomaly. *Exp Ther Med.* 2018;15:371-6.
10. Aminsharifi A, Niroomand R, Kroup M and Hosseini MM. Laparoscopic nephrolithotomy in a patient with crossed fused renal ectopia. *Nat Rev Urol.* 2009;6: 675-9.
11. Resorlu M, Kabar M, Resorlu B, Doluoglu OG, Kilinc MF, Karakan T. Retrograde intrarenal surgery in cross-fused ectopic kidney. *Urology.* 2015;85:e5-6.

**Cite this article as:** Anand A, Gupta P, Gupta S, Tripathi A, Mishra S. Percutaneous nephrolithotomy in case of crossed fused renal ectopia: a case report. *Int Surg J* 2024;11:539-41.