

Case Report

Littre's hernia: a rare complication of Meckel's diverticulum

Prakash Kumar Sahoo*, Suman Saurav Rout

Department of General Surgery, Institute of Medical Sciences and SUM Hospital, Bhubaneswar, Odisha, India

Received: 25 January 2017

Accepted: 23 February 2017

***Correspondence:**

Dr. Prakash Kumar Sahoo,

E-mail: drpksahoo2003@yahoo.co.in

Copyright: © the author(s), publisher and licensee Medip Academy. This is an open-access article distributed under the terms of the Creative Commons Attribution Non-Commercial License, which permits unrestricted non-commercial use, distribution, and reproduction in any medium, provided the original work is properly cited.

ABSTRACT

Littre's hernia is caused by the protrusion of Meckel's diverticulum through an orifice in the abdominal wall. Meckel's diverticulum is the most common congenital anomaly of the gastrointestinal tract that is generally asymptomatic and only manifests in a specific way when complications exist. An unusual complication of Meckel's diverticulum is known as Littre's hernia. It comprises less than 1% of all Meckel's diverticulum. Usual sites of Littre hernia are right inguinal (50% of cases), umbilical hernia (20%), and femoral hernia (20%). We present a case of Littre's hernia where we found a strangulated Meckel's diverticulum in an inguinal hernia sac.

Keywords: Littre's, Meckel's, Meckel's diverticulum in hernial sac

INTRODUCTION

Meckel's diverticulum is a remnant of the proximal portion of the omphalo-mesenteric duct, which links the embryonic intestine with the umbilical bladder until the fifth week of gestation. The incidence of Meckel's diverticulum is 2-3% and normally it is not symptomatic.¹ Only 4-6% of cases will produce symptoms (more frequent during infancy), the principal manifestation being rectal bleeding, sometimes massive, due to the presence of gastric mucosa.² Obstruction, intussusception and, more rarely, diverticulum to bladder fistulae and tumours may occur. Littre's hernia is caused by the protrusion of Meckel's diverticulum through an orifice in the abdominal wall. The incidence of Littre's hernia is very rare and not many cases are found in the literature.

CASE REPORT

A 39-year-old male presented with a hard-painful lump in his right groin for last 3 days accompanied by abdominal pain, nausea and vomiting admitted to the hospital. He was diagnosed with a right sided inguinal hernia. During that time, he had occasionally noticed an uncomfortable bulge but had always been able to reduce it himself

without difficulty. On physical examination a hard, tender lump was palpable in the right groin which was irreducible in nature. The leukocyte count was elevated i.e $13.7 \times 10^3/L$ with neutrophilia. Rest of the biochemical and hematological investigations were within normal limits. Plain abdominal radiograph demonstrated air fluid levels. But there was no evidence of intestinal obstruction. Diagnosis of an obstructed right inguinal hernia was made preoperatively.

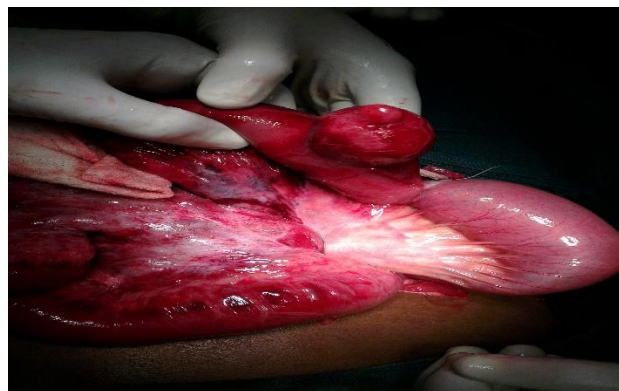

Figure 1: Congested meckel's diverticulum after removal from the hernial sac.

The pathology was approached through a right para-inguinal incision. An incarcerated inguinal hernia was found. The hernial contents were reddish, edematous with adhesions between the intestinal segments. The contents of the hernial sac were found to be a loop of ileum with an inflamed Meckel diverticulum at the base, 3.5cm long. The ileal loops proximal to the diverticulum was found to be dilated. The bands were dissected and the Meckel diverticulum was resected together with a segment of the small intestine and anastomosis made. Rest of the bowel was thoroughly examined for viability and was reduced into the abdomen. Bassini's herniorrhaphy was done with a prolene 1.0 suture. The patient did well without any complications and was discharged home on the seventh postoperative day.

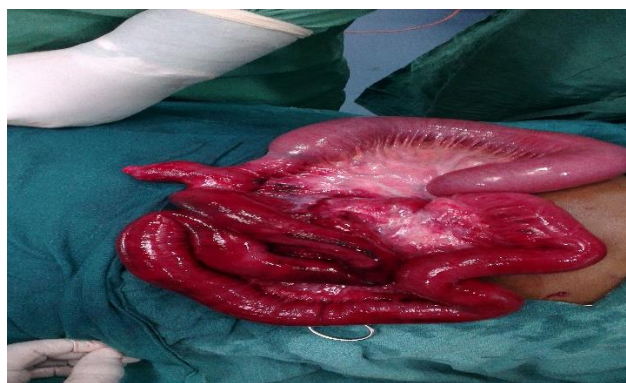

Figure 2: Congested Meckel's Diverticulum along with loops of ileum after removal from the hernial sac.

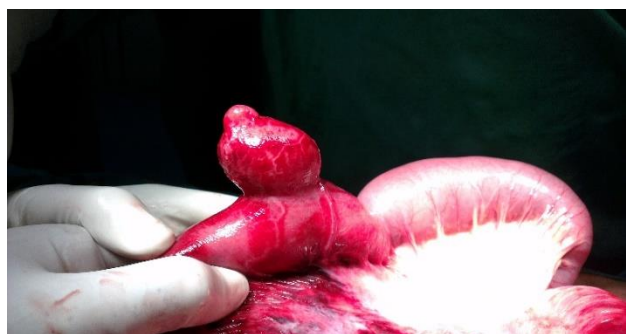


Figure 3: Strangulated Meckel's diverticulum.

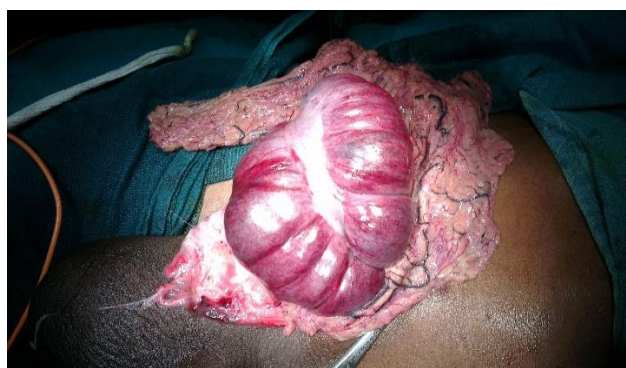

Figure 4: Opened up hernial sac.

On histopathological examination the Meckel's diverticulum was found to be lined by ileal mucosa and there was no ectopic tissue.

DISCUSSION

The abnormal protrusion of Meckel's diverticulum through an orifice in the abdominal wall is what is known as Littre's hernia and was first described by Alexis de Littre (1700) when he reported ileal diverticulae and attributed them to the traction realized on the ileum. This idea was conflicted by August Gottlieb Richter in 1785. However it seemed that both had very well ignored the embryological origins which was later in 1809 described by Johann Friedrich Meckel.¹ It is notable that Sir Frederic Treves later in 1897 distinguished between Littre's hernia and Richter's hernia.

Meckel's diverticulum is a true intestinal diverticulum and arises due to the failure of the omphalo-mesenteric duct to obliterate during the fifth week of fetal development.² With an incidence of around 2-3% it is the most common congenital anomaly of the GIT.¹ It is named after Johann Friedrich Meckel who in 1809 publish a meticulous description of its anatomy and embryonic origin.¹ It occurs on the antimesenteric border of the ileum and may be located 10-150 cm from the ileocaecal valve.³ It usually measures from 4 to 6cm in length and 2cm in diameter. It contains all the normal layers of the intestinal wall and approximately 50% of cases have some evidence of ectopic or heterotopic gastric, pancreatic, duodenal, colonic or biliary mucosa.⁴ 60% of Meckel's diverticulum become symptomatic before the age of ten and around 70% before the age of 40 years.⁵ The most common presentation being an incidental finding at laparotomy.⁶

Bowel obstruction, intussusception, diverticulitis, bleeding are significant complications of Meckel's diverticulum. Incarceration into a hernia sac or strangulation also may occur leading to emergencies. In 1978, Yamaguchi et al reviewed 600 patients with a symptomatic Meckel's diverticulum, ages ranging from one day old to 91 years old. In their series, the most common complication of Meckel's diverticulum was intestinal obstruction (36.5%) followed by intussusception (13.7%), inflammation (12.7%), hemorrhage (11.8%), perforation (7.3%) and as a component of a hernia sac or Littre's hernia (4.7%).⁷ Several mechanisms may cause obstruction. The diverticulum may be the leading point for an intussusception or volvulus around a fibrous band by which the diverticulum remains attached to the umbilicus. Other mechanisms of obstruction include entrapment of bowel within an internal hernia, entrapment between the mesentery and a mesodiverticular band, strangulation of the diverticulum in an external hernia.⁴ Our patient has been operated as strangulated inguinal hernia and Meckel's diverticulum in the hernia sac was found at operation.

Groin hernias do incarcerate and strangulate and the contents of the hernia sac may vary. Loops of bowel or more rarely the appendix (Amyand's Hernia), ovary, fallopian tube, bladder or a Meckel's diverticulum may be the found as the contents. The incidence of a Littre's hernia presenting in complicated abdominal hernias has been reported to be 0.78% as reported by Zuniga and Zupanec in 1977.⁸ Similarly, Frankau also reported the incidence of finding a Meckel's diverticulum in a complicated abdominal hernia to be 0.6% in 1931.⁹ As in present case, a Meckel's diverticulum is most commonly found in an inguinal hernia (50%) followed by umbilical (20-30%) and femoral (20%) hernias.⁸

In symptomatic Littre hernia the patient generally presents with a mass.¹⁰ Pain, fever and vomiting are common symptoms. Although fever and leucocytosis evolve, mechanical intestinal obstruction mostly may not be seen in incarcerated or strangulated Littre hernia.¹⁰ The preoperative diagnosis of a Littre hernia is difficult to establish. In case of mechanical small intestinal obstruction plain abdominal radiographs may demonstrate air fluid level. The computerised tomography scans are often nonspecific but occasionally helpful. The diagnosis is generally not possible with computerised tomography unless the diverticulum is visualized.¹¹

The usual evaluation for a suspected incarcerated hernia should be undertaken to ensure prompt reduction and to prevent ischemic consequences. Besides bowel ischemia, other complications include pain, bleeding, and perforation. Inflammation of the Meckel's diverticulum can create dense adhesions to the hernia sac. The accepted treatment is wedge resection of the diverticulum and repair of the ileum from within the sac.¹² If there is edema or inflammation at the base of the diverticulum as in our case; resection and anastomosis of a segment of ileum may be necessary. It may prevent postoperative stricture of resected segment.^{12,13} If thorough inspection and proper resection are not possible through the inguinal incision, it might be necessary to make an additional incision on the abdomen. Proponents of laparoscopic hernia repair have reported cases in which the Meckel's diverticulum was identified and reduced laparoscopically, and then resected through an umbilical incision.

CONCLUSION

In conclusion, the Meckel's diverticulum may be found in any type of hernia especially at inguinal site so, incarcerated hernia should not be attempted to reduce. In treatment of Littre hernia Meckel diverticulum should be resected and it is better to perform resection and

anastomosis of ileal segment in these patients to prevent postoperative ileal stricture.

Funding: No funding sources

Conflict of interest: None declared

Ethical approval: Not required

REFERENCES

1. Lauschke H, Kaminski M, Stratmann H. Littre's hernia clinical aspects and review of the history. *Chirurg*. 1999;70:953-6.
2. Moore TC. Omphalomesenteric duct malformations. *Semin Pediatr Surg*. 1996;5:116-23.
3. Ellis H. (1985) Meckel's diverticulum; diverticulosis of small intestine; umbilical fistula and tumors. In: Schwartz SI, Ellis H, Hussels WC, eds. *Maingot's Abdominal Operations*. Appleton-Century-Crofts, Norwalk, Connecticut; 1985:1085-1104.
4. Skandalakis PN, Zoras O, Skandalakis JE. Littre hernia: surgical anatomy, embryology, and technique of repair. *Am Surg*. 2006;72:238-43.
5. Margolies MN, Compton CC. A 23-year-old man with recurrent bouts of abdominal pain and vomiting. *N Engl J Med*. 1989;320:171-8.
6. Schwartz MZ. Meckel's diverticulum and other omphalomesenteric duct remnants. In: Wyllie R, Hyams JS, eds. *Pediatric gastrointestinal disease: pathophysiology, diagnosis, management*. Philadelphia, Saunders; 1999:483-8.
7. Yamaguchi M, Takeuchi S, Awazu S. Meckel's diverticulum. *Am J Surg*. 1978;136:247-9.
8. Zuniga D, Zupanec R. Littre hernia. *J Am Med Assoc*. 1977;237(15):1599
9. Frankau C. Strangulated hernias: a review of 1487 cases. *Br J Surg*. 1931;19:176-91.
10. Perlman JA, Hoover HC, Safer PK. Femoral hernia with strangulated Meckel's diverticulum (Littre's hernia). *Am J Surg*. 1980;139:286-9.
11. Sinha R. Bowel obstruction due to Littre hernia: CT diagnosis. *Abdom Imag*. 2005;30:682-4.
12. Ravikumar KK, Khope SS, Ganapathi BP. Littre's hernia in a child-an operative surprise (a case report). *J Postgrad Med*. 1989;35:112-3.
13. St-Vil D, Brandt ML, Panic S. Meckel's diverticulum in children: a 20-year review. *J Pediatr Surg*. 1991;26:1289-92.

Cite this article as: Sahoo PK, Rout SS. Littre's hernia: a rare complication of Meckel's diverticulum. *Int Surg J* 2017;4:1481-3.