

Original Research Article

Posterior rectus sheath variations: surgical significance and clinical implications for laparoscopic hernia surgeons

Maulana M. Ansari*

Department of Surgery, J. N. Medical College, Aligarh Muslim University, Aligarh, Uttar Pradesh, India

Received: 15 December 2017

Revised: 09 January 2018

Accepted: 11 January 2018

*Correspondence:

Dr. Maulana M. Ansari,

E-mail: mmansari.amu@gmail.com

Copyright: © the author(s), publisher and licensee Medip Academy. This is an open-access article distributed under the terms of the Creative Commons Attribution Non-Commercial License, which permits unrestricted non-commercial use, distribution, and reproduction in any medium, provided the original work is properly cited.

ABSTRACT

Background: Laparoscopic hernia surgeon needs accurate knowledge of not only of target inguinal region but also of adjacent access areas, but he/she is severely constrained by absence of research work on laparoscopic live surgical anatomy in literature.

Methods: Prospective study in patients who underwent laparoscopic total extra-peritoneal preperitoneal (TEPP) inguinal hernioplasty through 3-midline-port technique at Jawaharlal Nehru Medical College Hospital, Aligarh between 2010 and 2015.

Results: Sixty-eight TEPP repairs were performed in 60 adult patients. Overall incidence of conversion to Open/TAPP hernioplasty was 4% of all cases, but conversion secondary to the anatomic variation of short PRS was seen in only 1.4% of all cases. The endvision and ease of procedure (EOP) were 8.20 ± 1.33 and 7.27 ± 2.05 visual analog score respectively, and both of them were adversely affected in presence of variant PRS anatomy. Average operation time (OT) for unilateral TEPP hernioplasty was 1.9 hours and it was adversely affected in presence of variant PRS anatomy. Overall incidence of surgical emphysema was 16%, and its development was significantly more in presence of variant PRS anatomy. Overall incidence of peritoneal injury, postoperative seroma, infection and chronic pain was 28%, 10%, 6.7% and 1.5% respectively, but they were not affected by variant PRS anatomy.

Conclusions: Posterior Rectus Sheath Variations had significant impact on the intra-operative working but did not affect post-operative clinical outcome. Keen observation, timely recognition of anatomic variations and judicious dissection are essential keys for smooth conduct of the well-organized TEPP hernioplasty with ease, safety, rapidity and better results.

Keywords: Anatomic variations, Laparoscopic inguinal anatomy, Posterior rectus sheath, Posterior rectus sheath variations, Surgical significance, TEPP anatomy

INTRODUCTION

The current revolution of laparoscopic surgery has markedly altered the manners in how surgeons perceive and manipulate the anatomic tissues and planes of the human body.¹ The advent of laparoscopic surgery has generated a new field of live surgical anatomy called the

laparoscopic anatomy, and understanding of systematic laparoscopic anatomy can provide the operating surgeons a clear procedural approach, and would immensely benefit the laparoscopic surgeons in training.² The laparoscopic posterior approach does not follow the anatomy of the anterior approach for inguinal hernia repair, and this approach is also unfamiliar to the majority

of the surgeons.^{3,4} The laparoscopic hernia surgeon needs accurate knowledge of the specific anatomic landmarks and surgical planes not only of the target inguinal region but also of the adjacent access areas.^{2,5,6}

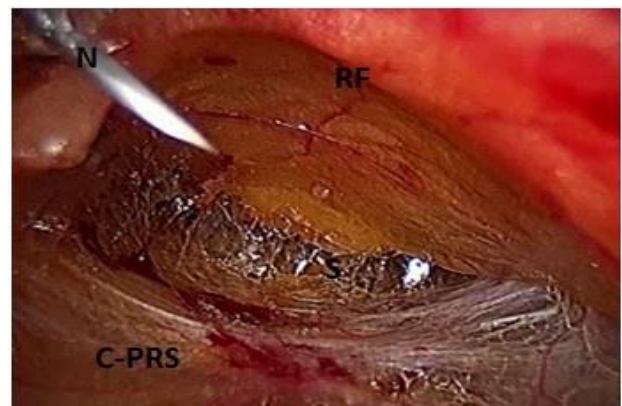
No doubt, the TEPP hernioplasty is now a well-recognized technique with proven efficacy, reduced post-operative pain and low failure rate in addition to the early return to activity and work.⁷ However, the operator often finds difficulties in execution of TEPP for no apparent reasons/cause, which are almost always attributed to lack of surgical skills or presence of adhesions. It is now increasingly recognized that despite the merits of laparoscopic hernioplasty, extra-peritoneal anatomy and dissection in the groin is poorly understood by the most practicing surgeons.^{4,7-10} Inadequate understanding and improper dissection of pre-peritoneal anatomy is now regarded as the main cause of difficulties during total extraperitoneal preperitoneal (TEPP) hernioplasty for inguinal hernia with a long learning curve, leading to its lack of popularity despite the obvious advantages and better results.⁷⁻¹¹ In contrast to the general belief, anatomy of the groin is reported to be complex, especially in presence of anatomic variations reported by several investigators that received little/no attention of anatomists and practicing surgeons alike.^{8,10,12-15} In 2001, Robert Bendavid declared that 'Nothing goes as far forward preventing complications as the surgeon's awareness and fear of them'.¹⁶

Recently the author has reported an exhaustive laparoscopic study on the anatomic variations in the posterior rectus sheath (PRS) observed during the TEPP hernioplasty.¹⁷ Details of the intraoperative and postoperative implications of the PRS variations on the surgical technique and functional outcome of TEPP hernioplasty in patients with inguinal hernia are presented herein.

METHODS

In the Department of Surgery, J. N. Medical College and Hospital, Aligarh Muslim University, Aligarh, India, a prospective doctoral research study was conducted from April 2010 to November 2016 under the Institutional Ethics Committee clearance and written informed consent. The study recruited all consecutive adult patients with primary inguinal hernia who underwent the TEPP hernioplasty after fulfilling the inclusion and exclusion criteria. The inclusion criteria comprised of adult patients with uncomplicated primary inguinal hernia, adult patients of age 18 years and above, and adult patients with ASA Grade I and II only of American Society of Anesthesiologists. Patients less than 18 years of age, patients with high physiological score of ASA grade III-V, adult patients with history of lower abdominal surgery, adult patients with recurrent/ complicated inguinal hernia, adult patients with femoral hernia, and adult patients with refusal for the laparoscopic repair were excluded from the study.

Surgical approach for the TEPP hernioplasty comprised of the standard 3-midline-port technique as was consistently same as was followed and reported earlier by the author.¹⁸⁻²³ CO₂ insufflation at a low pressure of 12mmHg was started after placement of a blunt metallic 11mm trocar in the infra-umbilical region. Gentle unhurried methodical telescopic dissection was performed in the avascular plane of posterior rectus canal in order to make good visualization and careful observation of the posterior rectus sheath, forming the posterior boundary of the posterior rectus canal. After medial dissection up to the pubic symphysis, two 5mm plastic working ports were placed in the midline lower down after the needle confirmation and under direct vision, i.e., one port (third port) was placed two-finger breadth above the upper border of the symphysis pubis and the other (second port) in between the first and the second ports (Figure 1). Thereafter, the further definitive dissection in the pelvic and inguinal regions was carried out gently and carefully, to create the wide preperitoneal space from the midline to the anterior superior iliac spine in order to place an adequate-size mesh. Mesh was frequently fixed with a single stitch of 3-0 polypropylene suture. Controlled slow deflation under vision was done to prevent infolding the edges of the mesh.



N, needle inserted percutaneously under vision to ensure the correct site and the direction for insertion within a small limited space of posterior rectus canal; RF, well-defined diaphanous rectus abdominis muscle covering rectus abdominis muscle anteriorly; C-PRS, grossly attenuated complete posterior rectus sheath extending up to the pubic bone; S, sign of lighthouse visible in the depth of the posterior rectus canal; (reproduced with permission from Ansari's thesis²⁵)

Figure 1: Percutaneous needle confirmation before placement of working port after initial telescopic dissection in the posterior rectus canal.

The study recorded the demographic data in terms of age, gender, weight (measured without footwear), height, and profession/occupation of the patients. Body mass index (BMI) was calculated by the Deurenberg's formula of weight in Kilogram divided by the square of the height in meters.²⁴ In case of an exigency, safety of the patient was considered paramount with early conversion protocol from TEPP to open repair/TAPP (Trans-Abdominal Pre-Peritoneal) laparoscopic repair. In addition to the

conversion, intraoperative outcome measures included the surgical technique, the endovision/endoscopic vision (measured in visual analog score of 1-10), the ease of procedure (measured in visual analog score of 1-10), the operation time, the peritoneal injury, and the surgical emphysema and their correlations with the anatomic variations of the posterior rectus sheath. Postoperative outcome measures included the postoperative seroma, infection, chronic pain and the hernia recurrence and their correlations with the anatomic variations of the posterior rectus sheath.

Statistical package for social sciences (SPSS version 21) was utilized for the statistical analysis of the observed data. Data were computed as the Mean \pm SD (standard deviation) and a p-value of <0.05 was considered significant. All figures and tables are reproduced after slight modifications with permission from Ansari's thesis.²⁵

RESULTS

Table 1: Distribution of subtypes of posterior rectus sheath according to combined extent and morphology in patients undergoing TEPP hernioplasty.

PRS types (extent + morphology)	Hernias		Patients	
	N	%	N	%
NWT	31	45.6	27	45.00
V-PRS	37	54.4	33	55.00
Total	68	100	60	100
V-PRS subtypes	N	%	N	%
SWT	3	8.1	3	9.1
LWT	3	8.1	2	6.1
CWT	6	16.2	6	18.2
CMT	1	2.7	1	3.0
NPT	8	21.6	7	21.2
LPT	7	18.9	7	21.2
CPT	1	2.7	OS	-
NTO	1	2.7	1	3.0
CTO	3	8.1	3	9.1
NGA	1	2.7	OS	-
CGA	3	8.1	3	9.1
Total	37	100	33	100

TEPP, total extraperitoneal preperitoneal; PRS, posterior rectus sheath; NWT, classical normal-length whole-tendinous PRS; V-PRS, variant PRS; SWT, short whole-tendinous PRS; LWT, long whole-tendinous PRS; CWT, complete whole-tendinous PRS; CMT, complete musculo-tendinous; NPT, normal-length partly tendinous; LPT, long partly-tendinous PRS; CPT, complete partly-tendinous PRS; NTO, normal-length thinned-out PRS; CTO, complete thinned-out PRS; NGA, normal-length grossly attenuated PRS; CGA, complete grossly attenuated PRS; OS, opposite side; (Reproduced with permission from Ansari's Thesis²⁵)

Three female patients with inguinal hernia presenting in the study period were not considered for the TEPP repair because of the presence of one or more exclusion criteria. Three out of 63 male patients were excluded from the

study because of an early conversion to the open/TAPP repair before sufficient details of the posterior rectus sheath could be documented. Reasons for conversion were early peritoneal injury by rather improper handling of first blunt trocar due to presence of a short posterior rectus sheath as detected on conversion to TAPP repair (1), early inadvertent injury to the deep inferior epigastric vessels by the rubbing with the roughened joint of Maryland dissector (1) and early excessive CO₂ retention with resultant anaesthetic problem (1). Thus, the TEPP hernioplasty was successfully completed in a total of 60 male adult patients only.

In the present study, the posterior rectus sheath (PRS) was documented in 12 subtypes one Classical subtype (46%), i.e., normal-length whole-tendinous (NWT), and 11 Variant subtypes (54%) (Table 1).

The Variant PRS included (1) SWT, short whole tendinous (4.4%), (2) LWT, long whole tendinous (4.4%), (3) CWT, complete-length whole tendinous (8.8%), (4) NPT, normal-length partly tendinous (11.8%), (5) LPT, long partly tendinous (10.3%), (6) NTO, normal-length thinned out (1.5%), (7) CTO, complete-length thinned out (4.4%), (8) NGA, normal-length grossly attenuated (1.5%), (9) CGA, complete-length grossly attenuated (4.4%), (10) CPT, complete-length partly tendinous (1.5%), and (11) CMT, complete-length musculo-tendinous (1.5%).

With respect to the PRS extent as well as PRS morphology, non-mirror anatomy of PRS was observed on the two sides of the body in 50% each; however, when PRS extent and morphology were considered together, non-mirror anatomy of PRS was documented on the two sides of the body in 75% of the 8 bilateral hernias who underwent bilateral TEPP hernioplasty (Table 2).

Details of these anatomic variations of the posterior rectus sheath (PRS) proved exhaustive and hence have been reported separately elsewhere;¹⁷ only their surgical significance and implications are outlined in the following paragraphs.

Demographic characteristics of patients

Mean age of the patients was 50.1 \pm SD (17.2) years (Range 18-80 years). Mean BMI of the patients was 22.6 \pm SD-2.0kg/m² (Range 19.5-31.2kg/m²). Patients were by profession manual labourers (n=24), retired persons (n=9), office workers (n=8), students (n=7), farmers (n=6) and field workers (n=6).

In the present study, the posterior rectus sheath (PRS) anatomy did not vary with respect to the age and profession of the patients but did vary significantly with respect to their BMI, with short tendinous PRS occurring mainly in the overweight/ obese patients, the details of which has been reported elsewhere by the author.¹⁷

Table 2: anatomy of posterior rectus sheath (PRS) in patients with bilateral inguinal hernias who underwent bilateral TEPP hernioplasty.

PRS extent		PRS extent subtypes		PRS morphology		PRS extent and morphology	
Right side	Left side	Right side	Left side	Right side	Left side	Right side	Left side
IC	IC	NIC	NIC	PT	PT	NPT	NPT
IC	1C	NIC	NIC	WT	WT	NWT	NWT
C	C	C	C	GA	PT*	CGA	CPT*
C	IC*	C	NIC*	WT	WT	CWT	NWT*
C	IC*	C	NIC*	WT	GA*	CWT	NGA*
IC	IC*	LIC	NIC*	WT	WT	LWT	NWT*
IC	IC	NIC	NIC	PT	WT*	NPT	NWT*
IC	IC	LIC	NIC*	WT	WT	LWT	NWT*

IC, incomplete PRS; C, complete PRS; NIC, normal-length incomplete PRS; LIC, long incomplete PRS; PT, partly-tendinous PRS; WT, whole-tendinous PRS; GA, grossly attenuated; NPT, normal-length partly-tendinous PRS; NWT, normal-length whole-tendinous PRS; CPT, complete partly-tendinous PRS; NGA, normal-length grossly attenuated PRS; *Different PRS type shown in red on contralateral side; (Reproduced with permission from Ansari's Thesis²⁵)

Table 3: Effect of anatomical variations of posterior rectus sheath on endovision during TEPP hernioplasty.

Variable	Subgroups	N	Endovision mean±SD* (VAS) [§]	CID [¶]	**t-value	Sig. (2-tailed)	p-value
PRS extent	Incomplete	54	8.20±1.33	2.97	10.095	0.000	<0.001
	Complete	14	4.50±0.59	4.44			
PRS morphology	Classical	37	8.14±1.82	0.651	3.487	0.001	<0.01
	Variant	31	6.61±1.75	2.394			
Total		68					

PRS, posterior rectus sheath; *SD, standard deviation; §VAS, visual analog score (1-10); ¶CID, 95% confidence interval of the difference; **t, independent-sample t-test value; BMI, body mass index; TEPP, total extraperitoneal preperitoneal; PRS, posterior rectus sheath; R-Fascia, rectus fascia; (Reproduced with permission from Ansari's Thesis²⁵)

Table 4: Effect of anatomical variations of posterior rectus sheath on ease of procedure (EOP) during TEPP hernioplasty (N = 68).

Variable	Subgroups	N	EOP ^φ mean±SD* (VAS) [§]	C.I.D [¶]	**t-value	Sig. (2-tailed)	p-value
PRS extent	Incomplete	54	7.94±1.73	2.2687	6.754	0.000	<0.001
	Complete	14	4.71±0.75	4.1731			
PRS morphology	Classical	37	8.28±1.85	1.3748	5.247	0.000	<0.001
	Variant	31	6.07±1.60	3.0637			

TEPP, total extraperitoneal preperitoneal; ¶PRS, posterior rectus sheath; φEOP, ease of procedure; *SD, standard deviation; §VAS, visual analog score (1-10); ¶CID, 95% confidence interval of the difference; **t, independent-sample t-test value; Sig., significance value; (Reproduced with permission from Ansari's Thesis²⁵)

Table 5: Effect of anatomical variations of posterior rectus sheath on operation time during TEPP hernioplasty.

Variable	Subgroups	N	OT [§] mean±SD* (hours)	C.I.D [¶]	**t-value	Sig. (2-tailed)	p-value
PRS extent	Incomplete	54	1.80±0.59	-0.660	-1.776	0.080	>0.05
	Complete	14	2.12±0.55	0.0385			
PRS morphology	Classical	37	1.68±0.54	-0.680	-2.972	0.004	<0.01
	Variant	31	2.09±0.58	-0.133			

TEPP, total extraperitoneal preperitoneal; ¶PRS, posterior rectus sheath; §OT, operation time; *SD, standard deviation; ¶CID, 95% confidence interval of the difference; **t, independent-sample t-test value; Sig., significance value; (Reproduced with permission from Ansari's Thesis²⁵)

Modification in surgical technique

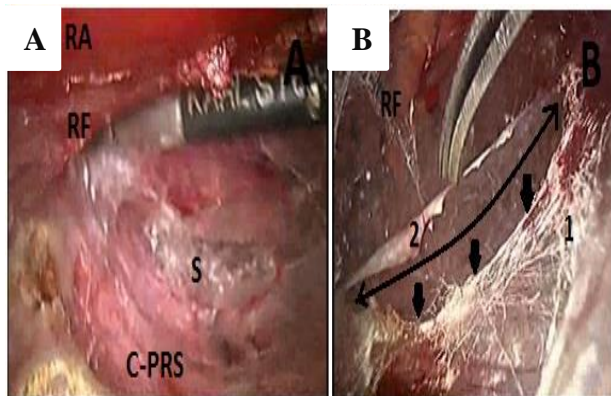
Under the standard posterior rectus approach for TEPP hernioplasty for the inguinal hernia, in presence of the classical incomplete PRS with a well-defined arcuate

line, the telescope is easily guided into the preperitoneal space just below the arcuate line and then further dissection becomes avascular and straightforward. However, the surgical technique was required to be modified in three situations encountered in the present study, namely, presence of complete posterior rectus

sheath (C-PRS), presence of long posterior rectus sheath (L-PRS) and presence of asymmetrical PRS anatomy on the contralateral side.

Creation of artificial arcuate line in presence of a complete PRS

As the complete PRS (C-PRS) was extending up to the pubic bone, an artificial arcuate was required to be created surgically by a combination of blunt/sharp dissection at about the level of the middle working port in order to gain entry into the requisite preperitoneal space and to get ample room for further definitive dissection (Figure 2).

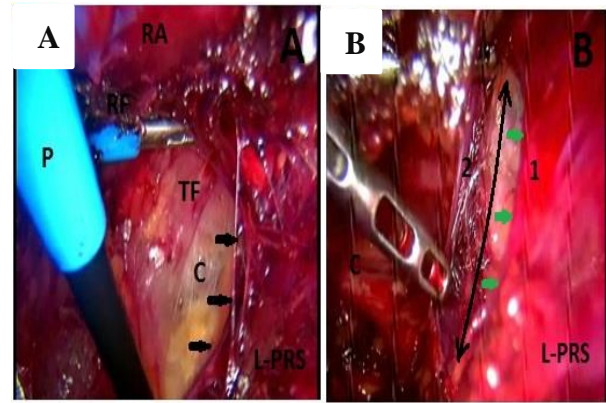


Double-headed arrow, indicates rent created surgically in the C-PRS; Single-headed Arrows, indicate lower border of the proximal part of the C-PRS, representing the artificial arcuate line; RA, rectus abdominis muscle visible partly; RF, rectus fascia covering the rectus abdominis muscle; S, sign of lighthouse faintly visible in the depth of the posterior rectus canal; (Reproduced with permission from Ansari's Thesis²⁵)

Figure 2: Creation of artificial arcuate line in the complete posterior rectus sheath; (A): Shows a complete posterior rectus sheath (C-PRS) extending up to the pubic bone without formation of an arcuate line; (B): Shows an artificial arcuate line created surgically in the C-PRS at about the level of middle working port.

Creation of artificial secondary arcuate line in presence of a long PRS

Presence of a long PRS (L-PRS) posed two problems. Firstly, as the arcuate low was found low in this situation, it increased the effective rectus sheath canal as reported earlier by the author, resulting in severe ergonomic problems for the laparoscopic instruments due to the wide fulcrum effects.¹⁸ Secondly, the working space for manoeuvring as well as creation of adequate space for mesh placement was found severely restricted due to the low lying arcuate line if the dissection was tried the below the low arcuate line. Therefore, creation of an artificial secondary arcuate line surgically was warranted in order to proceed for development of an adequate and proper preperitoneal space, a scenario similar to that of a complete posterior rectus sheath (Figure 3).



Double-headed Arrow, indicates rent created surgically in the L-PRS; Single-headed Arrows, indicate lower border of the proximal part of the L-PRS, representing the artificial secondary arcuate line; RA, rectus abdominis muscle visible partly; RF, rectus fascia covering the rectus abdominis muscle; C, corona mortis faintly visible on the pectineal ligament in the depth of the posterior rectus canal; (Reproduced with permission from Ansari's Thesis²⁵)

Figure 3: Creation of artificial arcuate line in the long posterior rectus sheath; (A) Shows a long posterior rectus sheath (L-PRS) extending just short of pubic bone with formation of a very low arcuate line; (B) Shows an artificial secondary arcuate line created surgically in the L-PRS at about the level of the middle working port.

False sense of security on contralateral surgery

With respect to the PRS extent (asymmetrical in 50%), there were two cases of long incomplete PRS (LIC) on the contralateral side against the classical PRS (NIC) who required creation of an artificial secondary arcuate line more proximally, and there were two cases of the complete PRS (C-PRS) on the contralateral side against the classical PRS (NIC) who required creation of an artificial arcuate line more at the level of the middle working port.

Asymmetry of the PRS morphology (37.5%) did not warrant change in the surgical technique except for more careful gentle dissection in view of the variably attenuated PRS on the opposite side in these cases.

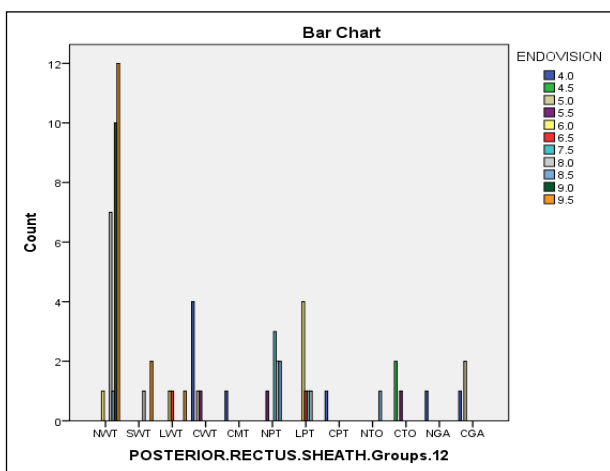
Conversion

Overall incidence of conversion in the present study was 4.8 % of 63 patients posted for the TEPP hernioplasty.

However, only one out of the three conversions were found secondary to the anatomic variation of the short posterior rectus sheath with a high arcuate line which was detected on conversion to TAPP approach and visualized with a 5mm telescope through the lateral working port, resulting in an incidence of 33.3% of all conversions, or 1.6% of 61 patients if other two conversions secondary to the different reasons were excluded.

Endoscopic vision (Endovision)

Overall mean endovision in terms of the visual analog score (VAS) of 1-10 was $8.20 \pm SD (1.33)$ VAS (Range 4.0-9.5 VAS). Difference in endovision between the cases with the complete posterior rectus sheath (C-PRS) and incomplete posterior rectus sheath (IC-PRS) was highly significant statistically ($p < 0.001$) (Table 3). Cases with three subtypes of the incomplete PRS (Classical incomplete (NIC), Low Incomplete (LIC) and Short Incomplete (SIC)) had different degrees of endovision with high statistical significance (ANOVA $F=9.162$, Sig. 0.000, $p < 0.001$), with endovision significantly much lower in LIC group ($p < 0.01$) as compared to the NIC and SIC subgroups of the incomplete PRS, while the endovision was comparable between the NIC and SIC subgroups ($p > 0.05$).



NWT, normal-length whole-tendinous(Classical); SWT, short whole- tendinous; LWT, long whole-tendinous; CWT, complete whole-tendinous; CMT, complete musculo-tendinous; NPT, normal-length partly tendinous; LPT, long partly-tendinous; CPT, complete partly-tendinous; NTO, normal-length thinned-out; CTO, complete thinned-out; NGA, normal-length grossly attenuated; CGA, complete grossly attenuated; (Pearson CHISQ CC: $R=236.696$, df 110, Sig. 0.000, $p < 0.001$; Likelihood Ratio: $R=152.403$, df 110, Sig. 0.005, $p < 0.01$; Linear-by-Linear Association: $R=31.897$, df 1, Sig. 0.000, $p < 0.001$); (Reproduced with permission from Ansari's Thesis²⁵)

Figure 4: Correlation between the endovision and the posterior rectus sheath.

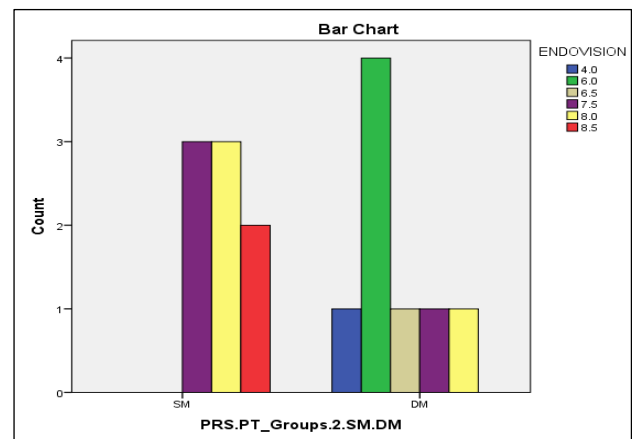
Endovision differed very significantly ($p < 0.01$) between the cases of the classical anatomy (NWT, normal-length whole tendinous incomplete PRS) and the cases of the variant anatomy (V-PRS) of the posterior rectus sheath (Table 3). With respect to various subgroups of Variant-PRS morphology, the endovision in cases of the classical PRS was found statistically different ($p < 0.05$) from that of cases of the grossly-attenuated PRS (GA-PRS) and the Partly-Tendinous (PT)/ Thinned-Out (TO) PRS; however, endovision in GA-PRS subgroup was not significantly different ($p > 0.05$) from other variant subgroups of the PRS, namely, PT/TO, Long Partly-Tendinous (LPT), Long Whole-Tendinous (LWT), Short Whole-Tendinous

(SWT), and Musculo-Tendinous (MT) which were also not significantly different from each other ($p > 0.05$) with respect to the endovision. Endovision was also found significantly different among the 12 subgroups of the PRS based on the combined features of the PRS extent and morphology; their associations were very strong statistically (Figure 4).

In presence of the double-layer PRS, the endovision was significantly lower in comparison to that of single-layer PRS in the PT-subgroup of the posterior rectus sheath (Figure 5).

Ease of procedure (EOP)

Overall mean EOP (ease of procedure) in terms of the visual analog score (VAS) of 1-10 was 7.27 ± 2.05 VAS (Range 4.0-9.5 VAS). Ease of procedure (EOP) between complete and incomplete PRS groups was different statistically ($p < 0.001$) (Table 4).

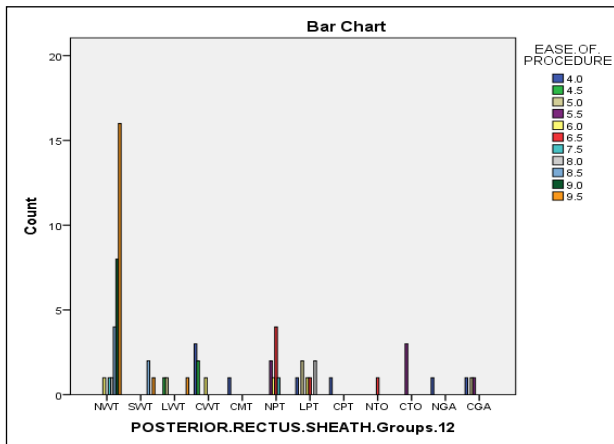


SM, single membranous; DM, double membranous; (Independent-Sample t-test: CID, 0.7275-2.6475, df 14, $t=3.770$, Sig. 0.002, $p < 0.01$); Pearson CHISQ CC: ($R = 10.000$, df 5, Sig. 0.075, $p > 0.05$); Likelihood Ratio: ($R=13.183$, df 5, Sig. 0.022, $p < 0.05$); Linear-by-Linear Association: ($R=7.557$, df 1; Sig. 0.006, $p < 0.01$); (Reproduced with permission from Ansari's Thesis²⁵)

Figure 5: Correlation between endovision and types of PRS-PT (partly tendinous posterior rectus sheath).

The EOP was also significantly different ($p < 0.01$) between the Classical morphology and the Variant morphology of the posterior rectus sheath. Post Hoc Tests (Tukey HSD) showed that the EOP in the classical PRS category was, in reality, different significantly from the GA and PT/TO groups only but not from the Short-PRS (SWT) or Long-PRS (LWT/LPT). However, there was no statistical difference among the various Variant PRS morphologies with respect to the EOP except between the SWT and GA subgroups which were found statistically different ($p < 0.05$) from each other. Pearson Chi Square correlation of the EOP was also highly significant ($p < 0.001$) for both the PRS extent and the PRS morphology (Figure 6).

In presence of the double-layer PRS, the EOP was not significantly different ($p > 0.05$) in comparison to that of single-layer PRS in the PT-subgroup of the posterior rectus sheath.



NWT, normal-length whole-tendinous (Classical); SWT, short whole-tendinous; LWT, long whole-tendinous; CWT, complete whole-tendinous; CMT, complete musculo-tendinous; NPT, normal-length partly tendinous; LPT, long partly-tendinous; CPT, complete partly-tendinous; NTO, normal-length thinned-out; CTO, complete thinned-out; NGA, normal-length grossly attenuated; CGA, complete grossly attenuated; (Pearson CHISQ CC: $R=196.266$, df 110, Sig. 0.000, $p < 0.001$; Likelihood Ratio: $R=150.550$, df 110, Sig. 0.006, $p < 0.01$; Linear-by-Linear Association: $R=35.805$, df 1, Sig. 0.000, $p < 0.001$); (Reproduced with permission from Ansari's Thesis²⁵)

Figure 6: Correlation between the EOP and 12 subtypes of PRS.

Operation time (OT)

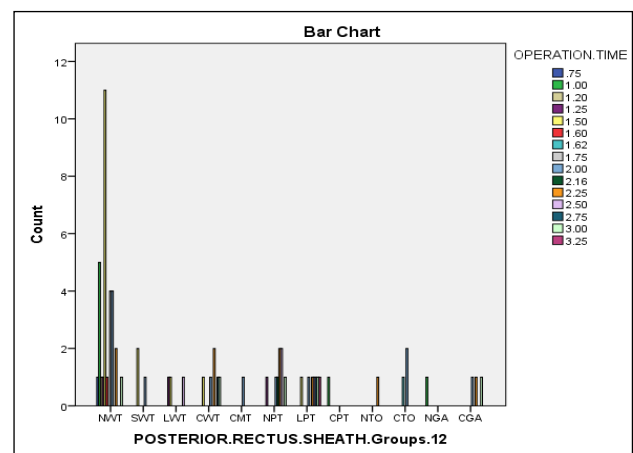
Overall mean OT in the present study was 1.87 ± 0.59 hours (Range 0.75-3.25 hours). With respect to the vertical extent of the posterior rectus sheath (PRS), there was no significant difference ($p > 0.05$) in the operation time between the complete PRS and incomplete PRS subgroups; however, with respect to the morphology of the posterior rectus sheath (PRS), the difference in the operation time between the Classical PRS and Variant PRS subgroups (PT/TO, GA, SWT, LPT, LWT, MT) was very significant ($p < 0.01$) (Table 5).

Post hoc tests (Tukey HSD) analysis showed a significant difference ($p < 0.05$) in the operation time between the Classical PRS morphology (NWT) and the Partly Tendinous PRS (PRS-PT); however, no statistical difference was found in the operation time either between the Classical morphology and other Variants, or among the different Variants of PRS morphology. The Pearson Chi-Square analysis also did not reveal any significant correlation between the operation time and the 12 groups of PRS anatomy (combined extent and morphology), although their linear association was very significant ($p < 0.01$) (Figure 7).

In presence of the double-layer PRS, the operation time was not significantly different ($p > 0.05$) in comparison to that of single-layer PRS in the PT-subgroup of the posterior rectus sheath.

Peritoneal injury (PI)

In the present study, intra-operative peritoneal injury (PI) during the TEPP hernioplasty occurred in 17 out of 60 patients, resulting in an overall incidence of 28.3%. Incidence of the peritoneal injury (PI) was not different significantly between the Classical and Variant types of the posterior rectus sheath (Table 6). Post Hoc Tests (Tukey HSD) also did not reveal any significant differences among the different Variant subgroups of the posterior rectus sheath.



NWT, normal-length whole-tendinous (Classical); SWT, short whole-tendinous; LWT, long whole-tendinous; CWT, complete whole-tendinous; CMT, complete musculo-tendinous; NPT, normal-length partly tendinous; LPT, long partly-tendinous; CPT, complete partly-tendinous; NTO, normal-length thinned-out; CTO, complete thinned-out; NGA, normal-length grossly attenuated; CGA, complete grossly attenuated; (Pearson CHISQ CC: $R=132.937$, df 154, Sig. 0.889, $P > 0.05$; Likelihood Ratio: $R=97.436$, df 154, Sig. 1.000, $p > 0.05$; Linear Association: $R=10.293$, df 1, Sig. 0.001, $p < 0.01$); (Reproduced with permission from Ansari's Thesis²⁵)

Figure 7: Correlation between operation time and types of posterior rectus sheath.

Surgical emphysema (Emphy)

In the present study, intra-operative surgical emphysema developed in 11 out of 68 TEPP hernioplasties, leading to an overall incidence of 16.2%. With respect to the two groups of the PRS extent (incomplete vs. complete), there was no significant difference in the incidence of the surgical emphysema (Table 7). Post Hoc Tests (Tukey HSD) analysis also did not show any significant difference among the 3 variant types (LIC, SIC and C) of the PRS extent. However, the occurrence of the surgical emphysema was significantly more ($p < 0.05$) in presence of the Variant morphology (PT, TO, GA, MT) of the posterior rectus sheath (V-PRS) as compared to that of

the classical PRS (NWT) (Table 7) (Figure 8). When the morphology and extent of the PRS were considered together, significant difference was found in the incidence of the surgical emphysema among the 12 subtypes, and the Pearson Chi-Square Correlations also revealed very significant difference among them (Figure 9).

Post-operative seroma

Present study documented occurrence of post-operative seroma in 7 out of 68 cases of the TEPP hernioplasty, resulting in an incidence of 10.3%. The incidence of the seroma was not different significantly ($p>0.05$) between the classical and variant types of the posterior rectus (Table 8).

Table 6: Effect of anatomical variations of posterior rectus sheath on peritoneal injury during TEPP hernioplasty.

Variable	Subgroups	N	P. injury [§] Mean±SD*	C.I.D. [¶]	**t-value	Sig. (2-tailed)	p-value
PRS Extent	Incomplete	54	0.20 ± 0.41	-0.482	-1.745	0.086	>0.05
	Complete	14	0.43 ± 0.51	0.032			
PRS Morphology	Classical	37	0.19 ± 0.40	-0.345	-1.261	0.212	>0.05
	Variant	31	0.32 ± 0.48	-0.078			

TEPP, total extraperitoneal preperitoneal; PRS, posterior rectus sheath; §P. Injury, peritoneal injury; *SD, standard deviation; CID, 95% confidence interval of the difference; **, independent-sample t-test value; Sig., significance value; (Reproduced with permission from Ansari's Thesis²⁵)

Table 7: Effect of anatomical variations of posterior rectus sheath on surgical emphysema during TEPP hernioplasty (N = 68).

Variable	Subgroups	N	§Emphysema Mean±SD*	C.I.D.	**t-value	Sig. (2-tailed)	p-value
PRS extent	Incomplete	54	0.13±0.34	-0.377	-1.413	0.162	>0.05
	Complete	14	0.29±0.47	0.064			
PRS morphology	Classical	37	0.08±0.28	-0.353	-2.003	0.049	<0.05
	Variant	31	0.26±0.45	0.001			

TEPP, total extraperitoneal preperitoneal; PRS, posterior rectus sheath; §Emphysema, surgical/subcutaneous emphysema; *SD, standard deviation; CID, 95% confidence interval of the difference; **, independent-sample t-test value; Sig., significance value; (Reproduced with permission from Ansari's Thesis²⁵)

Table 8: Effect of anatomical variations of posterior rectus sheath on postoperative seroma in patients undergoing TEPP hernioplasty (N = 68).

Variable	Subgroups	N	Seroma Mean±SD*	C.I.D.	**t-value	Sig.(2-tailed)	p-value
PRS extent	Incomplete	54	0.07±0.26	-0.322	1.543	0.128	>0.05
	Complete	14	0.21±0.43	0.041			
PRS morphology	Classical	37	0.08±0.28	-0.197	-0.640	0.524	>0.05
	Variant	31	0.13±0.34	0.102			

TEPP, total extraperitoneal preperitoneal; PRS, posterior rectus sheath; *SD, standard deviation; CID, 95% confidence interval of the difference; **, independent-sample t-test value; Sig., significance value; (Reproduced with permission from Ansari's Thesis²⁵)

Table 9: Significance of anatomic variations of posterior rectus sheath on the functional outcomes in patients (N=60) undergoing TEPP hernioplasty (N=68).

Variables	Subgroups	N	Endo	EOP	OT	PI	Emphy	Serom
PRS extent	Incomplete	54	<0.001	<0.001	>0.05	>0.05	>0.05	>0.05
	Complete	14						
PRS morphology	Classical	37	<0.01	<0.001	<0.01	>0.05	<0.05	>0.05
	Variant	31						

TEPP, total extraperitoneal preperitoneal; §PRS, posterior rectus sheath; Endo, endovision; EOP, ease of procedure; OT, operation time; PI, peritoneal injury; Emphy, surgical emphysema; Serom, postoperative seroma; TEPP, total extra-peritoneal preperitoneal hernioplasty; PRS, posterior rectus sheath; R-Fascia, rectus fascia; (Reproduced with permission from Ansari's Thesis²⁵)

Post-operative infection

Postoperative superficial infection at the port site was observed in 4 out of 60 patients, leading to an incidence of 6.7% in the present study. All of them were mild in

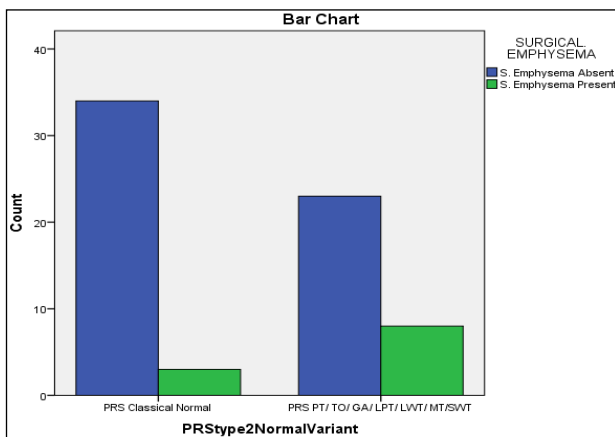
nature and resolved with simple dressings and antibiotic treatment in 3-5 days. No other type of sepsis was observed in the present study. Incidence of postoperative infection did not differ significantly with respect to the various subtypes of the posterior rectus sheath anatomy.

Post-operative chronic inguinal pain

In 1 out of 60 patients (exactly the 43rd in the consecutive order), the moderate pain in the groin radiating to the ipsilateral testis, suggestive of an injury to the genital branch of the genito-femoral nerve, persisted beyond 3 months, requiring oral analgesics often. Video review suggested the possibility of this nerve injury during the parietalization of the cord structures. The pain resolved almost fully with conservative treatment in about 9 months' time. This patient had a variant PRS in the form of normal-length partly tendinous type (NPT-PRS).

Recurrence of hernia

There was no recurrence of inguinal hernia after TEPP hernioplasty in the mean follow-up period of $33 \pm \text{SD}$ (17) months (Range 5-61 months) in the present study.



PT, Partly-Tendinous PRS; TO, Thinned-Out Throughout PRS; GA, Grossly Attenuated PRS; LPT, Long Partly Tendinous PRS; LWT, Long Whole-Tendinous PRS; MT, Musculo-Tendinous PRS; SWT, Short Whole-Tendinous PRS; (Pearson CHISQ CC: $R=3.896$, df 1, Sig. 0.048, $p < 0.05$; Likelihood Ratio: $R=3.964$, df 1, Sig. 0.046, $p < 0.05$; Linear-by-Linear Association: $R=3.839$, df 1; Sig. 0.050, $p > 0.05$); (Reproduced with permission from Ansari's Thesis²⁵)

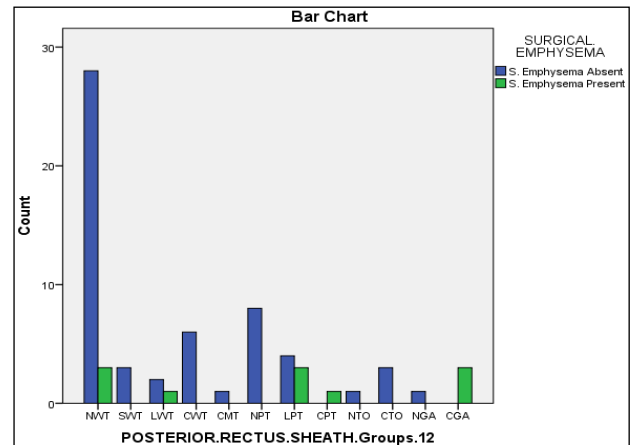
Figure 8: Correlation of incidence of surgical emphysema between classical and variant PRS.

DISCUSSION

In the current era of evidence-based medicine where each and every bit of information about the human body is researched and cross-examined, it appears strange to document that to the best of the knowledge, there is no clinical report cited in the literature regarding the clinical/surgical significance of the anatomic variations in the posterior rectus sheath, despite the present revolution of the laparoscopic surgery encompassing almost all parts of the body. Therefore, the discussion is limited to their own data only in the following paragraphs.

Present study found a significant difference in the degree of endoscopic vision (endovision) and the EOP among

the 12 subtypes of posterior rectus sheath anatomy in general (Figure 4 and 6) (Table 3 and 4). During analysis of the PRS extent variations only, the endovision and the ease of procedure (EOP) were found significantly less in presence of the complete PRS as compared to the incomplete PRS (Figure 11 and 12); moreover, the endovision and EOP were also significantly less in presence of the long PRS as compared to the classical or short PRS. The variations in the PRS extent did not affect other functional outcomes of operation time, peritoneal injury, surgical emphysema, postoperative pain, infection and pain (Table 9).

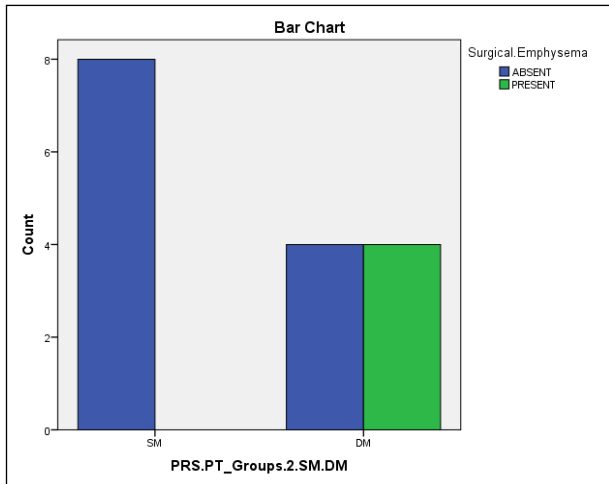


NWT, normal-length whole-tendinous; SWT, short whole-tendinous; LWT, long whole-tendinous; CWT, complete whole-tendinous; CMT, complete musculo-tendinous; NPT, normal-length partly tendinous; LPT, long partly-tendinous; CPT, complete partly-tendinous; NTO, normal-length thinned-out; CTO, complete thinned-out; NGA, normal-length grossly attenuated; CGA, complete grossly attenuated; (Pearson CHISQ CC: $R=30.458$, df 11, Sig. 0.001, $p < 0.01$; Likelihood Ratio: $R=27.100$, df 11, Sig. 0.004, $p < 0.01$; Linear-by-Linear Association: $R=7.293$, df 1, Sig. 0.007, $p < 0.01$); (Reproduced with permission from Ansari's Thesis²⁵)

Figure 9: Correlation between incidence of surgical emphysema and 12 subtypes of PRS morphology and extent.

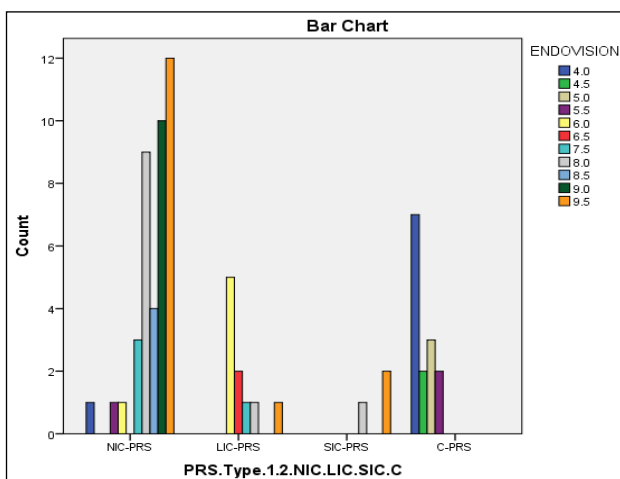
The secondary effects of the PRS morphology variations were differential in nature. Variant PRS morphology adversely affected not only the endovision and ease of procedure but also the OT and incidence of the surgical emphysema, although other complications (peritoneal injury, seroma, and wound infection) were not affected (Table 9). The various functional changes secondary to the variant anatomy of the posterior rectus sheath are illustrated in Figure 13.

It is of interest to note that in presence of a double-layer PRS, there was a reversal of phenomenon with respect to the endovision which was found significantly lower with strong association as compared to that observed in presence of the single layer PRS (Figure 5). All other functional parameters were either adversely affected (e.g., surgical emphysema) or not affected significantly in presence of a double-layer PRS.



SM, single membranous; DM, double membranous; (Independent-Sample t-test: (CID, -0.905 to -0.095, df 14, $t = -2.646$, Sig. 0.019, $p < 0.05$); Pearson CHISQ CC: $R = 5.333$, df 1, Sig. 0.021, $p < 0.05$; Likelihood Ratio: $R = 6.904$, df 1, Sig. 0.009, $p < 0.01$; Linear-by-Linear Association: $R = 5.000$, df 1; Sig. 0.025, $p < 0.05$); (Reproduced with permission from Ansari's Thesis²⁵)

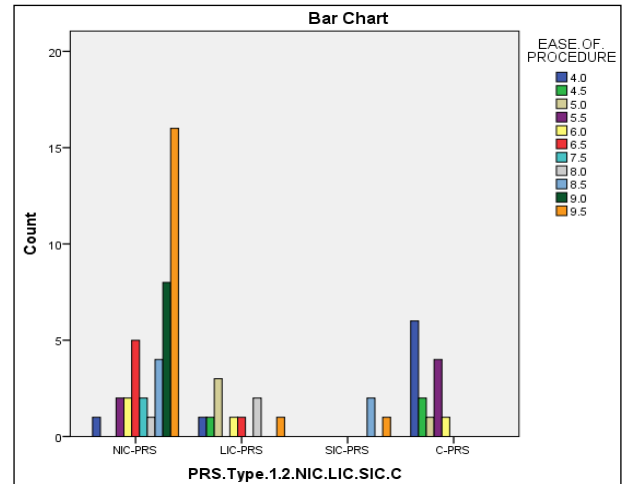
Figure 10: Correlation between incidence of the surgical emphysema and 2 Subtypes of PRS-PT.



PRS, posterior rectus sheath; NIC, classical incomplete; SIC, short incomplete; LIC, long incomplete; C-PRS, complete PRS; (Pearson CHISQ CC: $R = 101.444$, df 30, Sig. 0.000, $p < 0.001$; Likelihood Ratio: $R = 91.016$, df 30, Sig. 0.000, $p < 0.001$; Linear-by-Linear Association: $R = 39.354$, df 1, Sig. 0.000, $p < 0.001$); (Reproduced with permission from Ansari's Thesis²⁵)

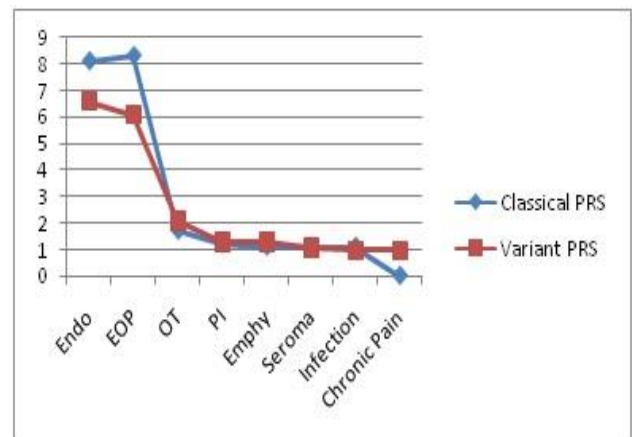
Figure 11: Correlation between the PRS extent and the endovision.

Present study has two limitations, Firstly, the present study is solely based on adult male patients only because the female patients could not be recruited in the study due to certain exclusion criteria although inguinal hernia is less common in the females. Secondly, the sample size of the present study is rather small in view of the fact that inguinal hernia repair inclusive of both open and laparoscopic techniques is the most common general surgical procedure performed worldwide.²⁵⁻²⁹



PRS, posterior rectus sheath; NIC, classical incomplete; SIC, Short incomplete; LIC, long incomplete; C-PRS, complete PRS; (Pearson CHISQ CC: $R = 77.810$, df 30, Sig. 0.000, $p < 0.001$; Likelihood Ratio: $R = 74.565$, df 30, Sig. 0.000, $p < 0.001$; Linear-by-Linear Association: $R = 28.774$, df 1, Sig. 0.000, $p < 0.001$); (Reproduced with permission from Ansari's Thesis²⁵).

Figure 12: Correlation Between PRS Extent and EOP (ease of procedure).



PRS, posterior rectus sheath; Endo, endovision; EOP, ease of procedure; OT, operation time; PI, peritoneal injury; Emphy, emphysema; (Reproduced with permission from Ansari's Thesis²⁵)

Figure 13: Correlation between PRS anatomy and functional outcome measures.

CONCLUSION

Anatomic variations in the PRSs are frequent in both its extent and morphology, and warrant due respect because of their significant intraoperative surgical implications and postoperative clinical consequences.

Keen observation, timely recognition of anatomic variations and judicious dissection are essential keys and are strongly recommended to reach the requisite surgical pre-peritoneal space in order to minimize complications and to improve faster learning for smooth conduct of the well-organized TEPP hernioplasty with ease, safety,

rapidity and better results, features which are crucial in popularising the well-proven technique with low failure rate, reduced post-operative pain, infection, and early return to activity/work.

The study confirmed the opinion of Kathkouda that the anatomic knowledge of abdominal wall aponeurosis, especially the posterior rectus sheath, is of paramount importance for the seamless TEPP hernia repair.

Funding: No funding sources

Conflict of interest: None declared

Ethical approval: The study was approved by the Institutional Ethics Committee

REFERENCES

- Brooks JD. Applied Laparoscopic Anatomy: Abdomen and Pelvis. 1997;158(2):681-2.
- Li LJ, Zheng XM, Jiang DZ, Zhang W, Shen HL, Shan CX, et al. Progress in Laparoscopic Anatomy Research: A Review of the Chinese Literature. World J Gastroenterol. 2010;16(19):2341-7.
- Marks SC, Gilroy AM, Page DW. The clinical anatomy of laparoscopic inguinal hernia repair. Singapore Med J. 1996;37(5):519-21.
- Spaw AT, Ennis BW, Spaw LP. Laparoscopic hernia repair: the anatomic basis. J Laparoendoscopic Surg. 1991;1:269-77.
- Rosser J. The anatomical basis for laparoscopic hernia repair revisited. Surg Laparosc Endosc. 1994;4(1):36-44.
- Avisse C, Delattre JF, Flament JB. The inguinofemoral area from a laparoscopic standpoint. History, anatomy, and surgical applications. Surg Clin North Am. 2000;80(1):35-48.
- Faure JP, Doucet C, Rigourd PH, Richer JP, Scepti M. Anatomical pitfalls in the technique for total extra peritoneal laparoscopic repair for inguinal hernias. Surg Radiol Anat. 2006;28(5):486-93.
- Lange JF, Rooijens PPGM, Koppert S, Kleinrensink GJ. The preperitoneal tissue dilemma in totally extraperitoneal (TEP) laparoscopic hernia repair. Surg Endosc. 2002;16:927-30.
- Colborn GL, Skandalakis JE. Laparoscopic inguinal anatomy. Hernia. 1998;2:179-91.
- Arregui ME. Surgical anatomy of the pre-peritoneal fasciae and posterior transversalis fasciae in the inguinal region. Hernia. 1997;1:101-10.
- Liem MS, van Steensel CJ, Boelhouwer RU, Weidema WF, Clevers G J, Meijer WS, et al. The learning curve of totally extraperitoneal laparoscopic hernia repair. Am J Surg. 1996;171:281-5.
- Rizk NN. A new description of the anterior abdominal wall in man and mammals. J Anat. 1980;131(3):373-85.
- Monkhouse WS, Khalique A. Variations in the composition of the human rectus sheath: a study of the anterior abdominal wall. J Anat. 1996;145:61-6.
- Mwachaka P, Odula P, Awori K, Kaisha. Variations in the Pattern of Formation of the Abdominis Rectus Muscle Sheath among Kenyans. Int J Morphol. 2009;27(4):1025-9.
- Mwachaka PM, Saidi HS, Odula PQ, Awori KO, Kaisha WO. Locating the arcuate line of Douglas: is it of surgical relevance. Clin Anat. 2010;23(1):84-6.
- Bendavid R. The transversalis fascia: new observations. In: Robert Bendavid, Jack Abrahamson, Maurice E. Arregui, Jean Bernard Flament, Edward E. Phillips (eds.) Abdominal Wall Hernias: Principles and Management. Springer-Verlag, New York; 2001:97-100.
- Ansari MM. Posterior Rectus Sheath: A Prospective Study of Laparoscopic Live Surgical Anatomy during TEPP Hernioplasty. World J Lap Surg. 2017;10(3).
- Ansari MM. Effective Rectus Sheath Canal: Does It Affect TEP Approach for Inguinal Mesh Hernioplasty. J Exp Integr Med. 2013;3(1):73-6.
- Ansari MM. Complete posterior rectus sheath and total extra-peritoneal hernioplasty. Saudi Surg J. 2014;2(4):80-3.
- Ansari MM. Arcuate Line Variations: Are they important for TEP surgeons? Kuwait Med J. 2015;47(4):313-6.
- Ansari MM. Rectus Fascia: A New Entity of Laparoscopic Live Surgical Anatomy. Open Access J Surg. 2017;3(4):1-5.
- Ansari MM. Surgical significance of rectus fascia during TEPP hernioplasty. Int. J Sci Appl Res. 2017;4(7):13-21.
- Ansari MM. Arcuate Line of Douglas: A Prospective Study of Laparoscopic Live Surgical Anatomy during TEPP Hernioplasty. Int J Sci Res. 2017;6(6):2348-63.
- Deurenberg P, Weststrate JA, Seidell JC. Body mass index as a measure of fatness: age- and sex-specific prediction formulas. Br J Nutr. 1991;65:105-14.
- Ansari MM. Thesis for PhD (Surgery) titled- 'A Study of Laparoscopic Surgical Anatomy of Infraumbilical Posterior Rectus Sheath, Fascia Transversalis and Pre-Peritoneal Fat/Fascia during TEPP Mesh Hernioplasty for Inguinal Hernia', Aligarh Muslim University, Aligarh, India, 2016'.
- Bittner R, Arregui ME, Bisgaard T, Dudai M, Ferzli GS, Fitzgibbons RJ, et al. Guidelines for laparoscopic (TAPP) and endoscopic (TEP) treatment of inguinal Hernia. Surg Endosc. 2011;25(9):2773-843.
- Putnis S, Berney CR. Totally extraperitoneal repair of inguinal hernia: techniques and pitfalls of a challenging procedure. Langenbecks Arch Surg. 2012;397:1343.
- Berger D. Evidence-Based Hernia Treatment in Adults. Deutsches Ärzteblatt Int Dtsch Arztebl Int. 2016;113:150-8.
- Kathkouda N. Advanced Laparoscopic Surgery: Techniques and Tips. 2nd Ed. London, Springer; 1998:149-168.

Cite this article as: Ansari MM. Posterior rectus sheath variations: surgical significance and clinical implications for laparoscopic hernia surgeons. *Int Surg J* 2018;5:683-94.