

Original Research Article

Management of iatrogenic bile duct injury in cholecystectomy: a single centre experience

Mohit Sharma*, Rachhpal Singh, Neeti Rajan Singh

Department of Surgery, Sri Guru Ram Das Institute of Medical Sciences and Research, Vallah, Amritsar, India

Received: 13 October 2016

Accepted: 17 October 2016

***Correspondence:**

Dr. Mohit Sharma,

E-mail: drmohit.gis@gmail.com

Copyright: © the author(s), publisher and licensee Medip Academy. This is an open-access article distributed under the terms of the Creative Commons Attribution Non-Commercial License, which permits unrestricted non-commercial use, distribution, and reproduction in any medium, provided the original work is properly cited.

ABSTRACT

Background: Iatrogenic bile duct injury during cholecystectomy is associated with high morbidity and is a potentially life threatening complication. The aim of the study was to present single centre experience in managing bile duct injuries and outcome after surgical repair.

Methods: The study was retrospective analyses of prospectively collected data. Bile duct injury patients admitted from June 2010 to August 2016 were studied. Following patient characteristics were studied demography, indication of surgery, laparoscopic or open cholecystectomy, conversion (done or not), clinical presentation, evaluation, management and outcome. Strasberg classification system was used to classify bile duct injury patients. Patients were categorized in three groups depending upon time of presentation. Group I- patients detected intraoperatively. Patients presenting within 2 weeks of cholecystectomy were categorized as Group II. Group III- Cases admitted after 2 weeks of cholecystectomy. Regular follow up was done every 6 months.

Results: Regular follow up every 6 months was done in all the patients. Mean follow up period was 24.5 months (1-60 months). In summary of the 14 patients requiring hepaticojejunostomy 1 required revision surgery (poor outcome), rest of the 13 patients had excellent outcome.

Conclusions: Minor bile duct injuries can be managed successfully with endoscopic and stenting. Major injuries can be managed optimally with Roux-en-Y hepaticojejunostomy with good long term results.

Keywords: Bile duct injury, Complications, Laparoscopic cholecystectomy, Roux-en-Y hepaticojejunostomy

INTRODUCTION

The bile duct injury is defined as damage to biliary tree in form of leak, stricture, ligation or transection of the ductal system. Cholecystectomy is one of the most common surgical procedure performed worldwide and therefore commonest cause for iatrogenic biliary tract injury. Incidence of bile duct injury following open cholecystectomy is 0.1-0.2%. However with the advent of laparoscopic cholecystectomy there has been increase incidence to the rate of 0.6-0.7%.¹ Bile duct injuries are associated with significant morbidity and is a potentially fatal complication. Numerous studies have stressed upon

the need of management at specialized hepatobiliary surgery centre for optimal outcome.²⁻⁴ The present study is retrospective analysis of bile duct injury patients managed in our surgical unit.

METHODS

This study was retrospective analysis of prospectively collected database of post cholecystectomy bile duct injury patients. From June 2010 to August 2016, 32 patients with bile duct injury were managed in our unit. Following patient characteristics were studied demography, indication of surgery, laparoscopic or open

cholecystectomy, conversion (done or not), clinical presentation, evaluation, management and outcome. Strasberg classification system was used to classify bile duct injury patients. Patients were categorized in three groups depending upon time of presentation. Group I- Patients detected intraoperatively. Patients presenting within 2 weeks of cholecystectomy were categorized as Group II. Group III - cases admitted after 2 weeks of primary surgery. In patients detected intraoperatively laparoscopic procedure was converted to laparotomy. On table cholangiography was done to delineate the entire biliary tree. Partial transections were repaired with polydioxanone 4-0 suture. In complete transections Roux-en-Y hepaticojejunostomy with wide stoma (2.5 cm in length) over left hepatic duct was done. Duct to mucosa technique using interrupted polydioxanone 4-0 suture was used. For group II cases ultrasound abdomen was done to look for any intra-abdominal collection, status of biliary tree. In case of generalized fluid collection in peritoneum and features of peritonitis immediate laparotomy with midline incision was done. No attempt for any definitive biliary repair was attempted. Sub hepatic area was drained with wide bore drains with the aim of controlling sepsis and making controlled external biliary fistula. In case of localized fluid collection ultrasound guided drainage of collection was done. Magnetic resonance cholangiogram (MRC) was done to delineate biliary tree. In case of biliary leakage with intact biliary tree patients were subjected to endoscopic papillotomy and stent placement. In patients showing complete cut off of common hepatic duct, definitive repair was done after minimum waiting period of 6 weeks after control of sepsis and optimization of nutritional status. For group III patient ultrasound abdomen was done to exclude any collections. MRC was done to know the extent of injury. Definitive repair was done after 6 weeks with Roux-en-Y hepaticojejunostomy with technical details as mentioned.

The follow up of these patients were done every 6 months. Triad of criteria used was clinical assessment, liver function tests and radiological investigation (ultrasound scan of the abdomen). Outcome was graded in following categories excellent- no clinical symptoms, normal LFT, normal radiology, good- no clinical symptoms, mild derangement of LFT, mild radiological abnormality, fair- improved symptoms, abnormal LFT, abnormal radiology, poor- worse symptom, abnormal LFT, abnormal radiology.

RESULTS

From June 2010 to August 2016, 32 patients with postcholecystectomy bile duct injury were managed in our unit. There were 8 male and 24 female patients. Mean age was 46.03 (range 23-70 years). In 21 cases injury occurred following open cholecystectomy whereas 11 patients had undergone laparoscopic cholecystectomy. Acute cholecystitis was the indication in 10 patients and symptomatic cholelithiasis with chronic cholecystitis in 22 patients. There were 4 patients in group I. Group II

and III comprised 8 and 20 patients respectively. The distribution of patients in accordance with Strasberg classification is shown in Table 1. In 28, Group II and III patients 19 patients presented with external biliary fistula, 5 had abdominal pain as presenting symptom whereas 4 patients presented with septicemia. Jaundice along with other presenting symptoms was present in 3 patients (Table 2).

Group I

In this group there were 4 patients in whom injury was detected intraoperatively. 3 were in our own units whereas for 1 patient we were called as rescue team in a city hospital. In 3 patients injury happened during laparoscopic cholecystectomy. Open cholecystectomy patient was 70 years old diabetic individual with ischaemic heart disease. He sustained injury to 3mm sized bile duct from segment VI while separating gall bladder from the liver. In view of small size of duct immediate suture ligation was done. He had uneventful outcome. Of the other 3 patients 2 patients had type D injury. One of the patients with type D injury was a case of double gall bladder. He sustained injury to lateral part of common hepatic duct in an attempt to dissect intrahepatic 2nd gall bladder adherent to common hepatic duct. Immediate conversion to laparotomy and direct suture repair of the duct was done. However in the postoperative period he continued to have persistent bile leak in the drain. ERC and stent placement resulted in resolution of bile leak. 2nd case of type D injury sustained injury during laparoscopic cholecystectomy for acute cholecystitis. Immediate conversion to laparotomy and suture repair of the injury was done. He had uneventful postoperative outcome. In the third case we were called as rescue team when operating surgeon detected complete transection of CBD during laparoscopic cholecystectomy for acute cholecystitis. On table cholangiography revealed type E1 injury. Roux-en-Y hepaticojejunostomy was done. In the postoperative period she had continuous bile leakage from the drain for 2 weeks. On follow up she developed biliary stricture 6 months postoperatively. Redo hepaticojejunostomy was done at 9 months. Rest of the patients had uneventful outcome on follow up.

Group II

In this group there were 8 patients presented within 2 weeks of cholecystectomy. One patient who underwent open cholecystectomy was referred to us on postoperative day 7 with features of peritonitis and shock. USG showed diffuse collection of fluid. She was taken up for immediate laparotomy. Preoperative findings revealed gross peritoneal contamination. Blood clots in sub hepatic space. Evacuation of blood clots revealed active bleeding from a vessel in hepatic hilum Hemostasis, thorough peritoneal lavage and adequate drainage of sub hepatic space was done. In the postoperative period she had biliary fistula along with deep wound dehiscence. She

died on postoperative day 14 because of multi-organ failure and sepsis.

Second patient had long standing history of gall bladder stone. Ultrasound showed contracted gall bladder with solitary 22mm calculus. During laparoscopy gall bladder was not visualised because of extensive sub hepatic adhesions. Laparotomy subtotal cholecystectomy was done. On post-operative day 3 she developed features of peritonitis with bilious leak in drain.

Ultrasound showed diffuse fluid collection. Immediate re-exploration revealed type D injury. She was managed

with repair and T tube placement. Five patients (4 laparoscopic cholecystectomy, 1 open cholecystectomy) presented with external biliary fistula. MRCP showed normal biliary tract anatomy in 3 patients. They were managed successfully with conservative management. Two patients who had cystic duct leak on MRC were managed by ERC and biliary stent.

A 24 year old female presented with external biliary fistula after open cholecystectomy. MRC showed Type E2 common bile duct injury (Fig1). She was managed conservatively for 6 weeks and later on underwent successful hepaticojejunostomy.

Table 1: Patient distribution as per strasberg classification.

Strasberg classification		Categories				
Types		LC	OC	I	II	III
A	Cystic duct leak or leak from duct in liver bed	2			2	
B	Occlusion of RHD	1	1			2
C	Transection of RHD		2	1		1
D	Lateral injury to major hepatic duct	3	1	2	1	1
E1	Transection 2 cm below hilar confluence	1	7		2	6
E2	Transection within 2cm hilar confluence	2	3	1		4
E3	Transection just below confluence	1	2			3
E4	Separation of R and L duct					
E5	Stricture involving common and R hepatic duct		1			1
Unclassified		2	3		4	1
Total		12	20	4	9	19

Table 2: Clinical presentation.

Clinical presentation	II (n = 9)	III (n = 19)
External biliary fistula	7	12
Abdominal pain	0	5
Jaundice	0	1
Septicaemia	2	1

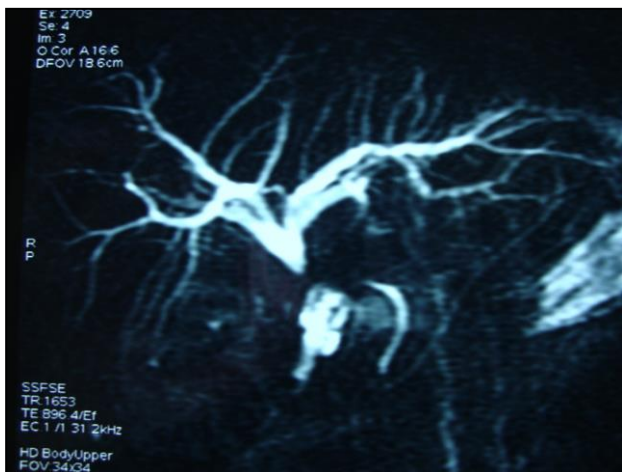

Figure 1: Type E2 biliary stricture.

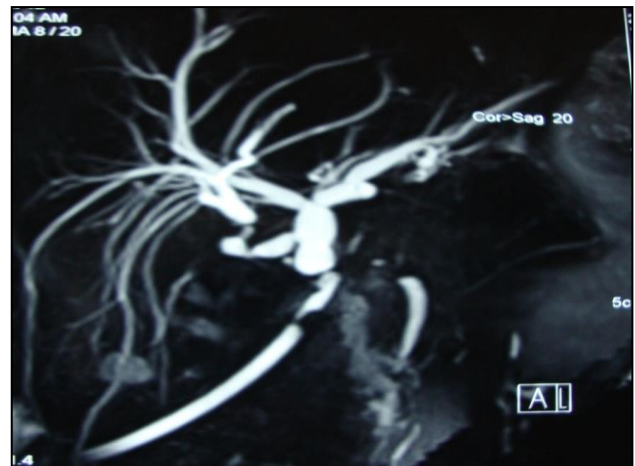


Figure 2: Type E5 biliary stricture.

Group III

In this group there were 20 patients. 12 patient's external biliary fistula, 4 patients had associated cholangitis, 3 patients presented with sepsis, jaundice, 5 patients presented with abdominal pain. Roux-en-Y hepaticojejunostomy was done in 11 patients after mean interval of 7.09 weeks. Postoperatively one patient had

low output biliary leak from the drain which resolved by day 6.

Two other patients had minor wound infection. Rest of the patients had uneventful outcome. One patient had type E 5 biliary stricture (Figure 2). Separate anastomosis of the right sectoral duct was done on same Roux loop. Conservative management was done in 4 patients. All these 4 patients presented with external biliary fistula after laparoscopic cholecystectomy.

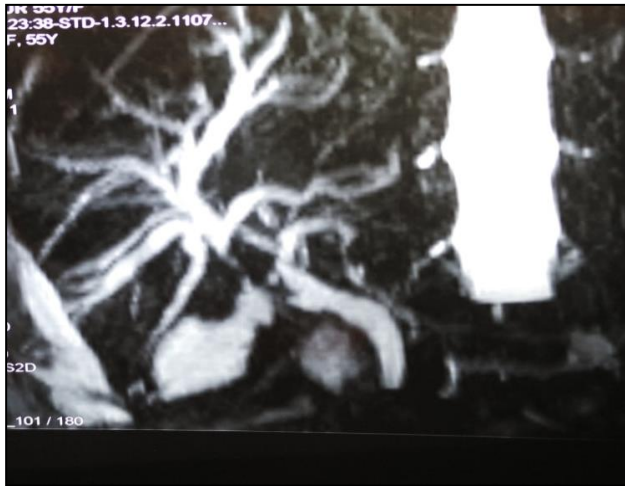

Figure 3: Right hepatic duct injury.

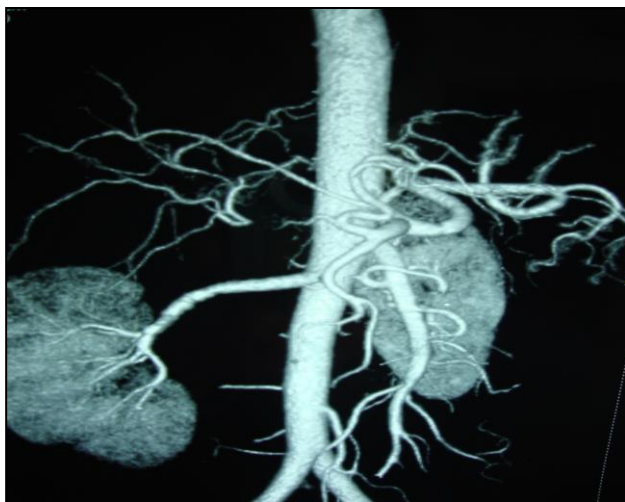

Figure 4: CT angiogram of right hepatic artery injury.

MRC revealed normal cholangiogram. These patients were managed successfully with conservative management. Percutaneous drainage of hepatic abscess was done in one patient. This patient developed external biliary fistula after the resolution of abscess and succumbed to sepsis, multi-organ failure after 1 month. One patient who had history of cholecystectomy 2 years back presented with abdominal pain evaluation with ultrasound revealed dilated CBD up to midpoint. Her liver function tests were normal except for the raised

alkaline phosphatase. ERC revealed tight mid CBD stricture, dilatation and stenting was done. Isolated right hepatic duct injury was identified in 3 patients. One patient after open cholecystectomy presented with external biliary fistula. MRC showed complete transection of right hepatic duct (Figure 3). This patient was initially managed conservatively. Her fistula subsided gradually. She was advised surgery but refused by patient. Second patient was 78 year old female. She presented with abdominal pain. Ultrasound scan and CECT scan of the abdomen showed gastrointestinal stromal tumor stomach with atrophic right posterior sector of the liver. She had history of open cholecystectomy many years back. In view of her age and associated comorbidities only tumor excision was done. Third patient presented with abdominal pain USG showed dilated posterior sector ducts. MRCP showed dilated posterior sector ducts with abrupt cut off. Roux-en-Y hepaticojejunostomy was done.

Regular follow up every 6 months was done in all the patients. Mean follow up period was 24.5 months (1-60 months). In summary of the 14 patients requiring hepaticojejunostomy 1 required revision surgery (poor outcome), rest of the 13 patients had excellent outcome.

DISCUSSION

Cholecystectomy (open or laparoscopic) is one of the commonest surgeries performed worldwide. Iatrogenic bile duct injury during cholecystectomy is a dreaded complication. Though the incidence of bile duct injury is more in laparoscopic cholecystectomy in comparison to open cholecystectomy, in our study open cholecystectomy was the primary surgery in majority 21 patients in comparison to 11 in laparoscopic cholecystectomy. This reflects that open cholecystectomy is still being performed in large number of peripheral hospitals. Our results are consistent with other studies done in various centers of India.⁵⁻⁷ Mean age of our patients was 47.6 years with male female ratio of 8:24. There are various conditions associated with increased risk of bile duct injuries such as acute cholecystitis, acute pancreatitis, cholangitis, scarring of Calot's triangle, intraoperative bleeding and anatomical variations.^{8,9} Lack of surgical skills, improper clip placement and excessive use of diathermy are other associated factors.¹⁰ In our series there was acute inflammation in 10 cases, bile duct anomaly in 2 cases, no known cause in 20 cases.

Majority of bile duct injuries are not recognized during cholecystectomy. Patients sustaining injury during cholecystectomy usually present in the early postoperative period. Usual clinical features are abdominal pain, distension, bile leak in drain, fever and features of septicaemia. In present study immediate recognition was done in 4 patients whereas other 28 patients presented at variable time, 9 patients within 2 weeks and 19 after 2 weeks of cholecystectomy. External biliary fistula was present in 19 patients, abdominal pain

in 5 patients and septicaemia as presenting clinical feature was there in 4 patients. Some studies have stressed upon prompt aggressive investigation in case of unexpected abdominal pain, fever and distension after cholecystectomy.¹¹⁻¹³ Maderiafis et al has shown abdominal pain secondary to biliary peritonitis as the main presenting feature.¹⁴ However in present study abdominal pain was present in only 5 patients. The reason for this is that in our case majority of patients has been referred from other hospitals after 2 weeks of cholecystectomy with external biliary fistula as the main presenting feature.

Management of type A injuries is done by ERC (endoscopic retrograde cholangiography) sphincterotomy and biliary stenting. Two patients in our series had type A injury. Both were successfully managed with endoscopic biliary stenting.

Traditionally type E injuries are managed by initial control of sepsis, making controlled external biliary fistula, improvement of nutrition and finally biliodigestive anastomoses after interval of 6 weeks to several months.⁶ Early repair is usually associated with high failure rates.^{15,16} Two of our patient in group II and 14 in Group III were managed with delayed repair. Hepaticojejunostomy was done in 11 patients with the mean interval of 7.09 weeks. The waiting period allowed ischemia of the cut end to stabilize, inflammation to subside plus the biliary radical dilatation help for optimal hepaticojejunostomy. Early repair was done in only one patient. This patient presented with jaundice, anaemia on postoperative day 16 of open cholecystectomy. CT angiography revealed injury to right hepatic artery (Figure 4). MRCP showed type E2 biliary injury. This patient had no external biliary fistula. Communication with operating surgeon suggested ligation of common bile duct in continuity. Since the patient had no features of sepsis. She was taken up for Roux-en-Y hepaticojejunostomy after correction of haemoglobin with multiple blood transfusions. There are studies which highlighted the role of early repair in select group of patients.^{17,18}

There were 4 type D injuries. 2 recognized intraoperatively were immediately dealt by on table repair. Other 2 one each in group I and group II were successfully managed with ERC and biliary stenting.

Though there were 2 cases of vascular injury in our series. No specific attempt was made by us for excluding vascular injury. Associated vascular injuries has adverse consequences in the repair of bile duct as highlighted by many studies.¹⁹⁻²¹ However in concordance with other authors⁶ we believe that wide anastomose constructed over well vascularized left duct obviates the need of any vascular repair.

Bile duct injury with septicaemia is potentially fatal. Two of our patients with septicaemia expired. Mortality rate

6.25% (2/32). In a study by Raute et al of the 16% observed mortality rate 7% was related to surgery and 9% unrelated to surgery.²² Helmy et al and Buanes et al reported 8.7% mortality rate as a result of postoperative complication.^{23,24}

Mean follow up for our patient was 24.5 months (1-60 months). All the patients who underwent hepaticojejunostomy except one patient had excellent result as per triad of criteria used. This patient sustained type E1 injury while undergoing laparoscopic cholecystectomy at another hospital. Immediate on table Roux-en-Y hepaticojejunostomy was done. She had persistent bile leak for 20 days postoperatively. On follow up at 6 months she developed jaundice accompanied by abdominal pain. MRC revealed anastomotic stricture. She required revision hepaticojejunostomy. Our results are consistent with the reported result in literature.^{25,26}

Limitation of the study is relatively small number of cases and retrospective nature. The good results of bile duct repair in the present study can be attributed to appropriate timing, strict adherence to principals of hepaticojejunostomy and tertiary care management.

Funding: No funding sources

Conflict of interest: None declared

Ethical approval: Not required

REFERENCES

1. Sicklick JK, Camp MS, Lillemore KD, Melton GB, Yeo CJ, Campbell KA et al. Surgical management of bile duct injuries sustained during laparoscopic cholecystectomy. *Ann Surg.* 2005;241:786-95.
2. Bergmann JJGHM, Brink GR, Rauws EAJ, Dewit L, Obertop H, Huibregtse K, et al. Treatment of bile duct lesions after laparoscopic cholecystectomy. *Gut.* 1996;38:141-7.
3. Slater K, Strong RW, Wall DR, Lynch SV. Iatrogenic bile duct injury: the scourge of laparoscopic cholecystectomy. *ANJ Surg.* 2002;72:83-8.
4. Lau WE, Lai ECH, Lau SHW. Management of bile duct injury after laparoscopic cholecystectomy: a review. *ANJ Surg.* 2010;80:75-81.
5. Chaudhary NA, Dar FA, Naikoo ZA, Wani NA, Parray FQ, Wani KA. Iatrogenic bile duct injuries in Kashmir valley. *Indian J Surg.* 2010;72:298-304.
6. Ibrarullah MD, Sankar S, Sreenivasan K, Gavini SRK. Management of bile duct injuries at various stages of presentation: experience from a tertiary care centre. *Indian J Surg.* 2015;77:92-8.
7. Pottakkat B, Vijayahari R, Prakash A, Singh RK, Behari A, Kumar A, Kapoor VK, Saxena R. Incidence, pattern and management of bile duct injuries during cholecystectomy: experience from a single centre. *Dig Surg.* 2010;27:275-9.

8. Schmidt SC, Langrehr JM, Hintze RE, Neuhaus P. Long term results and risk factors influencing outcome of major bile duct injuries following cholecystectomy. *Br J Surg*. 2005;92:76-82.
9. Soderlund C, Frozanpur F, Linder S. Bile duct injuries at laparoscopic cholecystectomy: a single institution prospective study acute cholecystitis indicates an increased risk. *World J Surg*. 2005;29:987-93.
10. Groonroos JM, Hamalainen MT, Karvonen J, Gullichsen R, Laine S. Is male gender a risk factor for bile duct injury during laparoscopic cholecystectomy. *Langenbecks Arch Surg*. 2003;388:261-4.
11. Davids PH, Tanka AK, Rauws EAJ, Vangullik TM, VanLeuween DJ, Dewit LT et al. Benign biliary stricture surgery or endoscopy. *Ann Surg*. 1993;217:237-43.
12. Trerotola SA, Savadar SH, Lund Vanbrux AC, Sostre S, Lillemoe KD et al. Biliary tract complications following laparoscopic cholecystectomy, imaging and intervention. *Radiology*. 1992;184:195-200.
13. Davidoff PM, Pappas TN, Murray EA, Hilleren DJ, Johnson RD, Baker ME. Mechanism of major biliary injury during laparoscopic cholecystectomy. *Ann Surg*. 1992;215:196-202.
14. Madraefis JR, Podson SF. Corrective treatment and anatomic consideration for laparoscopic cholecystectomy injuries. *J Am Coll Surg*. 1994;179:321-5.
15. Schol FP, Go PM, Gouma DJ. Outcome of 49 repairs of bile duct stricture after laparoscopic cholecystectomy. *World J Surg*. 1995;19:168-72.
16. Gouma DJ. Referral pattern and timing of repair are risk factors for complication after reconstructive surgery for bile duct injury. *Ann Surg*. 2007;265:763-70.
17. Mercado MA. Early versus late repair of bile duct injuries. *Surg Endosc*. 2007;20:1644-7.
18. Thomson BMJ, Parks RW, Madhvan KK, Wigmore SJ, Garden OJ. Early specialist repair of biliary injury. *Br J Surg*. 2006;93:216-20.
19. Schmidt SC, Settmacher U, Langrehr JM, Neuhaus P. Management and outcome of patients with combined bile duct and hepatic arterial injuries after laparoscopic cholecystectomy. *Surgery*. 2004;135:613-8.
20. Gupta N, Soloman H, Fairchild R, Kaminski DL. Management and outcome of patient with combined bile duct and hepatic arterial injuries. *Arch Surg*. 1998;133:176-81.
21. Koffron A, Ferrario M, Parsons W, Namseck A, Saker M, Abecassis M. Failed primary management of iatrogenic biliary injury: incidence and significance of concomitant hepatic arterial disruption. *Surgery*. 2001;130:722-31.
22. Raute M, Podlech P, Jaschke W, Mangegold BC, Trede M, Chir B et al. Management of bile duct injuries and strictures following cholecystectomy. *World J Surg*. 1993;17:553-62.
23. Helmy A, Gad H, Hammad E, Marawad I, El T, Waked I et al. Iatrogenic biliary injuries: patterns and surgical management. *Dig Surg*. 1997;14:534-9.
24. Buaenes T, Waage A, Majaland O, Solheim K. Bile leak after cholecystectomy significance and treatment. *Int Surg*. 1996;81:276-9.
25. Henry AP, Kauffman NL, Coleman J, White RI, Cameron JL. Benign postoperative biliary strictures. Operate or dilate. *Ann Surg*. 1989;210:417-25.
Stewart L, Way LW. Bile duct injury during laparoscopic cholecystectomy. Factors that influence the results of treatment. *Arch Surg*. 1995;120:1123-9.

Cite this article as: Sharma M, Singh R, Singh NR. Management of iatrogenic bile duct injury in cholecystectomy: a single centre experience. *Int Surg J* 2016;3:29-34.