

Case Report

Laparoscopic management of renal and hepatic hydatidosis in a child: a case report and review of literature

Rajashekhar T. Patil^{1*}, Sandesh V. Parelkar², Beejal Sanghvi²

¹Department of Surgery, SN Medical College, Bagalkot, Karnataka, India

²Department of Pediatric surgery, Seth GS Medical College, and KEM Hospital Mumbai, Maharashtra, India

Received: 07 March 2017

Accepted: 01 April 2017

*Correspondence:

Dr. Rajashekhar T. Patil,

E-mail: rtpatil79@gmail.com

Copyright: © the author(s), publisher and licensee Medip Academy. This is an open-access article distributed under the terms of the Creative Commons Attribution Non-Commercial License, which permits unrestricted non-commercial use, distribution, and reproduction in any medium, provided the original work is properly cited.

ABSTRACT

Hydatidosis is an endemic disease caused by *Echinococcus granulosus*. Humans are accidental intermediate hosts. In children, it affects the lung in 64% of cases and the liver in 28%. Renal involvement is uncommon (2-4%). We operated 7 years old girl with renal and hepatic hydatidosis laparoscopically. Hydatid cyst should be kept as one of differential diagnosis while managing cystic disease of any organ in the body. To the best of our knowledge this is the first case of renal hydatidosis with hepatic hydatidosis that has been managed laparoscopically. Laparoscopic surgery is safe and efficacious in managing multiorgan hydatid disease in children.

Keywords: Children, Laparoscopy, Renal and hepatic hydatidosis

INTRODUCTION

Hydatidosis is an endemic disease caused by *Echinococcus granulosus*. Humans are accidental intermediate hosts. In adults, it affects the liver in 55-70% of cases and the lung in 18-35% and in children, it affects the lung in 64% of cases and the liver in 28%.¹ Renal involvement is uncommon (2-4%).^{2,3} Another organ involvement with renal hydatidosis is reported 44% of these cases. We operated 7-year-old girl with renal and hepatic hydatidosis laparoscopically. To the best of our knowledge this is the first case of renal hydatidosis with hepatic hydatidosis that has been managed laparoscopically.

CASE REPORT

A 7-year-old girl presented with history of right side vague upper abdominal pain and mass per abdomen since 2 months. She did not have bowel or bladder complaints. There was no history of jaundice. Girl was from a village

where sheep rearing was the main occupation. On examination, there was a large cystic swelling present in right hypochondriac region extending to right lumbar region, which was nontender and bimanually palpable. Abdominal ultrasonography was suggestive of unilocular renal cyst, measuring 10 X 9 X 9 cms, arising from lower pole of right kidney and another small cyst involving right lobe of liver. MRI abdomen also revealed similar findings (Figure 1).

With clinical diagnosis of simple cyst of right kidney, she was taken for laparoscopic deroofing of the cyst. The patient was placed in supine position with right side elevated. Two 5 mm trocars were used. Primary camera port was put at subumbilical region, 30° telescope was used. On laparoscopy, a large cystic swelling arising from lower pole of right kidney was found which was displacing large and small intestine medially and there was no obvious cystic lesion over liver surface. 5 mm trocar placed in right hypochondriac region over cyst site. Suction needle was put to aspirate the cyst. (Figure 2)

After aspirating the fluid cyst was decompressed and we could see hydatid membrane like structure at cyst wall opening. Then cyst wall was held with grasper forceps and delivered out through right hypochondriac port site taking utmost care to prevent spillage into peritoneal cavity. Partial cystectomy and removal of germinating membrane of hydatid cyst was done. (Figure 3) Cyst cavity irrigated with betadine as scolicedal agent. Cyst wall closed over the tube drain and replaced back into the abdominal cavity. Drain removed on postoperative day 2. Postoperative course was uneventful. Patient was discharged on albendazole.

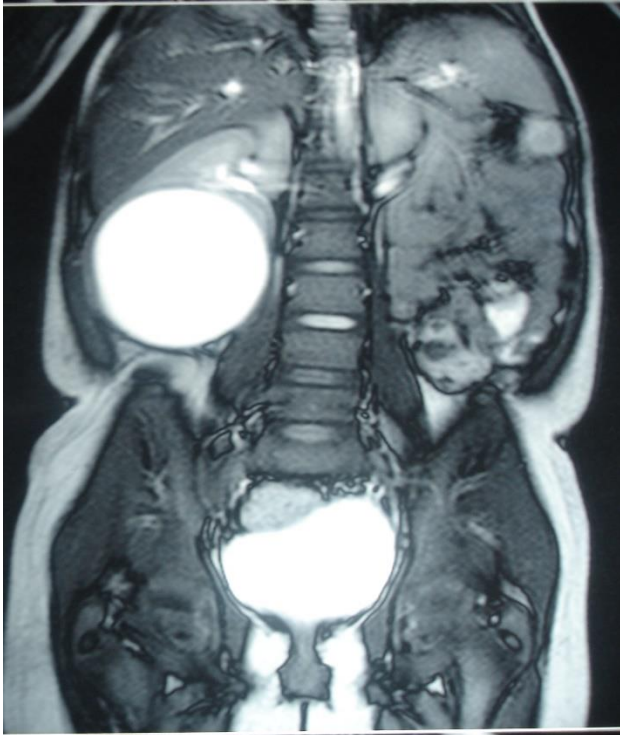


Figure 1: MRI showing unilocular right renal cyst.

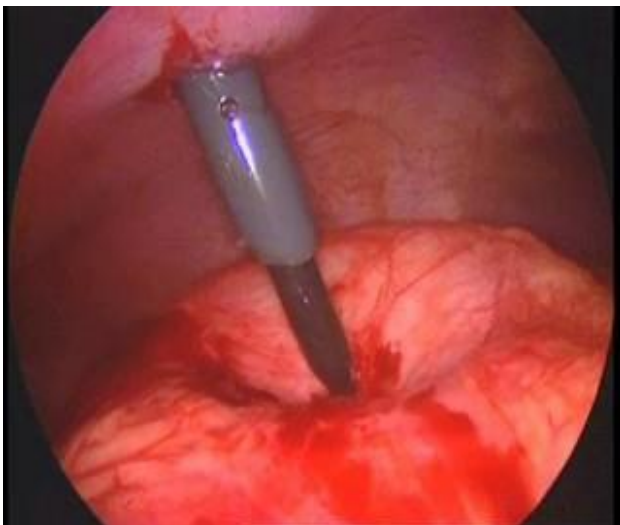


Figure 2: Laparoscopic aspiration of renal hydatid cyst.

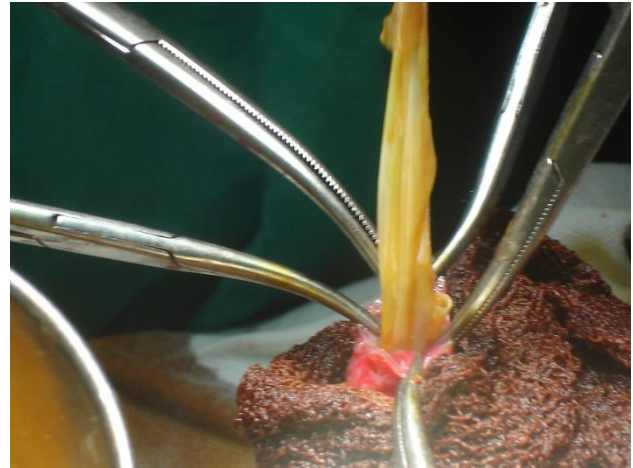


Figure 3: Renal hydatid cyst delivered out through port site.

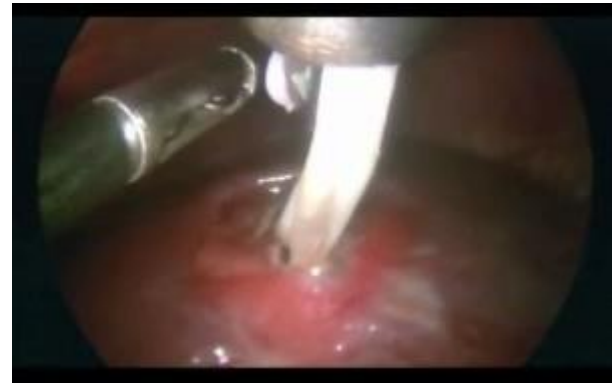

Figure 4: Laparoscopic removal of germinating membrane from liver hydatid cyst.

On follow up at 3 months patient complained of vague right upper quadrant abdominal pain. On examination, abdomen was nontender without any palpable lump. Abdominal ultrasonography revealed no recurrence of renal hydatid, but there was increase in size of liver hydatid cyst. CT scan confirmed the findings. Patient was posted for laparoscopic hepatic hydatid cyst unroofing. Three 5mm trocars were used. Primary camera port placed in sub-umbilical region by open Hassan's technique. Pneumoperitoneum created at 8-10 mmHg pressure and under vision one working port put at right hypochondrium at previous operative scar and other at epigastric region. There was cystic swelling over surface of right lobe of liver with adhered omentum. Using harmonic scalpel omentum was released from liver surface and cyst wall cauterized and aspirated using suction canula. After decompressing the cyst, cavity was irrigated with betadine. Cyst wall was opened and germinating membrane removed taking care not spill into abdominal cavity. (Figure 4) Partial cystectomy and omentoplasty was done. Postoperative course was uneventful. She was discharged on Albendazole for 3 months. On follow up at 6 months, patient is

asymptomatic and ultrasound abdomen showed no recurrence of hydatid cyst of kidney and liver.

DISCUSSION

Hydatidosis caused by *Echinococcus granulosus* is an endemic parasitic disease in Mediterranean countries, North Africa, Spain, Greece, Turkey, Portugal, Middle East, Australia, New Zealand, South America, Baltic areas, Philippines, Northern China and the Indian sub-continent. In India, hydatid disease is common in most of the states (Predominantly in Andhra Pradesh and Tamil Nadu states).⁴ It was described by Hippocrates as a “liver full of water” in 400 BC. *Echinococcus granulosus* has dog as the definitive host and sheep as the intermediate host. Humans are accidental intermediate hosts. Hydatid cyst involves the liver in 55% to 70% of cases and the lung in 18% to 35% in adults. In children, it affects the lung in 64% of cases and the liver in 28%. Renal involvement is uncommon (2-4%). In renal hydatidosis other organ involvement is 44%. Renal hydatid cyst patients usually present with mass per abdomen, pain abdomen or sometimes with hydaturia. Our patient presented with pain and cystic mass per abdomen. Even with most sophisticated investigations hydatid cyst diagnosis was missed. In this case unilocular renal hydatid cyst was mimicking simple renal cyst. Hydatid cyst diagnosis was made intraoperatively. Casoni's skin test and complement fixation test are no longer performed because of the high percentage of false-positive results.⁵ Hydatid disease should be kept as differential diagnosis in children presenting with cystic swelling in kidney and liver especially when the patients belong to endemic region. Mebendazole and albendazole are in use as chemotherapy for hydatid disease. The drug kills the parasite by limiting its glucose uptake through the disruption of the microtubules in the germinal membrane cells.⁶ PAIR (percutaneous aspiration, injection of scolicidal agent, and respiration) under radiological guidance has been described as an alternative to surgical intervention. It has advantages like relatively short hospital stay, cosmetically better, and possibility of performing the procedure under local anesthesia.⁷ It may also be indicated in the case of deep-seated cysts.

However, it is not without drawbacks. Cyst puncture carries the risk of spillage in superficially located cysts, as procedure is not under control, thus leading to dissemination of the disease or anaphylactic shock.⁸ Other drawback are cysts in proximity to major blood vessels, difficulty in eradicating complicated cysts (Gharbi types III and IV) and lack of accessibility to extrahepatic cysts.⁹⁻¹¹ Hydatid cysts can be managed either by open surgery or by minimal invasive surgery. There are case reports of children with renal hydatid cyst being managed by retroperitoneoscopic technique. All the principles of open surgery should be followed during laparoscopic surgery like utmost care to prevent spillage into peritoneal cavity, sterilization of the cyst with scolicidal agents (Betadine solution), and complete

removal of the endocyst. Exclusion criteria are cysts with biliary communication, deeply located cysts and disseminated liver hydatidosis. The number, size and location of the cysts are not the contraindications for surgery.¹² In fact, this technique is safe in exploring the dome and cysts located posteriorly with a 30° telescope. Complex cysts were not found to be a contraindication to this operation. The laparoscopic approach can be advantageous because the endoscope can be introduced into the cyst cavity for inspection and to make sure that no daughter cysts or laminated membranes were overlooked and also helps to detect small bile opening. A major disadvantage of laparoscopy is the lack of precautionary measures concerning spillage, especially under high abdominal pressures induced by pneumoperitoneum.¹³ However, Bicket et al. demonstrated that the increase in intracystic pressure was no greater than the increase in intra-abdominal pressure and that pneumoperitoneum was protective against spillage.¹⁴ Laparoscopic surgery is safe and efficacious in managing multiorgan hydatid disease in children.¹⁵ It offers the advantages of less pain, rapid recovery, less short-term and long-term morbidity, and good cosmesis.

Funding: No funding sources

Conflict of interest: None declared

Ethical approval: Not required

REFERENCES

1. Tsakayiannis E, Pappis C, Moussatos G. Late results of the conservative surgical procedures in hydatid disease of the lung in children. *Surg.* 1970;68:379-82
2. Kirkland K. Urological aspects of hydatid disease. *Br J Urol.* 1996;38:241-54.
3. Angulo JC, Sanchez-Chapado M, Diego A, Escribano J, Tamayo JC, Martin L. Renal echinococcosis: clinical study of 34 cases. *J Urol.* 1997;157:787-94.
4. Jahed AK, Fardin R, Farzad A, Bakshadeh K. Clinical echinococcosis. *Ann Surg.* 1975;182:541-6.
5. Katz R, Murphy S, Kosloske A. Pulmonary echinococcosis: a pediatric disease of the southwestern United States. *Pediatr.* 1980;65:1003-6.
6. Kammener W, Judge D. Chemotherapy of hydatid disease (*Echinococcus granulosus*) in mice with mebendazole and bithionol. *Am J Trop Med Hyg.* 1976;25:714-7.
7. Bret PM, Fond A, Bretagnolle M, Valette PJ, Thiesse P, Lambert R, et al. Percutaneous aspiration and drainage of hydatid cysts in the liver. *Radiol.* 1988;168:617-8.
8. Derveniz C, Delis S, Avgerinos C, Madariaga J, Milicevic M. Changing concepts in the management of the liver hydatid disease. *J Gastrointest Surg.* 2005;9:869-77.
9. Ustunsoz B, Akhan O, Kamiloglu MA, Somuncu I, Ugurel MS, Cetiner S. Percutaneous treatment of

- hydatid cysts of the liver: long-term results. *AJR Am J Roentgenol.* 1999;172:91-6.
10. Men S, Hekimoglu B, Yucesoy C, Arda IS, Baran I. Percutaneous treatment of hepatic cysts: an alternative to surgery. *AJR Am J Roentgenol.* 1999;172:83-9.
 11. Kabaalioglu A, Ceken K, Alimoglu E, Apaydin A. Percutaneous imaging guided treatment of hydatid liver cysts: do long-term results make in a first choice? *Eur J Radiol.* 2006;59:65-73.
 12. Maazoun K, Mekki M, Chioukh FZ, Sahnoun L, Ksia A, Jouini R, et al. Laparoscopic treatment of hydatid cyst of the liver in children. A report on 34 cases. *J Pediatr Surg.* 2007;42:1683-6.
 13. Ertem M, Karahasanoglu T, Yavuz N, Erguney S. Laparoscopically treated liver hydatid cysts. *Arch Surg.* 2002;137:1170-3.
 14. Bickel A, Daud G, Urbach D, Lefler E, Barasch EF, Eitan A. Laparoscopic approach to hydatid liver cysts. *Surg Endosc.* 1998;12:1073-7.
 15. Parelkar SV, Gupta RK, Shah H, Sanghvi B, Gupta A, Jadhav V, et al. Experience with video-assisted thoracoscopic removal of pulmonary hydatid cysts in children. *J Pediatr Surg.* 2009;44:836-41.

Cite this article as: Patil RT, Parelkar SV, Sanghvi B. Laparoscopic management of renal and hepatic hydatidosis in a child: a case report and review of literature. *Int Surg J* 2017;4:1793-6.